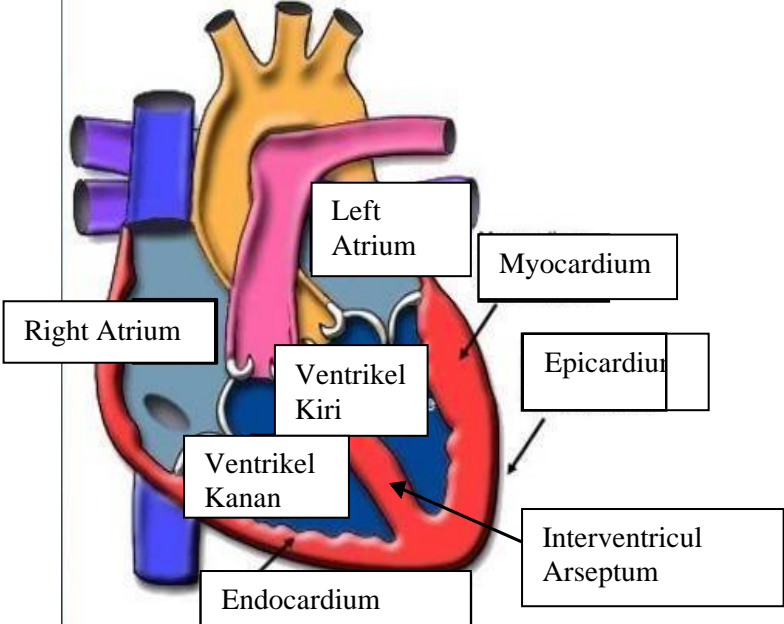
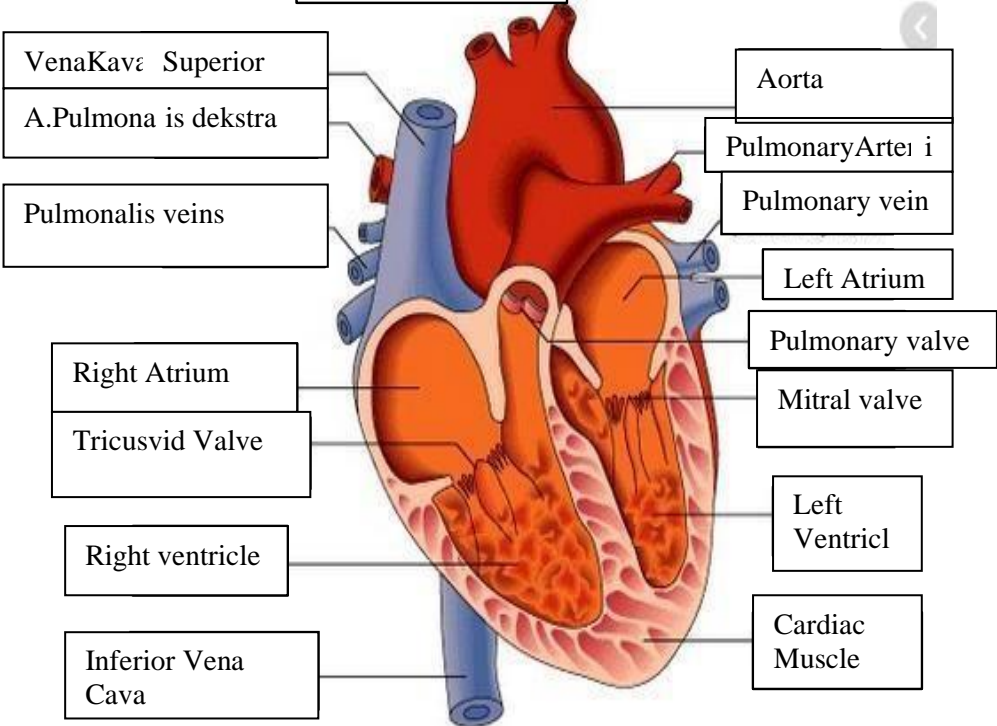
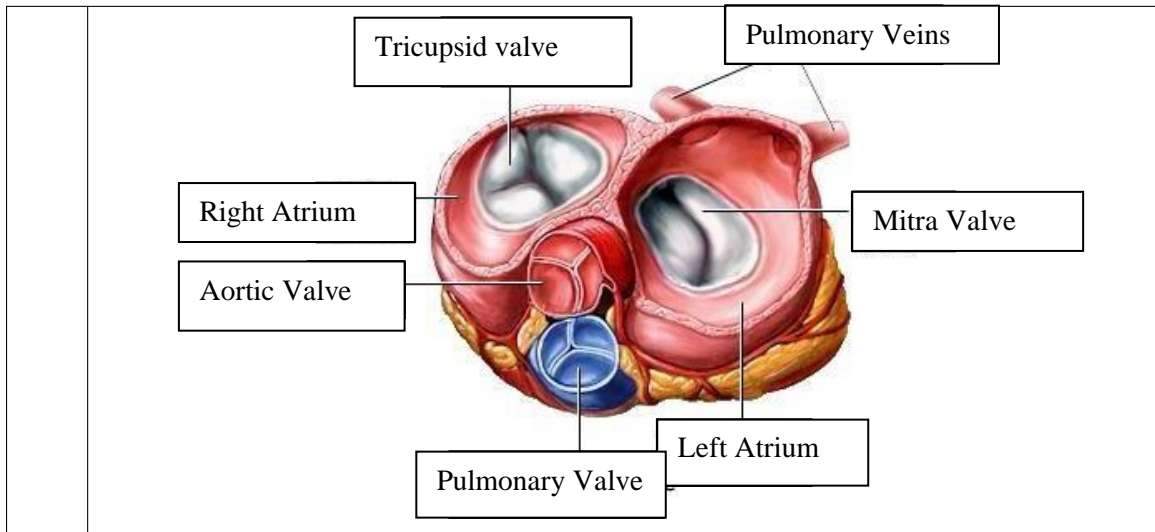


WORKSHEETS (LEMBAR KERJA)

Mata Kuliah	: Anatomi
Materi	: Anatomi Cardiovaskuler
NIM/Nama Mahasiswa	: 2110101055/ Niken Desri Fauzana

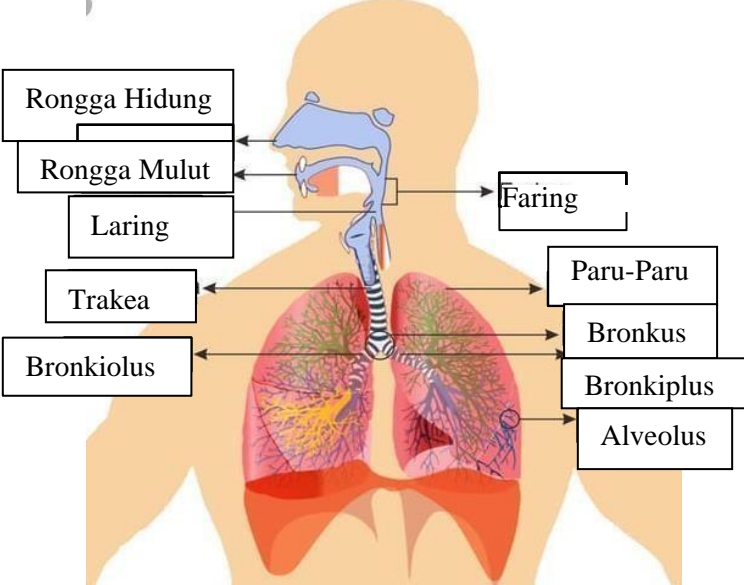
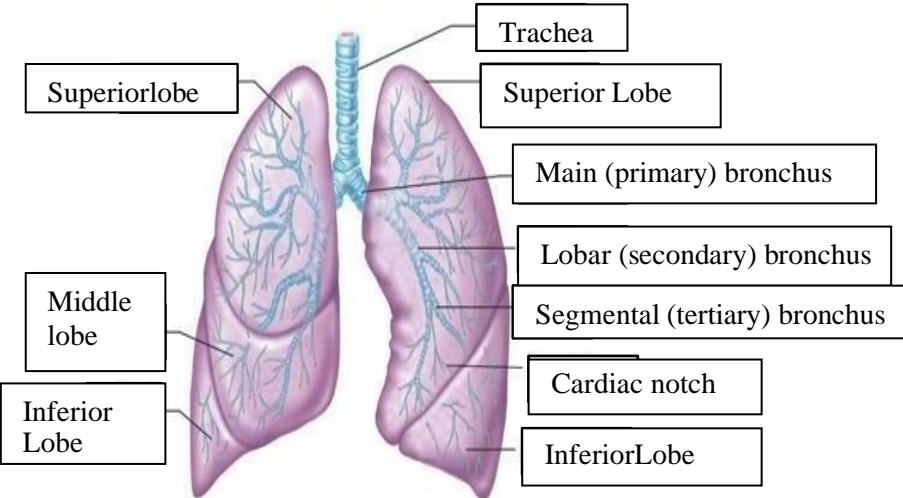
No	Keterangan	Pembahasan
1		 <p>This diagram shows a cross-section of the heart wall and its internal chambers. Labels include: Right Atrium, Left Atrium, Ventrikel Kiri (Left Ventricle), and Ventrikel Kanan (Right Ventricle). The wall layers are labeled as Endocardium (innermost), Myocardium (middle), and Epicardium (outermost). The Interventricular Arseptum (Septum) is also shown separating the ventricles.</p>
	<p>VenaKava Superior</p> <p>A.Pulmona is dekstra</p> <p>Pulmonalis veins</p> <p>Right Atrium</p> <p>Tricusvid Valve</p> <p>Right ventricle</p> <p>Inferior Vena Cava</p>	 <p>This diagram shows the heart with its major blood vessels and valves. Labels include: VenaKava Superior, A.Pulmona is dekstra, Pulmonalis veins, Right Atrium, Tricusvid Valve, Right ventricle, Inferior Vena Cava, Aorta, PulmonaryArteri i, Pulmonary vein, Left Atrium, Pulmonary valve, Mitral valve, Left Ventricl, and Cardiac Muscle.</p>



WORKSHEETS (LEMBAR KERJA)

Mata Kuliah	: Anatomi
Materi	: Anatomi Respirasi
NIM>Nama Mahasiswa	: 2110101073/ Anjeli Sauri

No	Keterangan	Pembahasan
1	<p>An anatomical diagram of the human respiratory system. It shows the nasal cavity, pharynx, trachea, bronchi, bronchioles, lungs (right and left), pleura, and diaphragm. Labels with leader lines point to the following structures:</p> <ul style="list-style-type: none"> Pharynx Nasal Cavity Esophagus Trachea Bronkus Bronkiolus ParuParu Kanan Bronkus Pleura Paru-Paru Kiri Diafragma 	

No	Keterangan	Pembahasan
		 <p>Diagram of the human respiratory system with labels:</p> <ul style="list-style-type: none"> Rongga Hidung Rongga Mulut Laring Trakea Bronkiolus Faring Paru-Paru Bronkus Bronkiplus Alveolus
		 <p>Detailed anatomical diagram of the lungs with labels:</p> <ul style="list-style-type: none"> Superiorlobe Middle lobe Inferior Lobe Trachea Superior Lobe Main (primary) bronchus Lobar (secondary) bronchus Segmental (tertiary) bronchus Cardiac notch InferiorLobe

