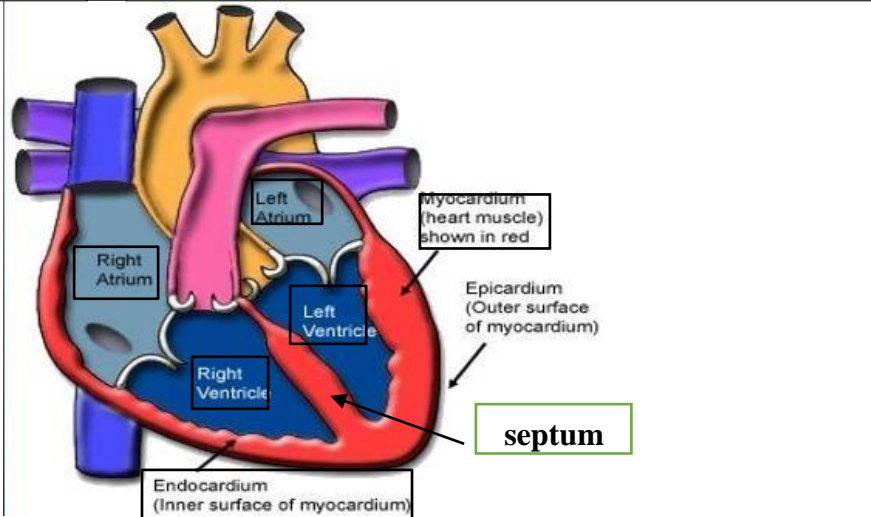
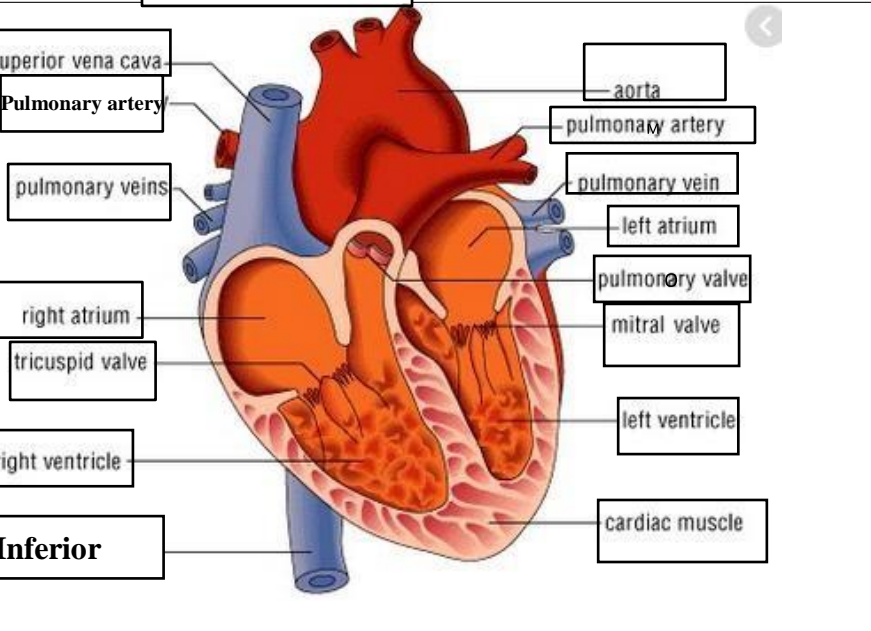
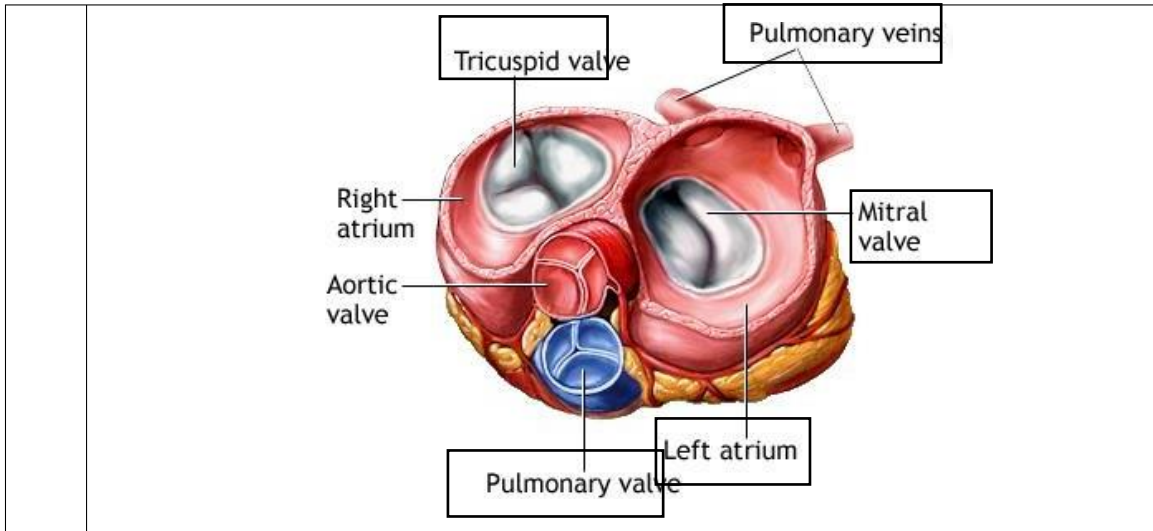


WORKSHEETS (LEMBAR KERJA)

Mata Kuliah	: Anatomi
Materi	: Anatomi Cardiovaskuler
NIM>Nama Mahasiswa	: 2110101040 / ANIDA PERMATA SARI

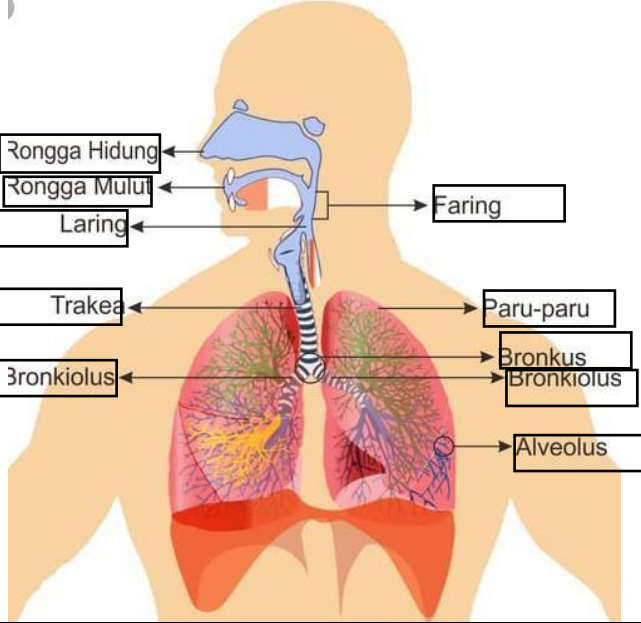
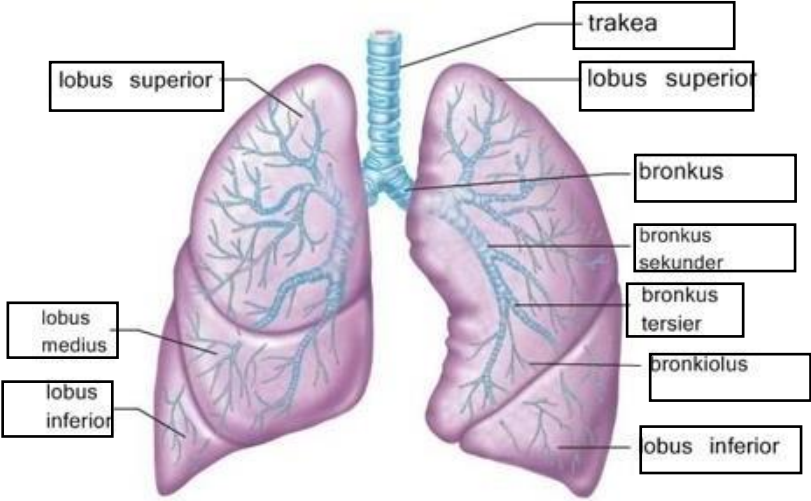
No	Keterangan	Pembahasan
1		
		



WORKSHEETS (LEMBAR KERJA)

Mata Kuliah	: Anatomi
Materi	: Anatomi Respirasi
NIM>Nama Mahasiswa	: 2110101040_ANIDA PERMATA SARI

No	Keterangan	Pembahasan
1	<p>An anatomical diagram of the human respiratory system. Labels include: Faring, Laring, Bronkus, Paru-paru kanan, Pleura, Diafragma, Rongga hidung, Trakea, Bronkiolus, Bronkus, and Paru-paru kiri. The diagram shows the airway from the nasal cavity down to the lungs, which are situated above the diaphragm.</p>	

No	Keterangan	Pembahasan
		 <p>Diagram of the human respiratory system with labels: Rongga Hidung, Rongga Mulut, Laring, Faring, Trakea, Paru-paru, Bronkus, Bronkiolus, and Alveolus.</p>
		 <p>Detailed diagram of the lungs with labels: trakea, lobus superior, lobus superior, bronkus, bronkus sekunder, bronkus tersier, pronkiolus, lobus inferior, lobus medius, and lobus inferior.</p>