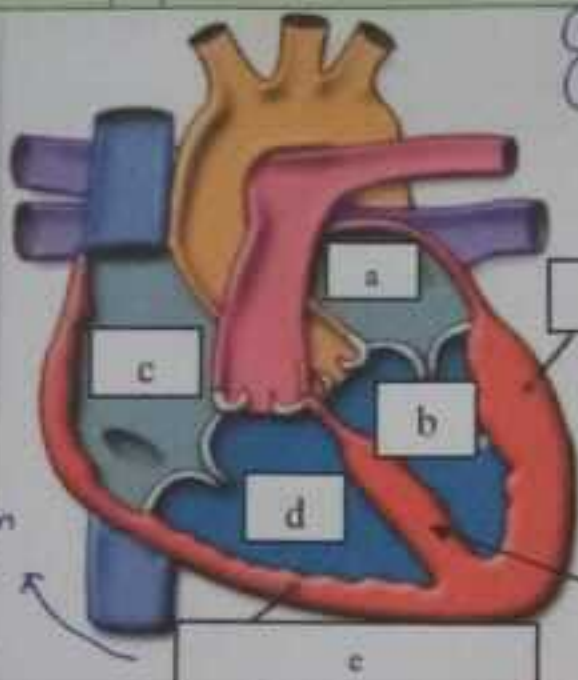
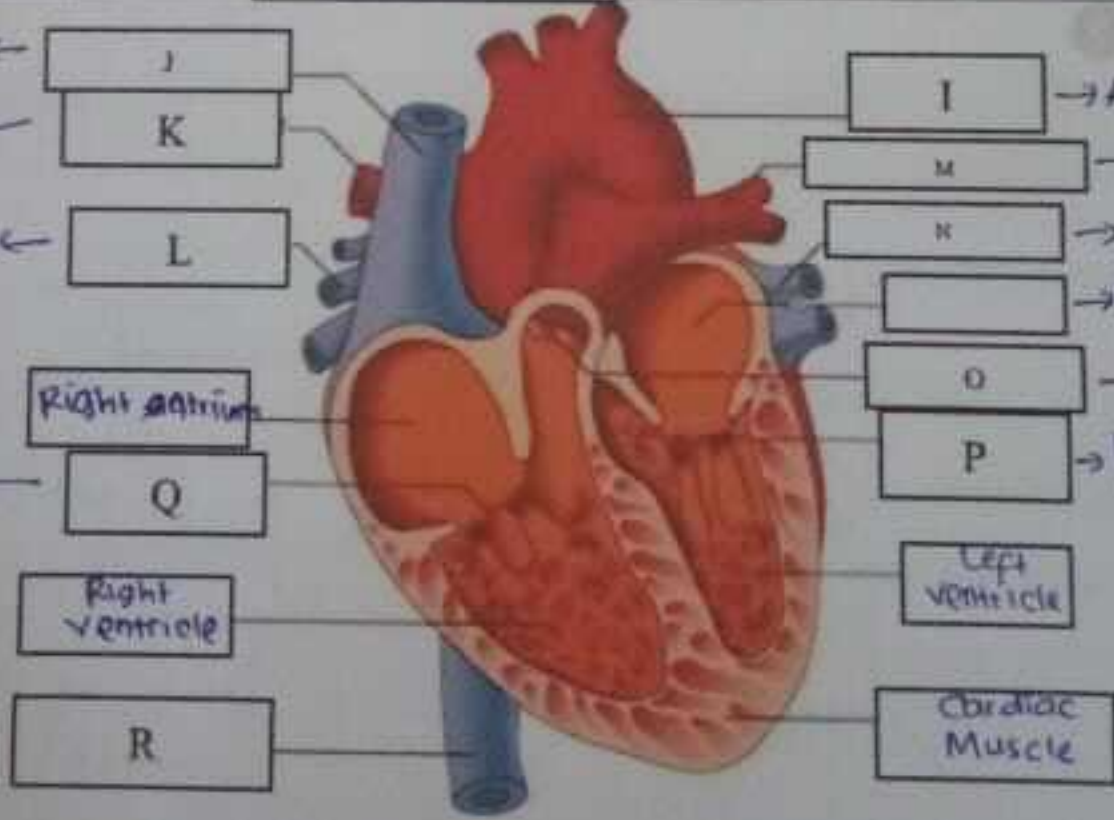
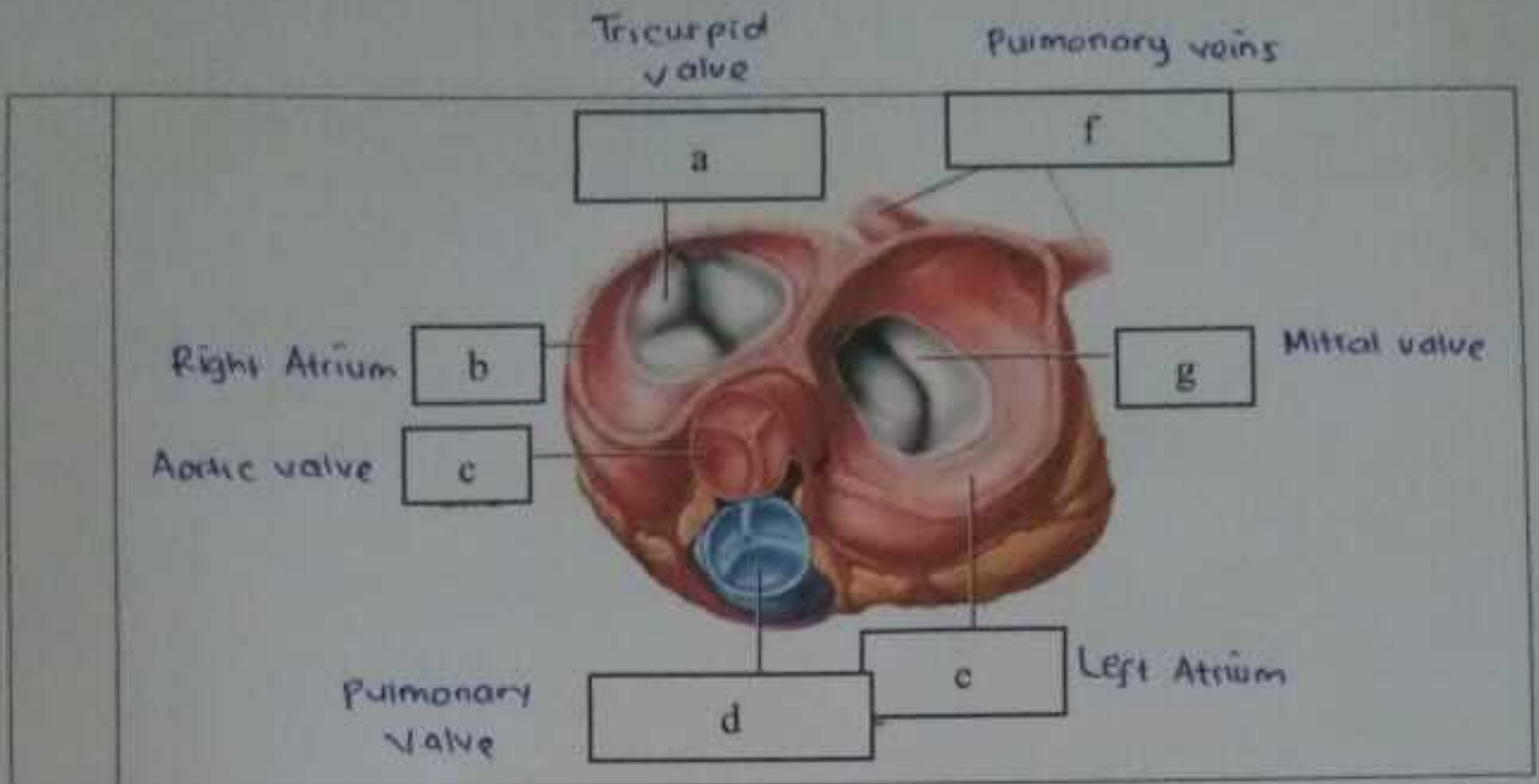


WORKSHEETS (LEMBAR KERJA)

Mata Kuliah	: Anatomi
Materi	: Anatomi Cardiovaskuler
NIM>Nama Mahasiswa	: 2110101059 / Salma Safira Damayanti

No	Keterangan	Pembahasan
1	<p>(c) Right atrium</p> <p>(d) Right ventricle</p> <p>(e) Endokardium</p>	 <p>(a) Left atrium</p> <p>(b) Left ventricle</p> <p>(c) Right atrium</p> <p>(d) Right ventricle</p> <p>(e) Endokardium</p> <p>(f) Epitardium</p> <p>(g) Myokardium</p> <p>(h) Perikardium</p>
	<p>vena cava superior ←</p> <p>Arteri pulmonari ←</p> <p>pulmonari veins ←</p> <p>tricuspid valve ←</p> <p>Vena cava inferior ←</p>	 <p>I → Aorta</p> <p>M → Arteri pulmonari</p> <p>N → Pulmonary vein</p> <p>O → Left atrium</p> <p>P → Pulmonary valve</p> <p>Mitral valve</p> <p>Left ventricle</p> <p>Cardiac Muscle</p> <p>Right atrium</p> <p>Right ventricle</p>



WORKSHEETS (LEMBAR KERJA)

Mata Kuliah	: Anatomi
Materi	: Anatomi Respirasi
NIM>Nama Mahasiswa	: 2110101057 / Salma Sapira Damayanti

No	Keterangan	Pembahasan
1	<p>Faring ← a</p> <p>Laring ← c</p> <p>Bronkus ← e</p> <p>Paru-paru kanan ← []</p> <p>pleura ← h</p>	<p>[] → Pongga hidung</p> <p>[] → Trakea</p> <p>[] → Bronkiolus</p> <p>[] → Bronkus</p> <p>[] paru kiri</p> <p>[]</p> <p>Diaphragma</p>

No	Keterangan	Pembahasan
----	------------	------------

- (A)
- (B)

Rongga hidung
Rongga mulut

