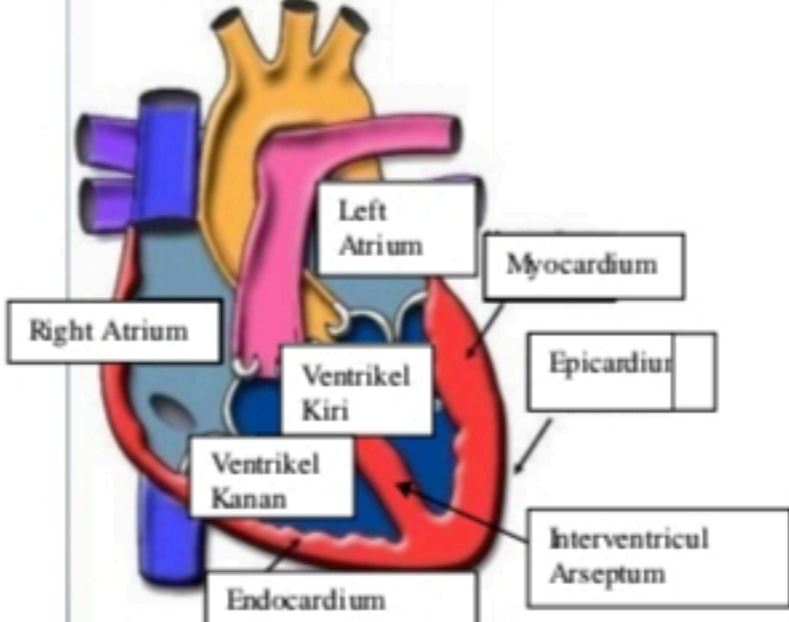
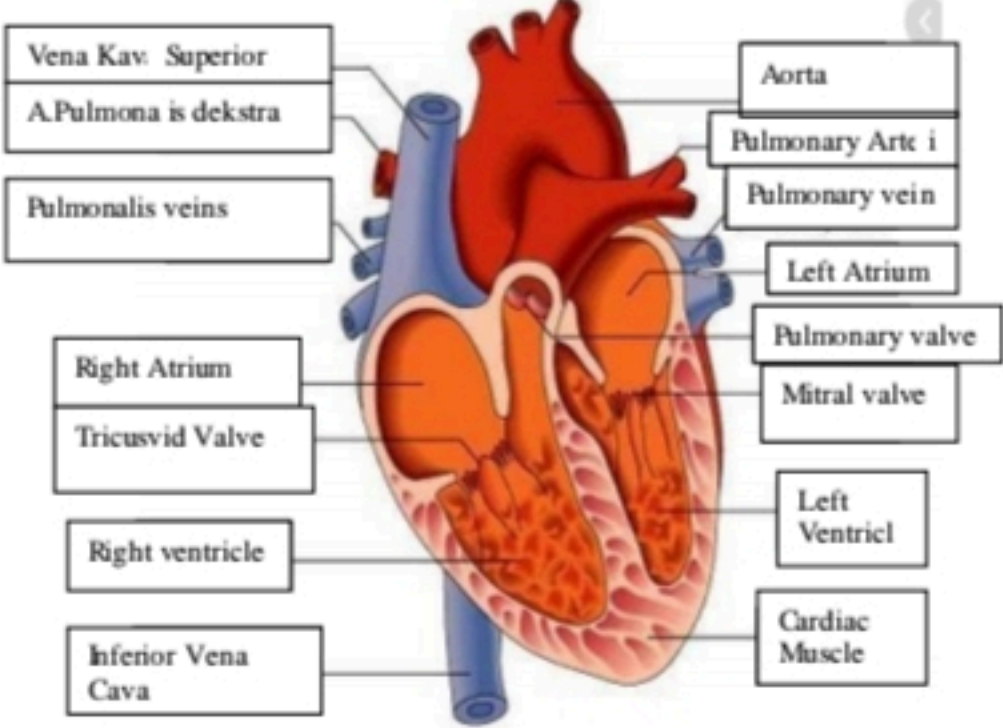
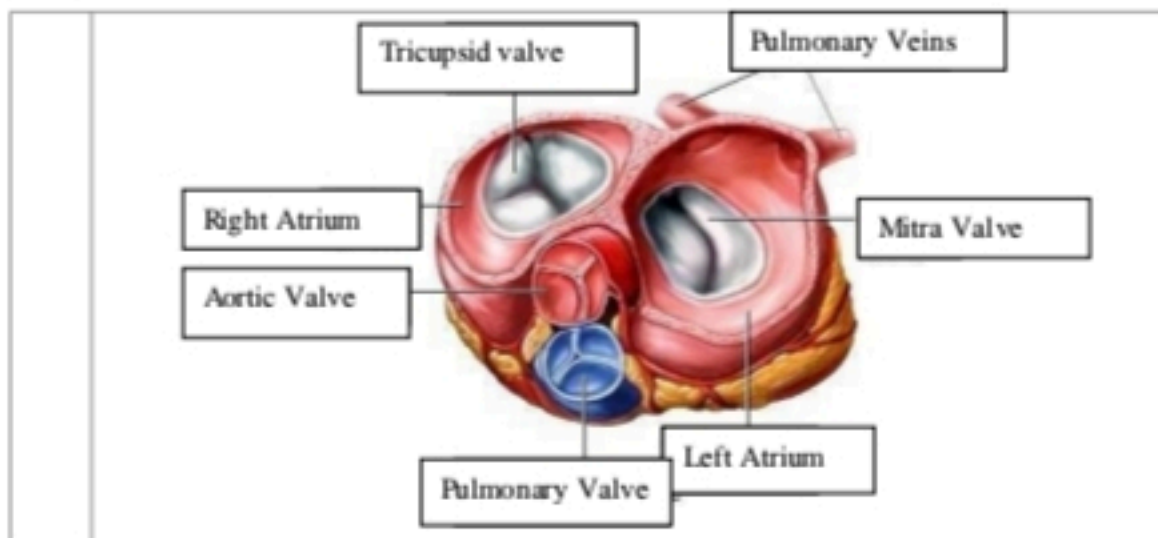


**WORKSHEETS (LEMBAR KERJA)**

<b>Mata Kuliah</b>	: Anatomi
<b>Materi</b>	: Anatomi Cardiovaskuler
<b>NIM/Nama Mahasiswa</b>	: 2110101050/Mila Novika Sari


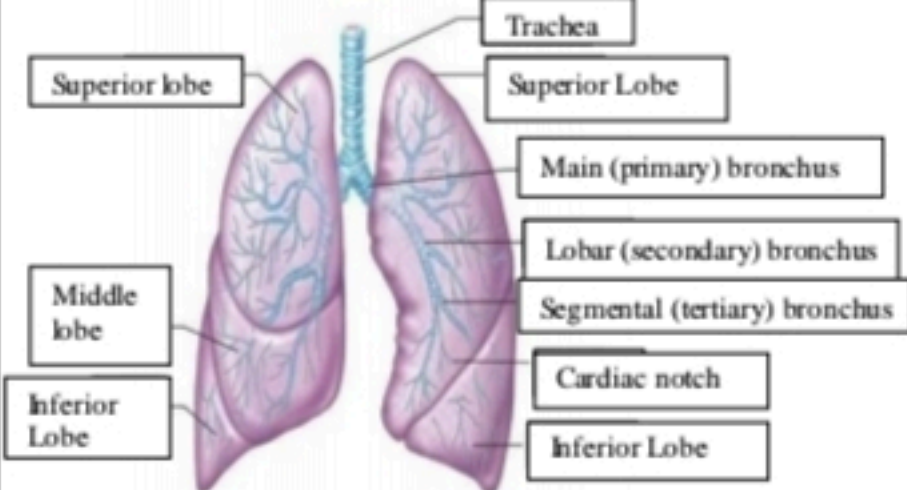
No	Keterangan	Pembahasan
1		 <p>This diagram shows a cross-section of the heart wall and its internal chambers. The layers of the heart wall are labeled as follows: Endocardium (innermost), Myocardium (middle), and Epicardium (outermost). The chambers shown are the Right Atrium, Left Atrium, Right Ventricle (Ventrikel Kanan), and Left Ventricle (Ventrikel Kiri). The Interventricular Arseptum is also indicated.</p>
	<p>Vena Kav. Superior</p> <p>A. Pulmonalis dekstra</p> <p>Pulmonalis veins</p> <p>Right Atrium</p> <p>Tricuspid Valve</p> <p>Right ventricle</p> <p>Inferior Vena Cava</p>	 <p>This diagram shows a more detailed view of the heart with its major vessels and valves. The vessels shown include the Vena Kav. Superior, A. Pulmonalis dekstra, Pulmonalis veins, and Inferior Vena Cava. The valves shown are the Tricuspid Valve, Pulmonary valve, and Mitral valve. The chambers shown are the Right Atrium, Left Atrium, and Left Ventricle. The Cardiac Muscle is also labeled.</p>



**WORKSHEETS (LEMBAR KERJA)**

Mata Kuliah	: Anatomi
Materi	: Anatomi Respirasi
NIM>Nama Mahasiswa	: 2110101066/Areta Maurindha Pratiwi

No	Keterangan	Pembahasan
1	<p>An anatomical diagram of the human respiratory system. Labels include: Pharynx, Esophagus, Bronkus, Paru Paru Kanan, Pleura, Nasal Cavity, Traches, Bronkiolus, Bronkus, Paru-Paru Kiri, and Diafragma.</p>	

No	Keterangan	Pembahasan
		 <p>Diagram of the human respiratory system with labels in Indonesian:</p> <ul style="list-style-type: none"> <li>Rongga Hidung</li> <li>Rongga Mulut</li> <li>Laring</li> <li>Trakea</li> <li>Bronkiolus</li> <li>Faring</li> <li>Paru-Paru</li> <li>Bronkus</li> <li>Bronkiplus</li> <li>Alveolus</li> </ul>
		 <p>Diagram of the lungs with labels in English:</p> <ul style="list-style-type: none"> <li>Trachea</li> <li>Superior Lobe</li> <li>Main (primary) bronchus</li> <li>Lobar (secondary) bronchus</li> <li>Segmental (tertiary) bronchus</li> <li>Cardiac notch</li> <li>Inferior Lobe</li> <li>Superior lobe</li> <li>Middle lobe</li> <li>Inferior Lobe</li> </ul>