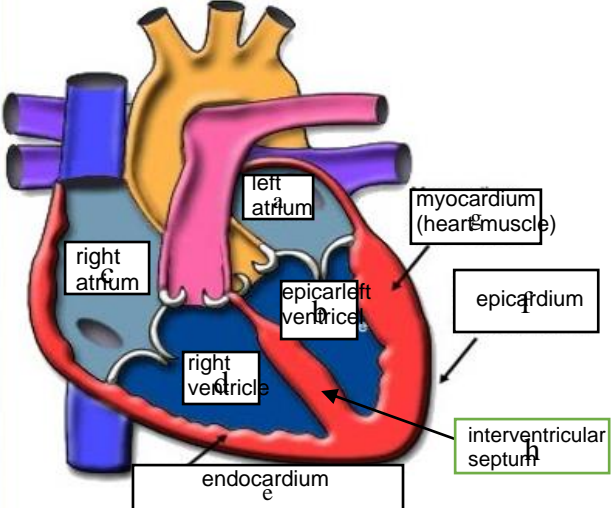
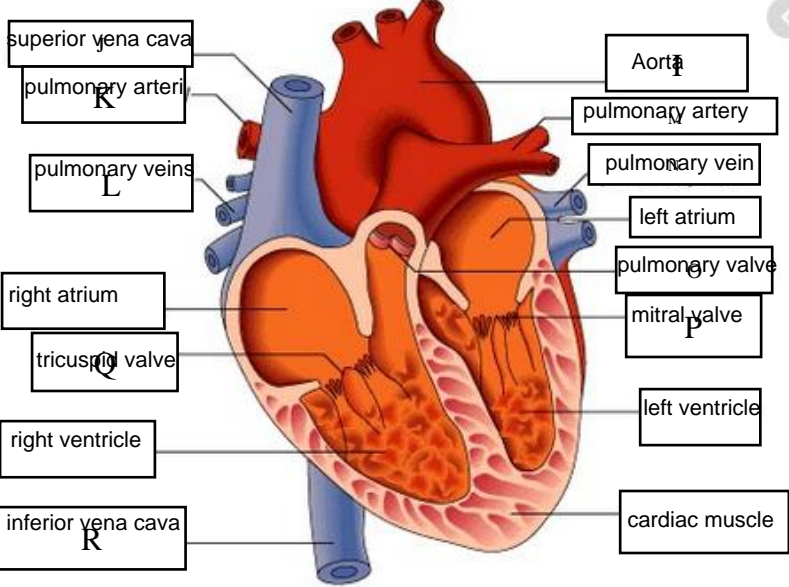
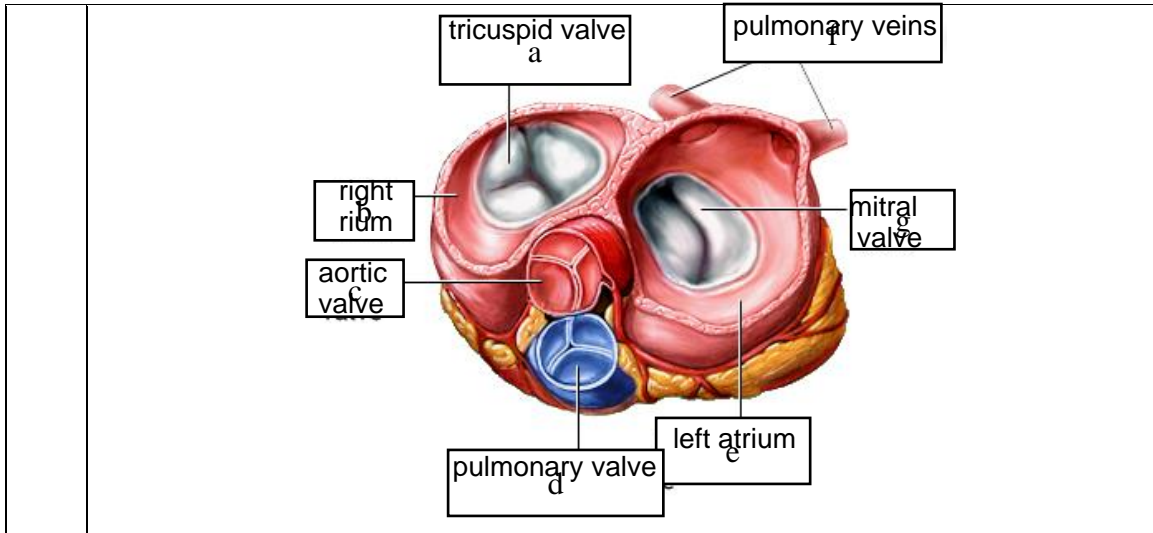


WORKSHEETS (LEMBAR KERJA)

Mata Kuliah	: Anatomi
Materi	: Anatomi Cardiovaskuler
NIM>Nama Mahasiswa	: 2110101032 / Izza syifa wahyu

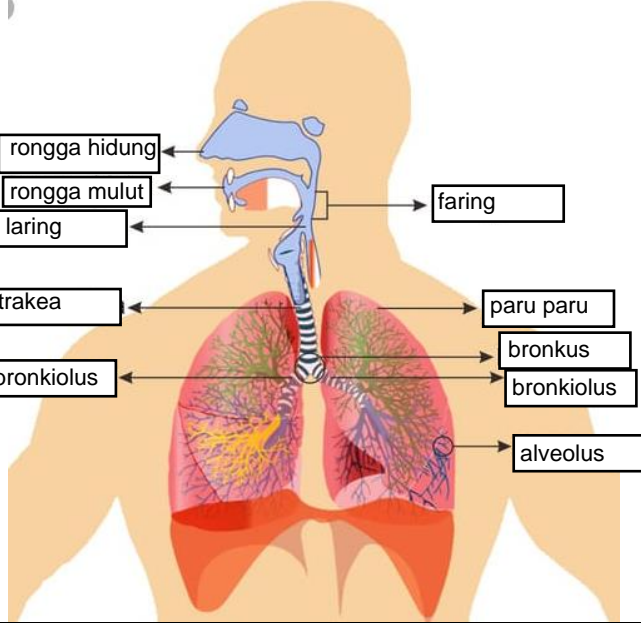
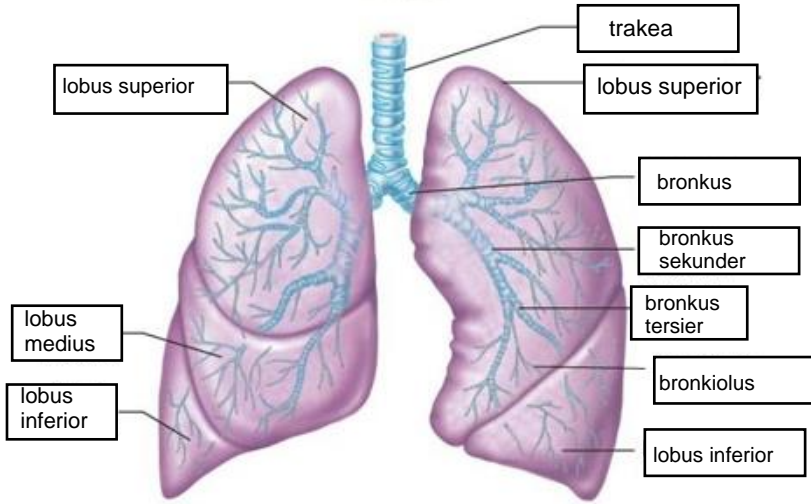
No	Keterangan	Pembahasan
1		
		



WORKSHEETS (LEMBAR KERJA)

Mata Kuliah	:	Anatomi
Materi	:	Anatomi Respirasi
NIM>Nama Mahasiswa	:	

No	Keterangan	Pembahasan
1	<p>Diagram of the human respiratory system with labels:</p> <ul style="list-style-type: none"> faring (a) laring (c) bronkus paru paru kanan pleura (h) paru paru kiri trakea (d) Bronkiolus Bronkus Diafragma 	

No	Keterangan	Pembahasan
		 <p>Diagram of the human respiratory system with labels: rongga hidung, rongga mulut, laring, trakea, bronkiolus, faring, paru paru, bronkus, bronkiolus, and alveolus.</p>
		 <p>Detailed diagram of the lungs with labels: lobus superior, lobus medius, lobus inferior, trakea, lobus superior, bronkus, bronkus sekunder, bronkus tersier, bronkiolus, and lobus inferior.</p>

