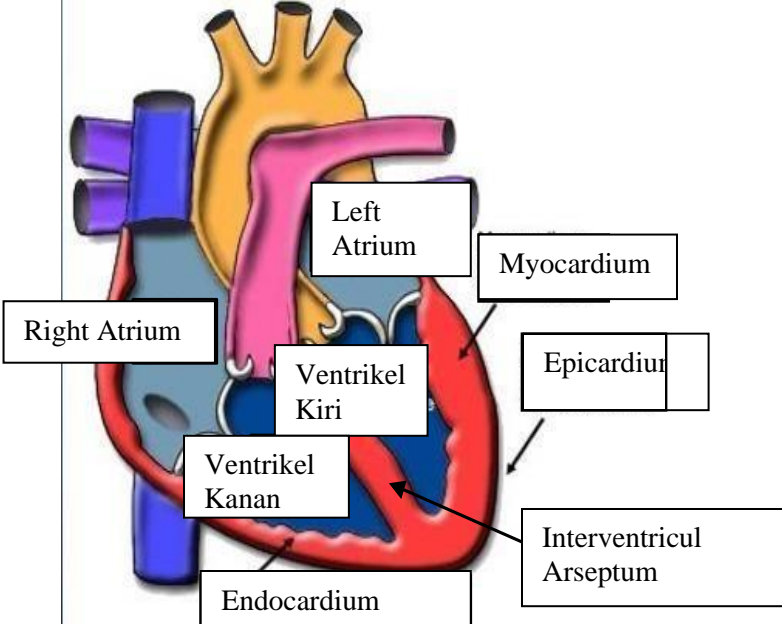
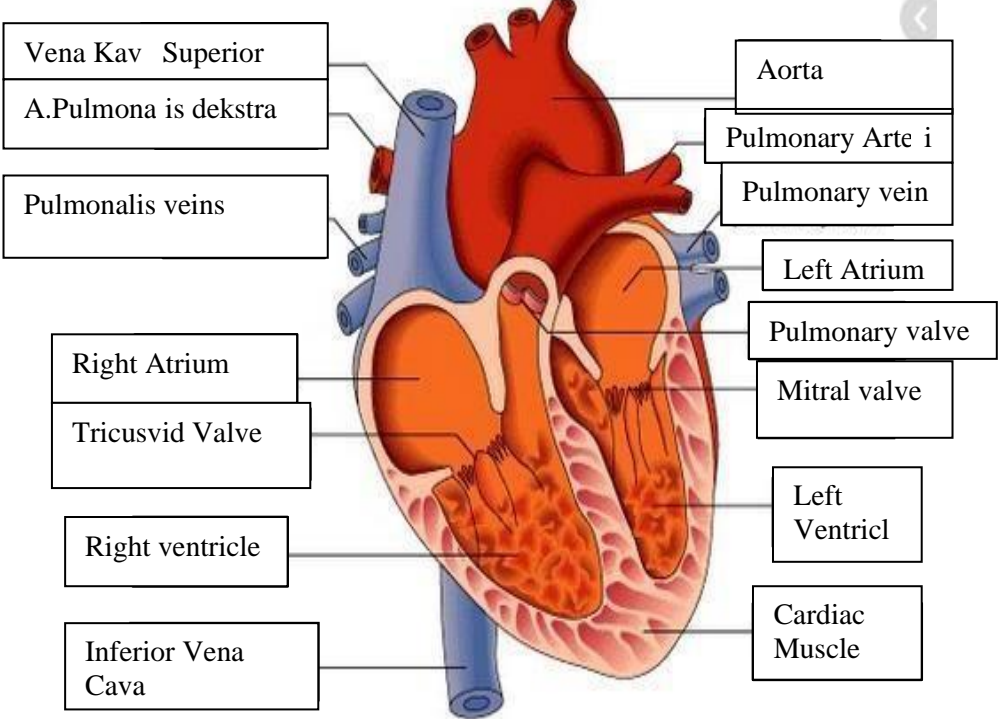
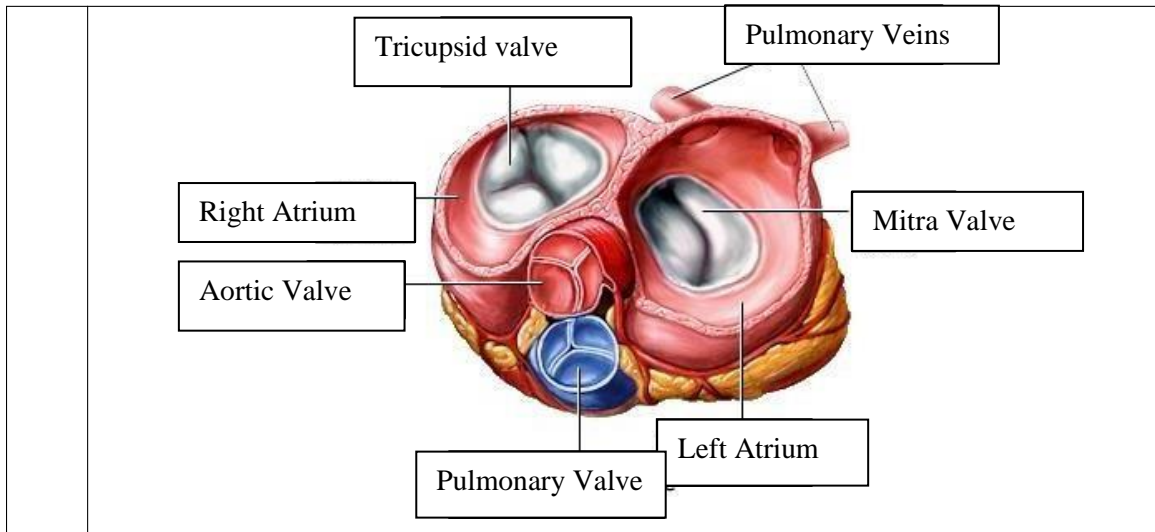


**WORKSHEETS (LEMBAR KERJA)**

|                           |                                      |
|---------------------------|--------------------------------------|
| <b>Mata Kuliah</b>        | : <b>Anatomi</b>                     |
| <b>Materi</b>             | : <b>Anatomi Cardiovaskuler</b>      |
| <b>NIM/Nama Mahasiswa</b> | : <b>2110101029/Monica dwi putri</b> |

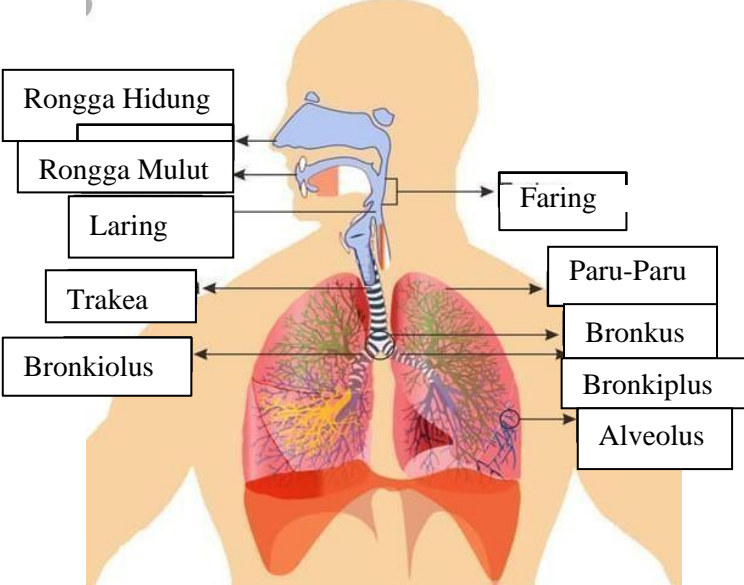
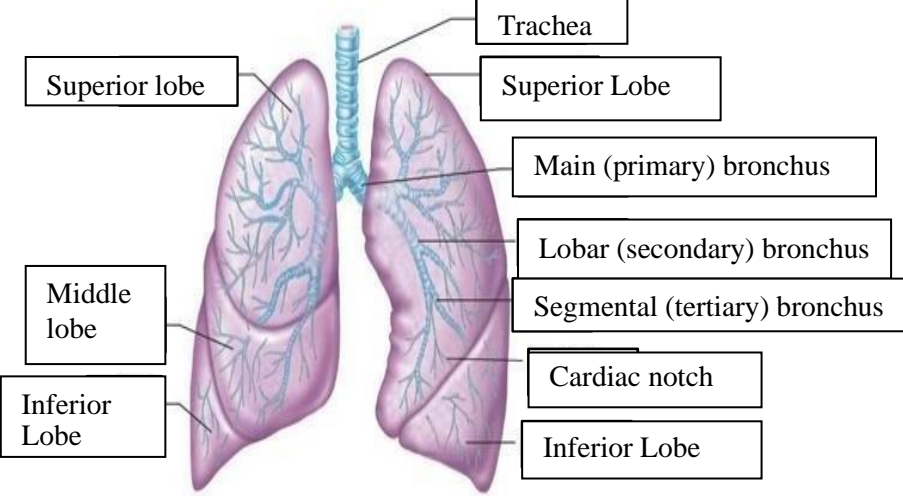
| No | Keterangan   | Pembahasan  |
|----|--|---|
| 1  |  |  <p>This diagram shows a cross-section of the heart wall. Labels include: Right Atrium, Left Atrium, Myocardium, Epicardium, Endocardium, Ventrikel Kiri (Left Ventricle), Ventrikel Kanan (Right Ventricle), and Interventricul Arseptum (Interventricular Septum).</p> |
|    |  <p>This diagram shows a detailed cross-section of the heart with various internal structures labeled. On the left side, labels include: Vena Kav Superior, A.Pulmonalis dekstra, Pulmonalis veins, Right Atrium, Tricuspid Valve, Right ventricle, and Inferior Vena Cava. On the right side, labels include: Aorta, Pulmonary Arteri, Pulmonary vein, Left Atrium, Pulmonary valve, Mitral valve, Left Ventricl, and Cardiac Muscle.</p> |   |



### WORKSHEETS (LEMBAR KERJA)

|                              |                       |
|------------------------------|-----------------------|
| <b>Mata Kuliah</b>           | : Anatomi             |
| <b>Materi</b>                | : Anatomi Respirasi   |
| <b>NIM&gt;Nama Mahasiswa</b> | : 2110101112/ Mufidah |

| No | Keterangan   | Pembahasan |
|----|--|------------|
| 1  | <p>An anatomical diagram of the human respiratory system, showing the nasal cavity, pharynx, trachea, bronchi, bronchioles, lungs, pleura, and diaphragm. The diagram is labeled with the following parts:</p> <ul style="list-style-type: none"> <li>Pharynx</li> <li>Nasal Cavity</li> <li>Esophagus</li> <li>Trachea</li> <li>Bronkus</li> <li>Bronkiolus</li> <li>Paru Paru Kanan</li> <li>Bronkus</li> <li>Pleura</li> <li>Paru-Paru Kiri</li> <li>Diafragma</li> </ul> |            |

| No | Keterangan | Pembahasan  |
|----|------------|---|
|    |            |  <p>Diagram of the human respiratory system with labels:</p> <ul style="list-style-type: none"> <li>Rongga Hidung</li> <li>Rongga Mulut</li> <li>Laring</li> <li>Trakea</li> <li>Bronkiolus</li> <li>Faring</li> <li>Paru-Paru</li> <li>Bronkus</li> <li>Bronkiplus</li> <li>Alveolus</li> </ul>  |
|    |            |  <p>Detailed diagram of the lungs with labels:</p> <ul style="list-style-type: none"> <li>Superior lobe</li> <li>Middle lobe</li> <li>Inferior Lobe</li> <li>Trachea</li> <li>Superior Lobe</li> <li>Main (primary) bronchus</li> <li>Lobar (secondary) bronchus</li> <li>Segmental (tertiary) bronchus</li> <li>Cardiac notch</li> <li>Inferior Lobe</li> </ul> |

