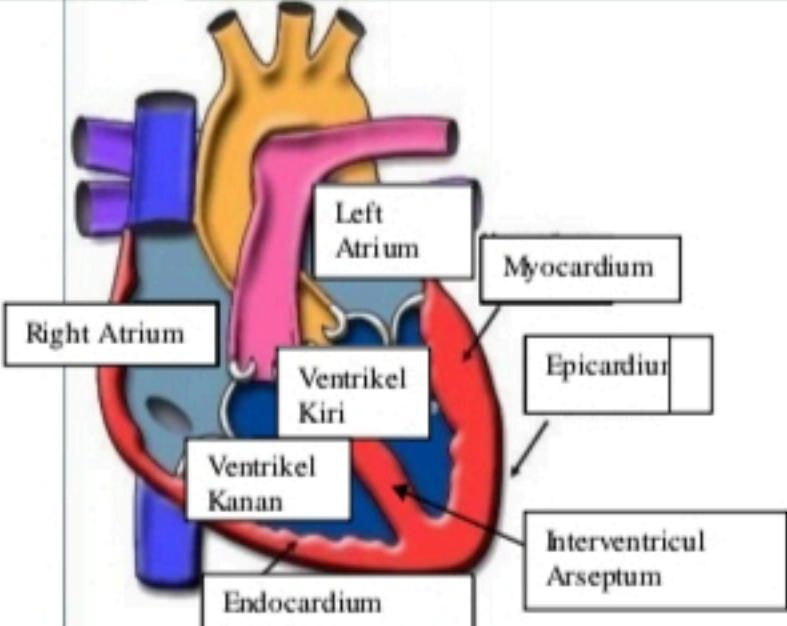
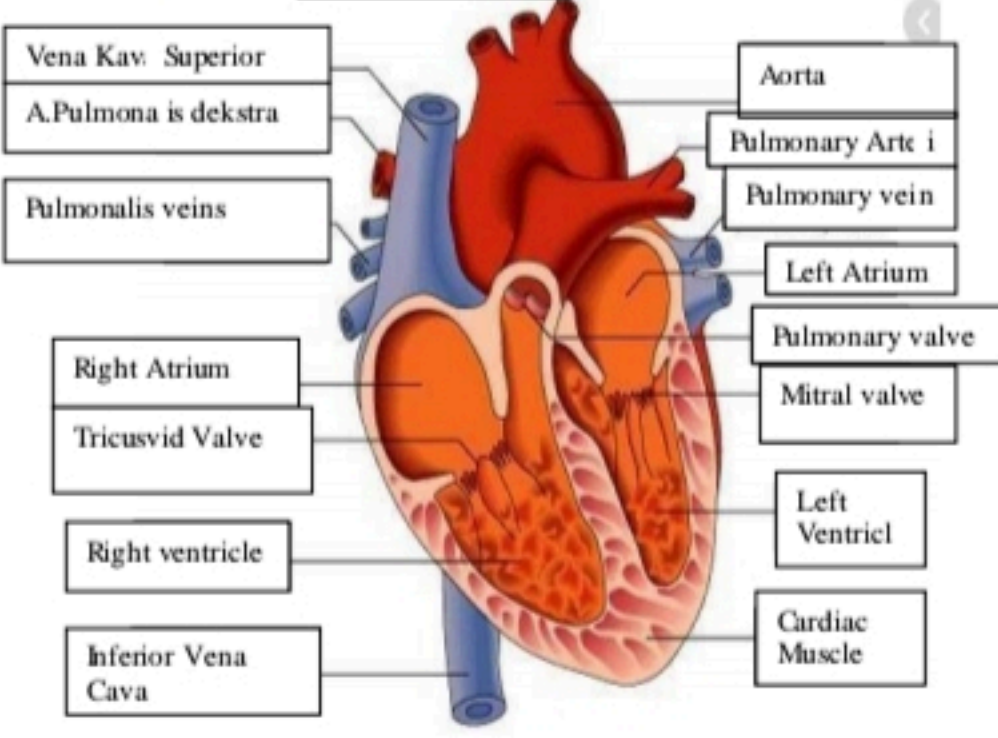


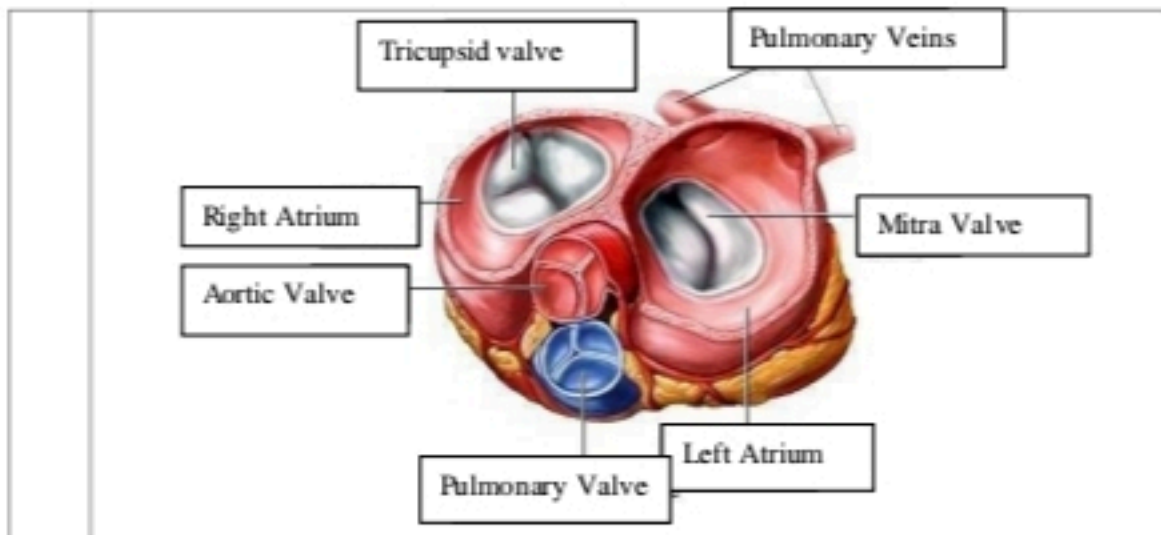
**WORKSHEETS (LEMBAR KERJA)**

Mata Kuliah	: Anatomi
Materi	: Anatomi Cardiovaskuler
NIM/Nama Mahasiswa	: 2110101058/Putri adelia

No	Keterangan	Pembahasan
----	------------	------------

1		 <p>This diagram shows a cross-section of the heart wall and its internal chambers. Labels include: Right Atrium, Left Atrium, Ventrikel Kiri (Left Ventricle), and Ventrikel Kanan (Right Ventricle). The wall layers are labeled as Endocardium (innermost), Myocardium (middle), and Epicardium (outermost). The Interventricular Arseptum (Septum) is also shown separating the ventricles.</p>
---	--	--

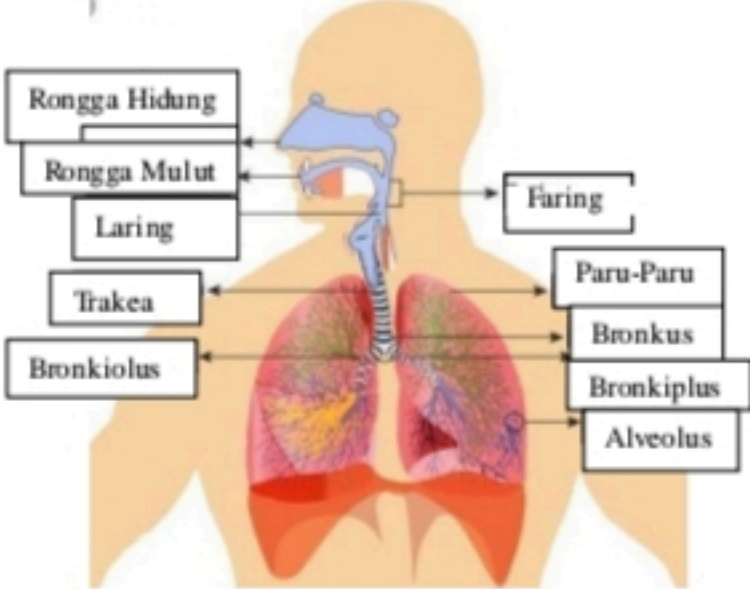
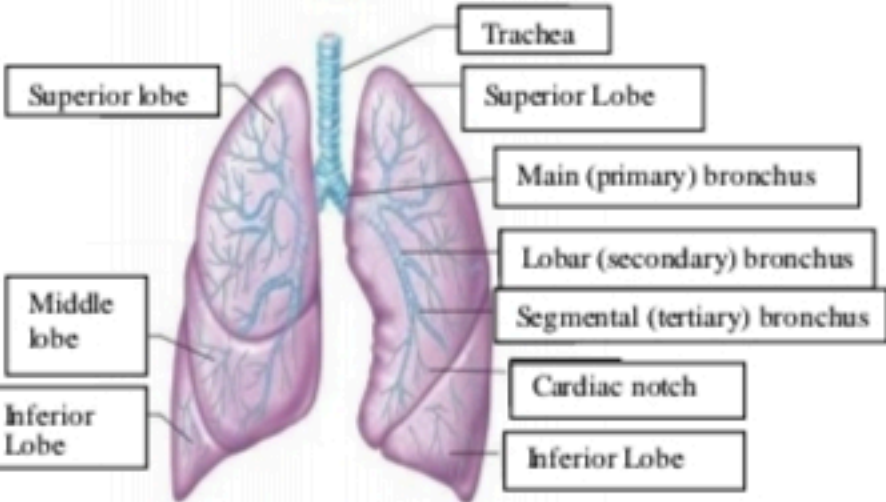
<p>Vena Kav. Superior</p> <p>A.Pulmonalis dekstra</p> <p>Pulmonalis veins</p> <p>Right Atrium</p> <p>Tricuspid Valve</p> <p>Right ventricle</p> <p>Inferior Vena Cava</p>	 <p>This diagram shows the heart with its major blood vessels and valves. Labels include: Vena Kav. Superior, A.Pulmonalis dekstra, Pulmonalis veins, Right Atrium, Tricuspid Valve, Right ventricle, Inferior Vena Cava, Aorta, Pulmonary Arteri, Pulmonary vein, Left Atrium, Pulmonary valve, Mitral valve, Left Ventricl, and Cardiac Muscle.</p>	<p>Aorta</p> <p>Pulmonary Arteri</p> <p>Pulmonary vein</p> <p>Left Atrium</p> <p>Pulmonary valve</p> <p>Mitral valve</p> <p>Left Ventricl</p> <p>Cardiac Muscle</p>
---	---	---



**WORKSHEETS (LEMBAR KERJA)**

<b>Mata Kuliah</b>	: Anatomi
<b>Materi</b>	: Anatomi Respirasi
<b>NIM&gt;Nama Mahasiswa</b>	: 2110101066/Areta Maurindha Pratiwi

No	Keterangan	Pembahasan
1	<p>An anatomical diagram of the human respiratory system. It shows the nasal cavity leading to the pharynx, which then branches into the trachea (windpipe) and bronchi (main airways). The bronchi further divide into bronchioles, which lead to the lungs (Paru-Paru Kanan and Paru-Paru Kiri). The lungs are surrounded by the pleura. The diaphragm is shown at the base of the thoracic cavity. Labels with leader lines identify each part of the system.</p>	

No	Keterangan	Pembahasan
		 <p>Diagram of the human respiratory system with labels: Rongga Hidung, Rongga Mulut, Laring, Trakea, Bronkiolus, Faring, Paru-Paru, Bronkus, Bronkiplus, Alveolus.</p>
		 <p>Detailed diagram of the lungs with labels: Superior lobe, Middle lobe, Inferior Lobe, Trachea, Superior Lobe, Main (primary) bronchus, Lobar (secondary) bronchus, Segmental (tertiary) bronchus, Cardiac notch, Inferior Lobe.</p>