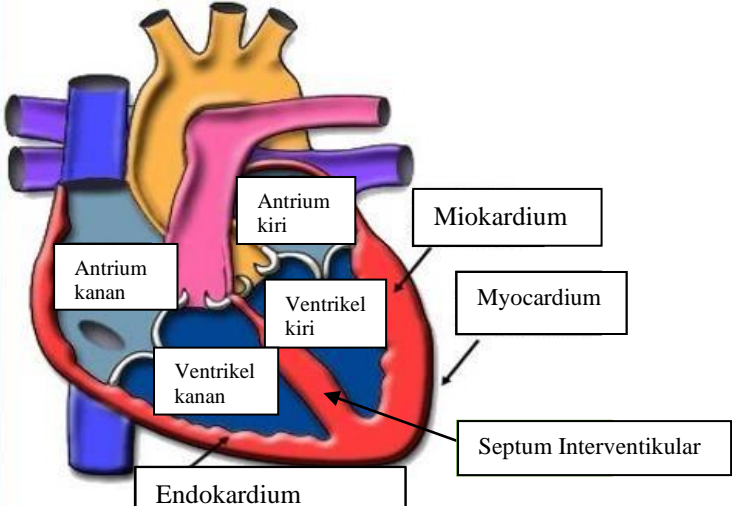
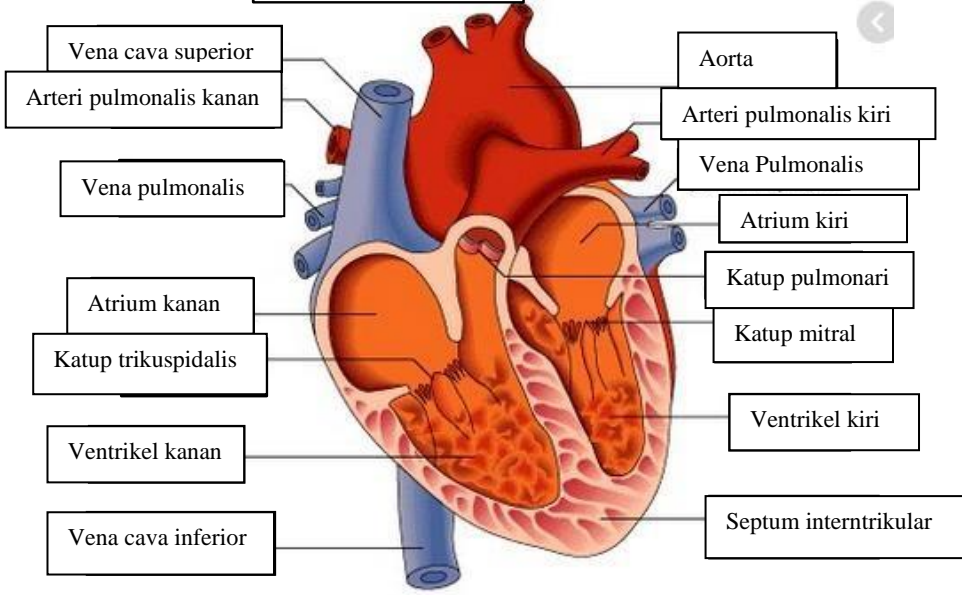
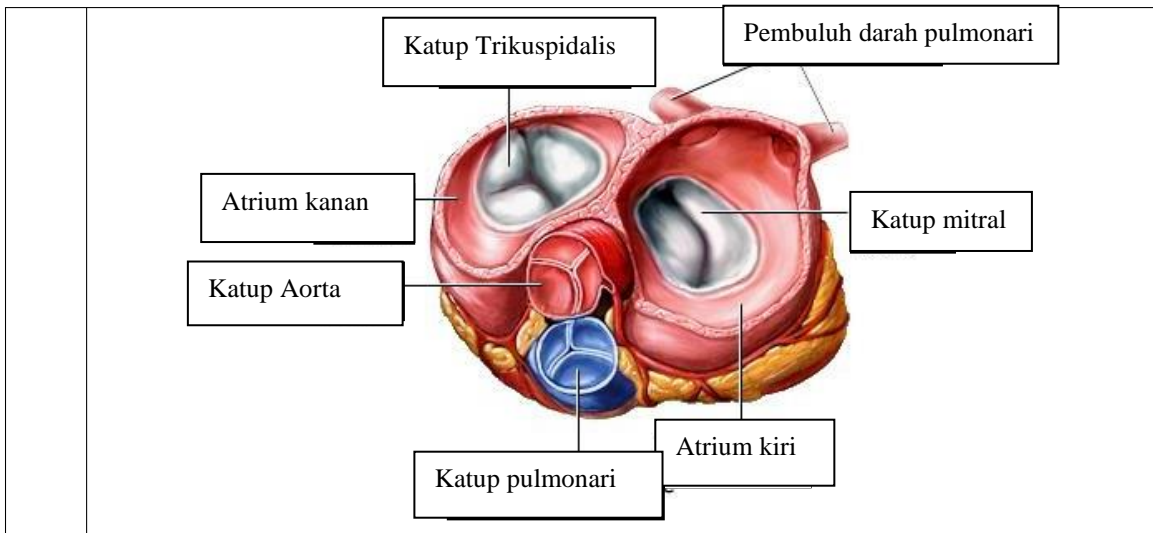


**WORKSHEETS (LEMBAR KERJA)**

|                              |                                    |
|------------------------------|------------------------------------|
| <b>Mata Kuliah</b>           | : <b>Anatomi</b>                   |
| <b>Materi</b>                | : <b>Anatomi Cardiovaskuler</b>    |
| <b>NIM&gt;Nama Mahasiswa</b> | : 2110101060/Firsta Fadhlila Putri |

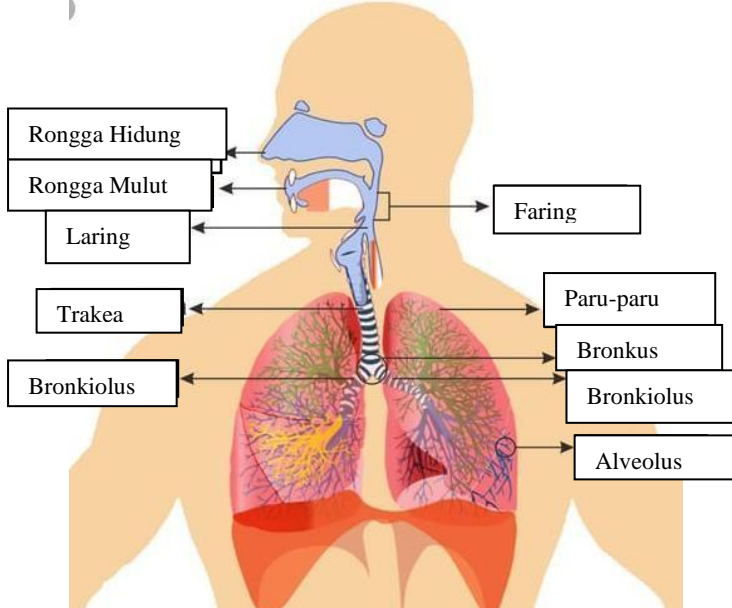
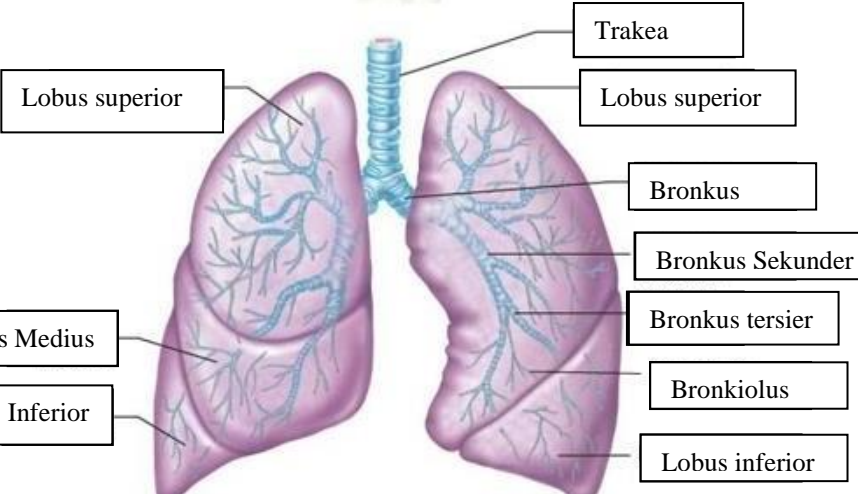
| No | Keterangan | Pembahasan   |
|----|------------|--|
| 1  |            |    |
|    |            |  |



**WORKSHEETS (LEMBAR KERJA)**

|                              |                     |
|------------------------------|---------------------|
| <b>Mata Kuliah</b>           | : Anatomi           |
| <b>Materi</b>                | : Anatomi Respirasi |
| <b>NIM&gt;Nama Mahasiswa</b> | :                   |

| No | Keterangan   | Pembahasan |
|----|--|------------|
| 1  | <p>Labels for the respiratory system diagram:</p> <ul style="list-style-type: none"> <li>Faring</li> <li>Laring</li> <li>Bronkus kanan</li> <li>Paru-paru Kanan</li> <li>Pleura</li> <li>Rongga hidung</li> <li>Trakea</li> <li>Bronkiolus</li> <li>Bronkus kiri</li> <li>Paru-paru kiri</li> <li>Diafragma</li> </ul> |            |

| No | Keterangan | Pembahasan   |
|----|------------|--|
|    |            |  <p>Diagram of the human respiratory system with labels:</p> <ul style="list-style-type: none"> <li>Rongga Hidung</li> <li>Rongga Mulut</li> <li>Laring</li> <li>Trakea</li> <li>Bronkiolus</li> <li>Faring</li> <li>Paru-paru</li> <li>Bronkus</li> <li>Bronkiolus</li> <li>Alveolus</li> </ul>                           |
|    |            |  <p>Detailed diagram of the lungs with labels:</p> <ul style="list-style-type: none"> <li>Lobus superior</li> <li>Lobus Medius</li> <li>Lobus Inferior</li> <li>Trakea</li> <li>Lobus superior</li> <li>Bronkus</li> <li>Bronkus Sekunder</li> <li>Bronkus tersier</li> <li>Bronkiolus</li> <li>Lobus inferior</li> </ul> |

