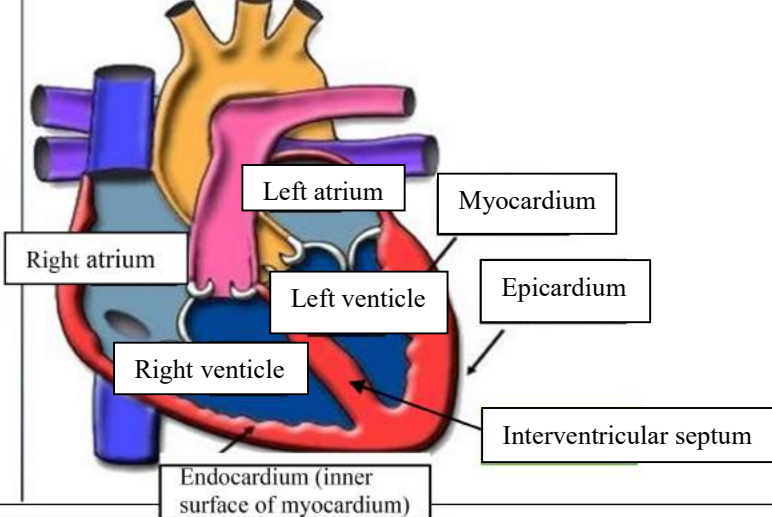
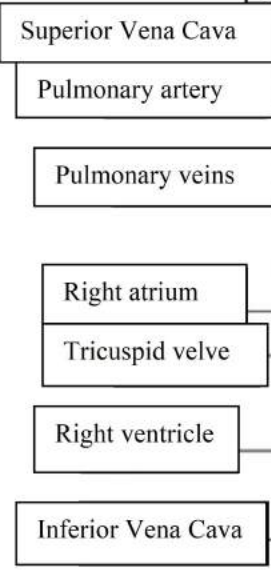
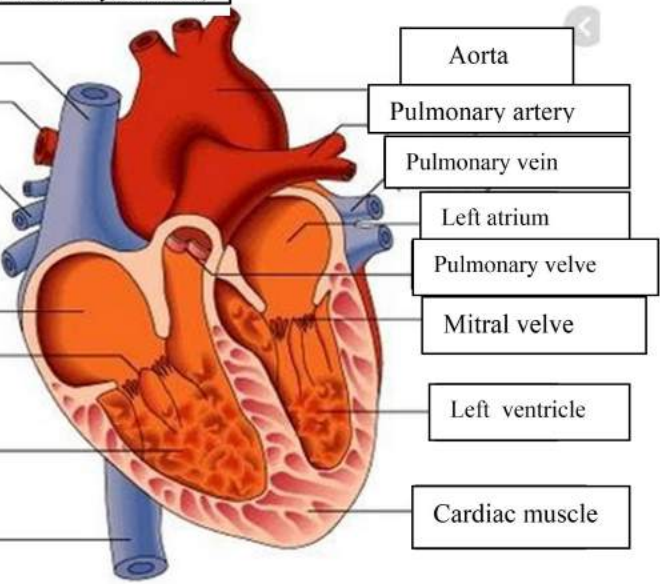
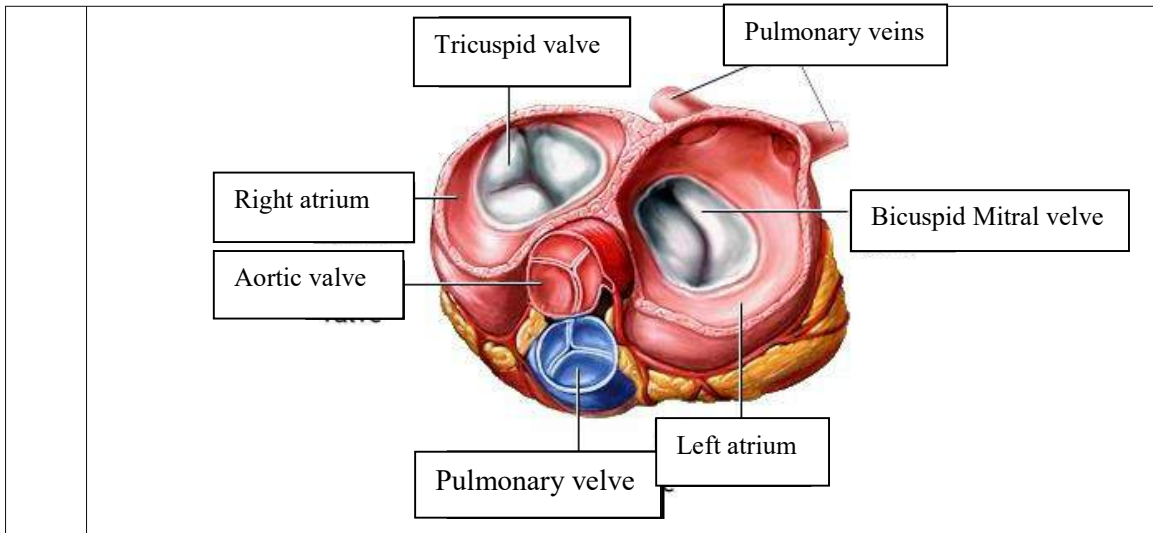


WORKSHEETS (LEMBAR KERJA)

Mata Kuliah	: Anatomi
Materi	: Anatomi Cardiovaskuler
NIM>Nama Mahasiswa	: 2110101033 / Sylvia putri

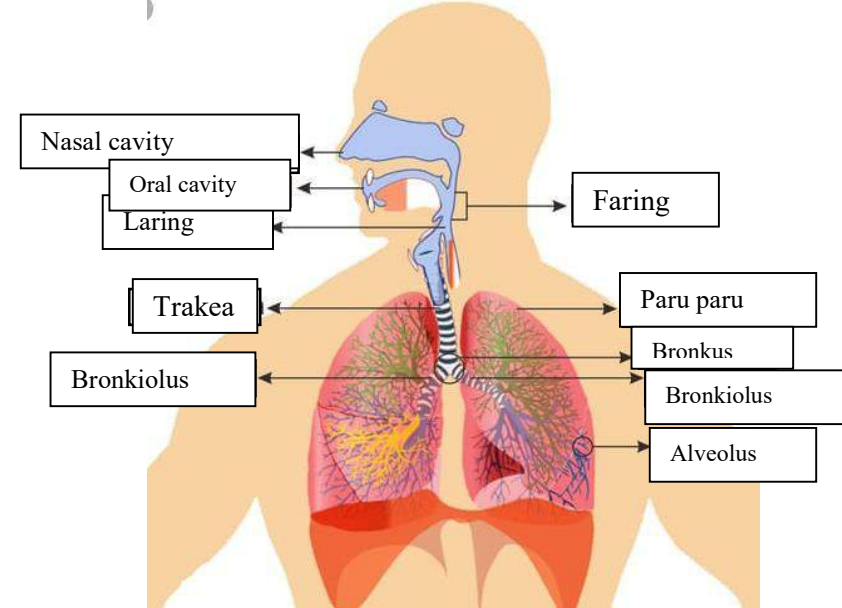
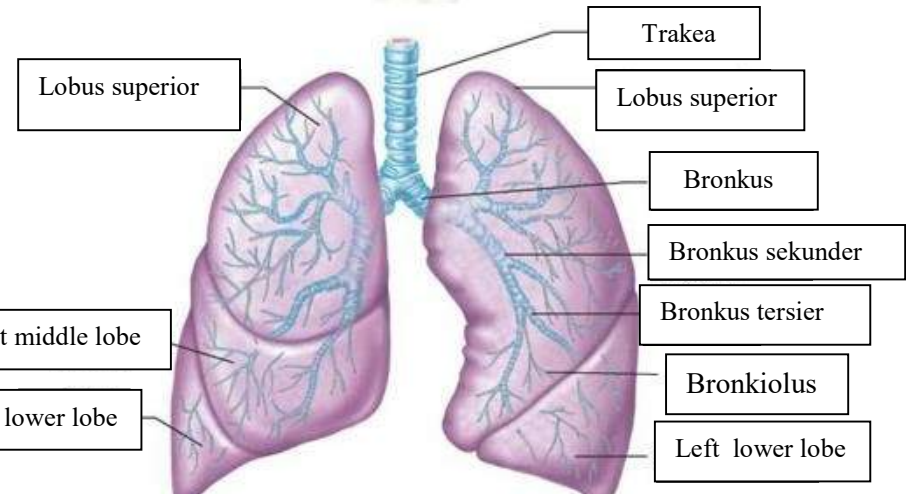
No	Keterangan	Pembahasan
1		
		



WORKSHEETS (LEMBAR KERJA)

Mata Kuliah	: Anatomi
Materi	: Anatomi Respirasi
NIM>Nama Mahasiswa	: 2110101033 / Sylvia putri

No	Keterangan	Pembahasan
1	<p>An anatomical diagram of the human respiratory system. Labels include: Faring (throat), Laring (voice box), bronkus (bronchi), Paru paru kanan (right lung), pleura (lung lining), diafragma (diaphragm), nasal cavity (nose), Trakea (trachea), Bronkiolus (bronchioles), Bronkus (bronchi), and Paru paru kiri (left lung).</p>	

No	Keterangan	Pembahasan
		 <p>Diagram of the human respiratory system with labels: Nasal cavity, Oral cavity, Laring, Faring, Trakea, Paru paru, Bronkus, Bronkiolus, Alveolus.</p>
		 <p>Detailed diagram of the lungs with labels: Trakea, Lobus superior, Bronkus, Bronkus sekunder, Bronkus tersier, Bronkiolus, Right middle lobe, Right lower lobe, Left lower lobe.</p>

