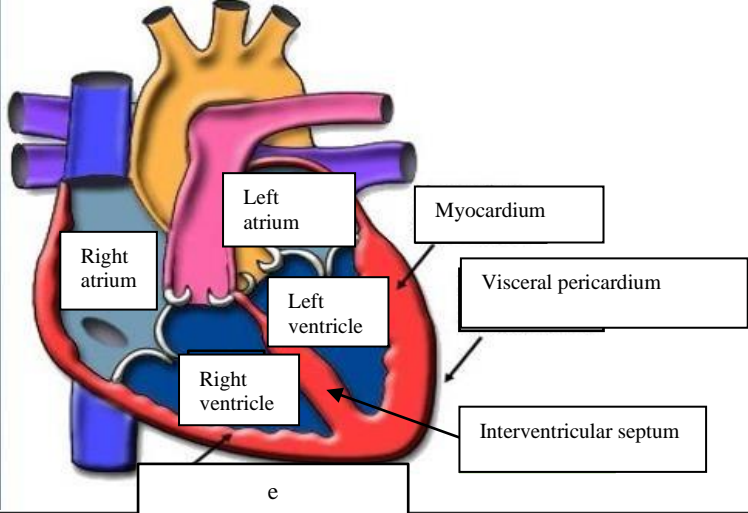
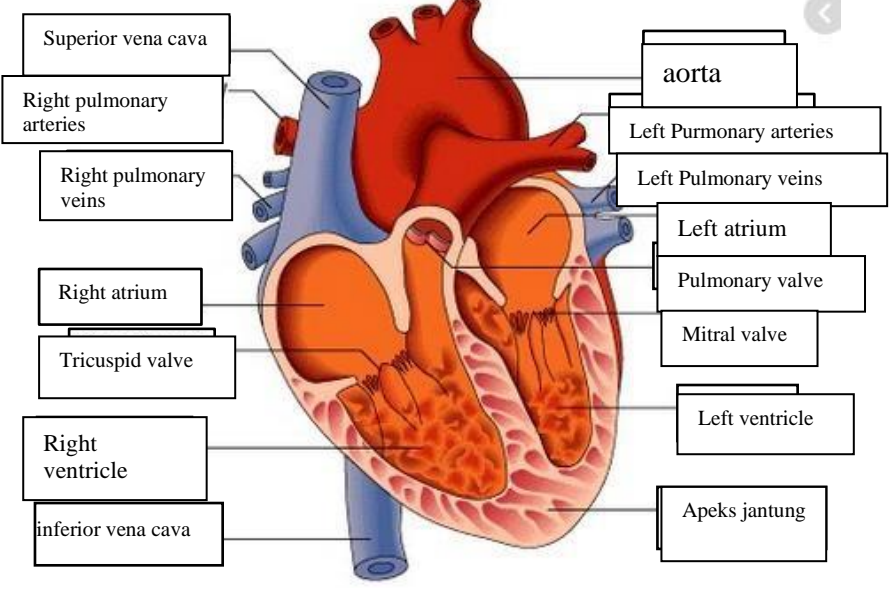
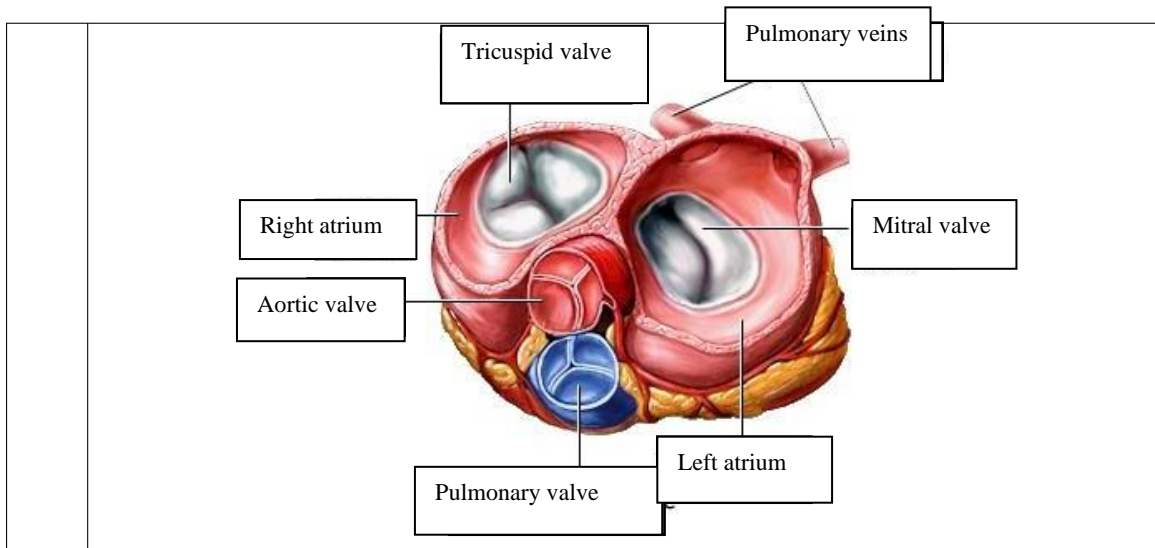


**WORKSHEETS (LEMBAR KERJA)**

<b>Mata Kuliah</b>	: <b>Anatomi</b>
<b>Materi</b>	: <b>Anatomi Cardiovaskuler</b>
<b>NIM&gt;Nama Mahasiswa</b>	: <b>2110101041/DWI YANTI</b>

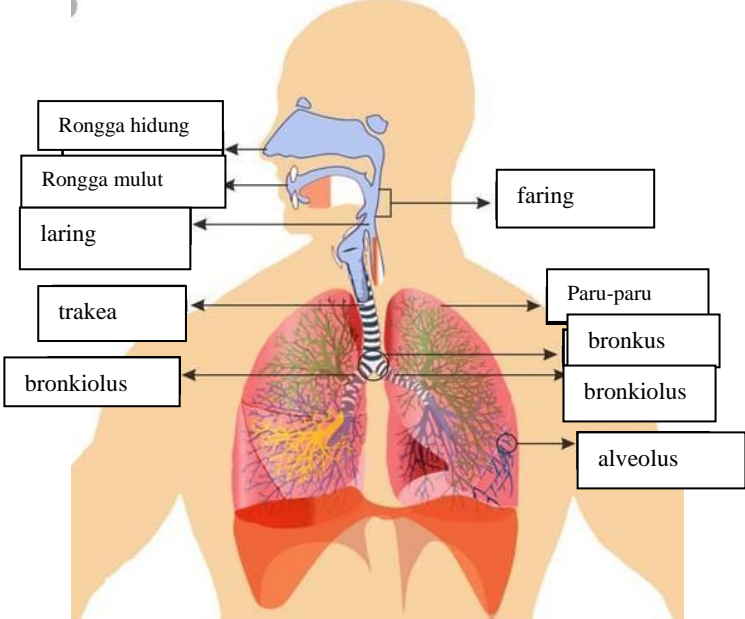
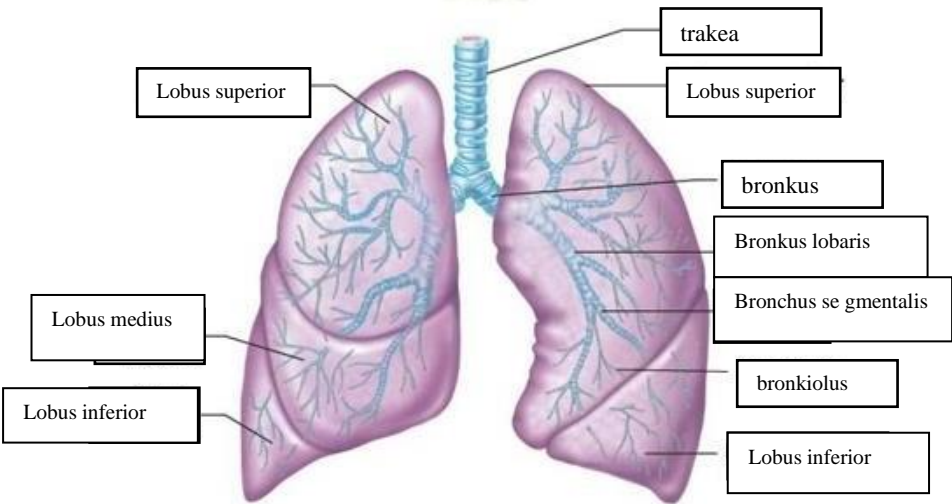
No	Keterangan	Pembahasan
1		
		



**WORKSHEETS (LEMBAR KERJA)**

<b>Mata Kuliah</b>	: Anatomi
<b>Materi</b>	: Anatomi Respirasi
<b>NIM&gt;Nama Mahasiswa</b>	: 2110101041/DWI YANTI

No	Keterangan	Pembahasan
1	<p>An anatomical diagram of the human respiratory system. Labels include: faring (pharynx), laring (larynx), bronchus, Paru-paru kanan (right lung), pleura, diafragma (diaphragm), Rongga hidung (nasal cavity), trachea, bronkiolus (bronchioles), bronkus (bronchus), and paru-paru kiri (left lung).</p>	

No	Keterangan	Pembahasan
		 <p>Diagram of the human respiratory system with labels: Rongga hidung, Rongga mulut, laring, trakea, bronkiolus, faring, Paru-paru, bronkus, bronkiolus, and alveolus.</p>
		 <p>Detailed diagram of the lungs with labels: trakea, Lobus superior, Lobus medius, Lobus inferior, bronkus, Bronkus lobaris, Bronchus segmentalis, bronkiolus, and Lobus inferior.</p>

