

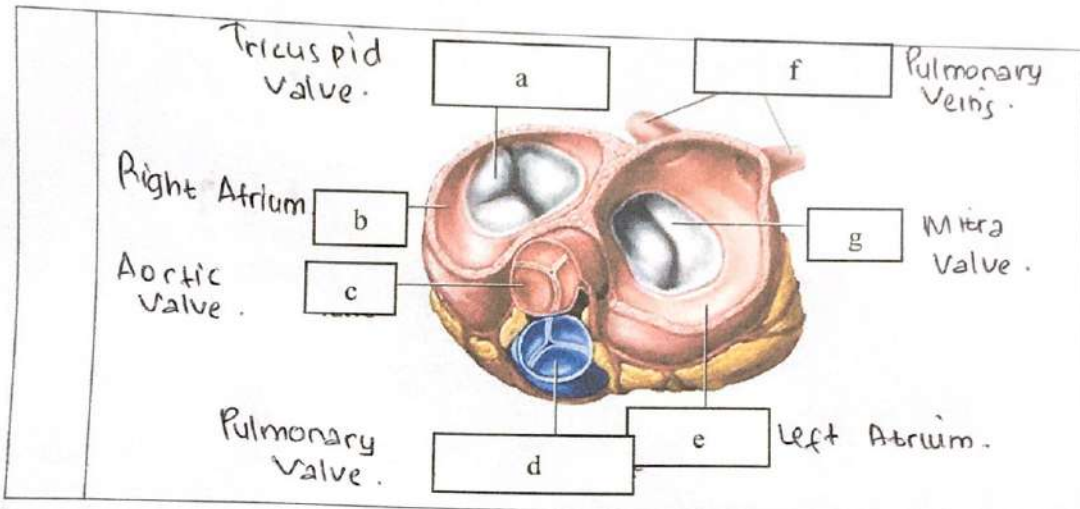
WORKSHEETS (LEMBAR KERJA)

Mata Kuliah	: Anatomi
Materi	: Anatomi Cardiovaskuler
NIM>Nama Mahasiswa	: 2110101038 / Baiba Awiktamara Hisa.

No	Keterangan	Pembahasan
----	------------	------------

1	<p>c. Right Atrium.</p> <p>d. Right Ventricle.</p> <p>Endocardium. e</p>	<p>a. Left Atrium.</p> <p>b. Left Ventricle.</p> <p>c. Right Atrium.</p> <p>d. Right Ventricle.</p> <p>e. Endocardium.</p> <p>f. Epicardium.</p> <p>g. Myocardium.</p> <p>h. Interventricular Septum.</p>
---	--	---

<p>Vena kava Superior.</p> <p>Pulmonary artery.</p> <p>Pulmonary Veins.</p> <p>Right Atrium.</p> <p>Tricuspid Valve.</p> <p>Right Ventricle.</p> <p>Vena kava inferior</p>		<p>J</p> <p>K</p> <p>L</p> <p>Right Atrium.</p> <p>Q</p> <p>Right Ventricle.</p> <p>R</p> <p>I Aorta</p> <p>M Pulmonary artery.</p> <p>N Pulmonary vein.</p> <p>Left Atrium.</p> <p>O Pulmonary Valve.</p> <p>P Mitral Valve.</p> <p>Left Ventricle</p> <p>Cardiac Muscle.</p>
--	--	--



WORKSHEETS (LEMBAR KERJA)

Mata Kuliah	: Anatomi
Materi	: Anatomi Respirasi
NIM>Nama Mahasiswa	: 2110101038 / Balta Awiktamara Nisa.

No	Keterangan	Pembahasan
1	<p>Faring. a b Rongga hidung.</p> <p>Laring c d Trakea.</p> <p>Bronkus e f Bronkiolus.</p> <p>Paru-paru kanan. g Bronkus.</p> <p>Pleura. h Paru-paru kiri.</p> <p>i</p> <p>Diafragma.</p>	

No	Keterangan	Pembahasan
----	------------	------------

