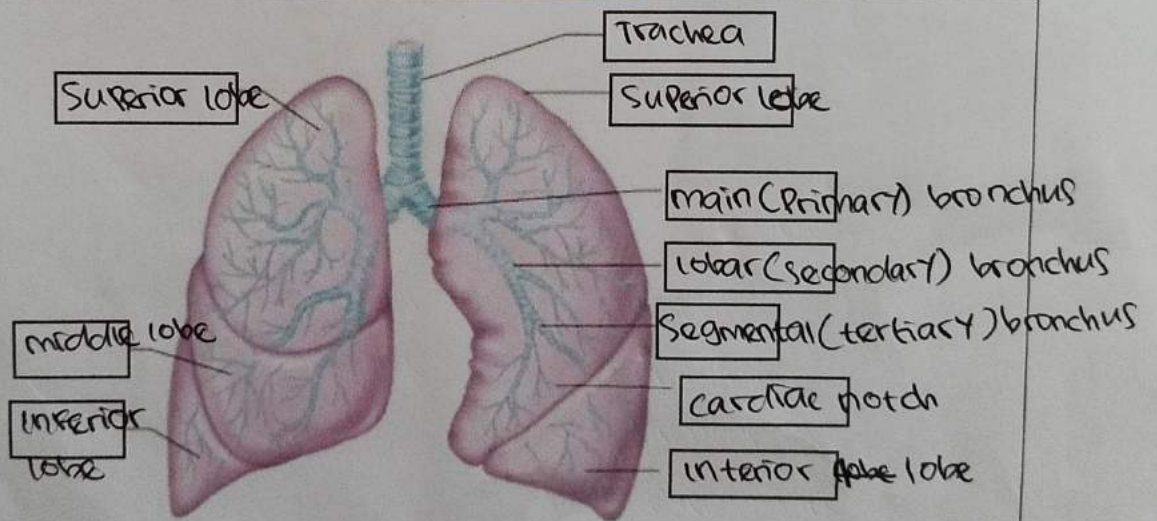
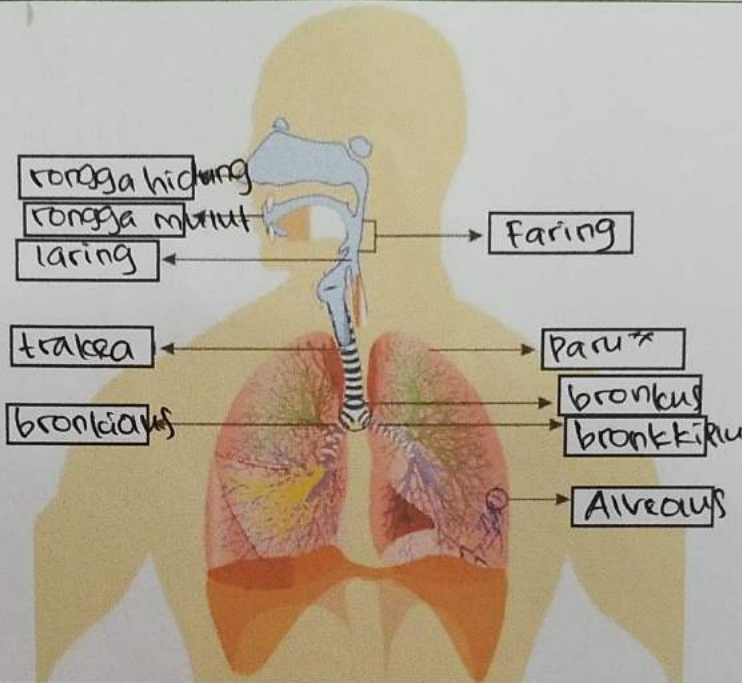
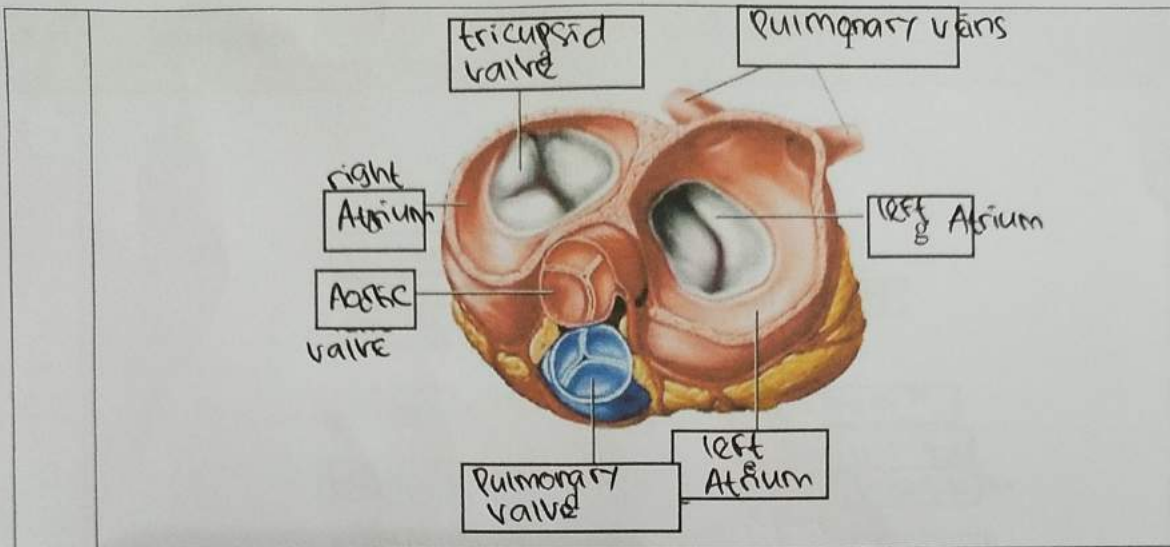


| No | Keterangan | Pembahasan |
|----|------------|------------|
|----|------------|------------|





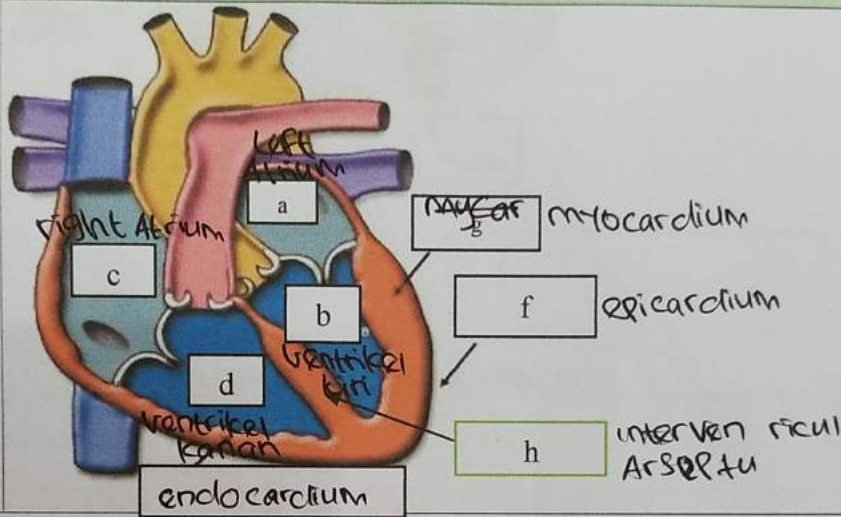
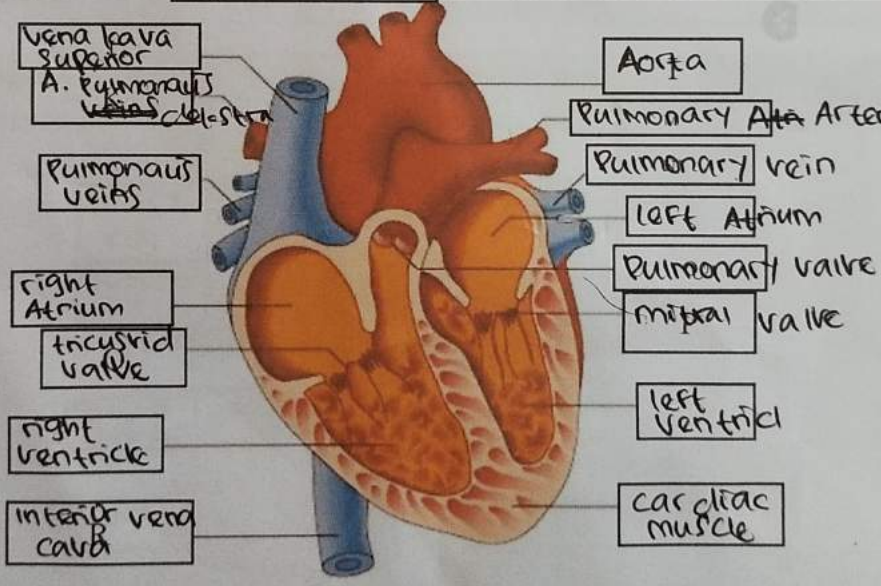
WORKSHEETS (LEMBAR KERJA)

| | |
|--------------------|------------------------------|
| Mata Kuliah | : Anatomi |
| Materi | : Anatomi Respirasi |
| NIM>Nama Mahasiswa | : 210101034 / Lia Agusmarina |

| No | Keterangan | Pembahasan |
|----|--|------------|
| 1 | <p>Diagram of the respiratory system showing the following labeled parts:</p> <ul style="list-style-type: none"> Pharynx esophagus bronchus paru x kanan pleura nasal cavity trachea bronchiolus bronchus paru x kiri diafragma | |

WORKSHEETS (LEMBAR KERJA)

| | |
|--------------------|-----------------------------|
| Mata Kuliah | : Anatomi |
| Materi | : Anatomi Cardiovaskuler |
| NIM>Nama Mahasiswa | : 21101034 / Lia Agusmarina |

| No | Keterangan | Pembahasan |
|----|------------|---|
| 1 | |  <p>Labels in diagram:</p> <ul style="list-style-type: none"> a: Left Atrium b: Ventrikel kiri c: Right Atrium d: Ventrikel kanan endocardium myocardium epicardium h: interventricular septum |
| | |  <p>Labels in diagram:</p> <ul style="list-style-type: none"> Vena kava superior A. pulmonalis Pulmonalis veins right Atrium tricuspid valve right ventricle inferior vena cava Aorta Pulmonary Artery Pulmonary vein left Atrium Pulmonary valve mitral valve left ventricle cardiac muscle |