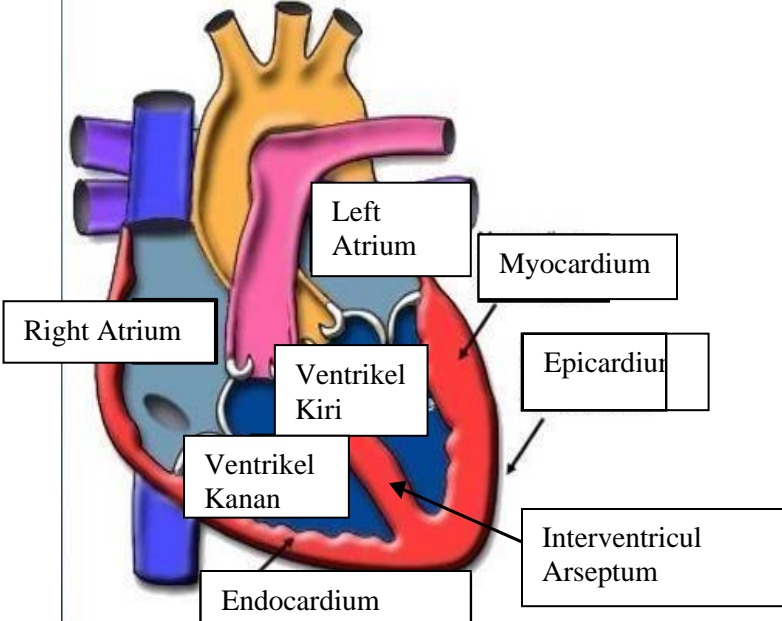
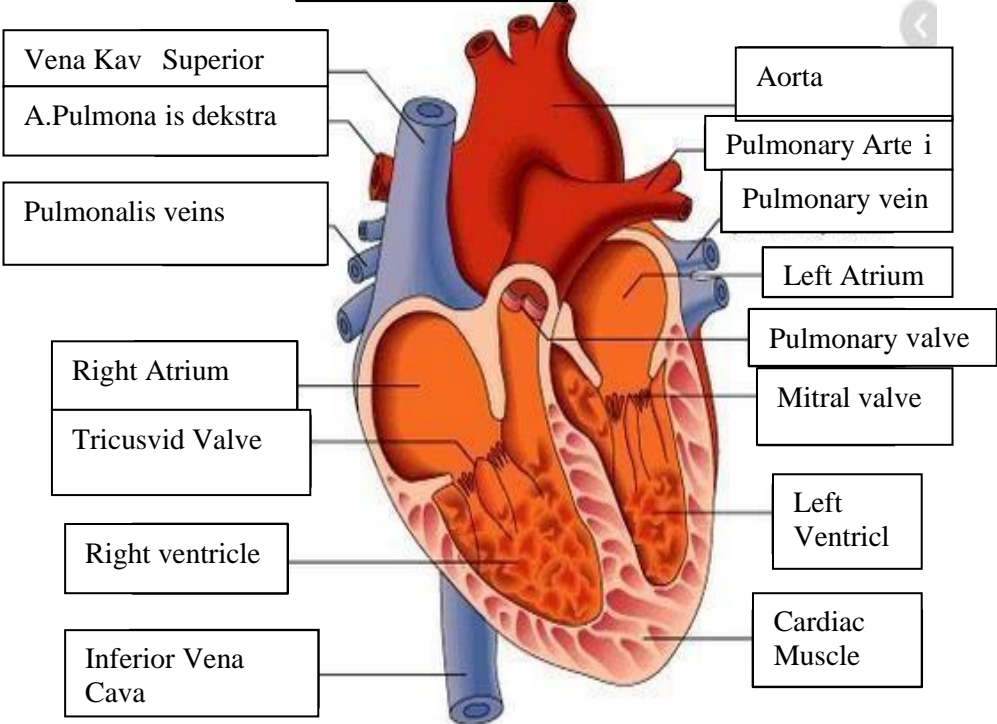
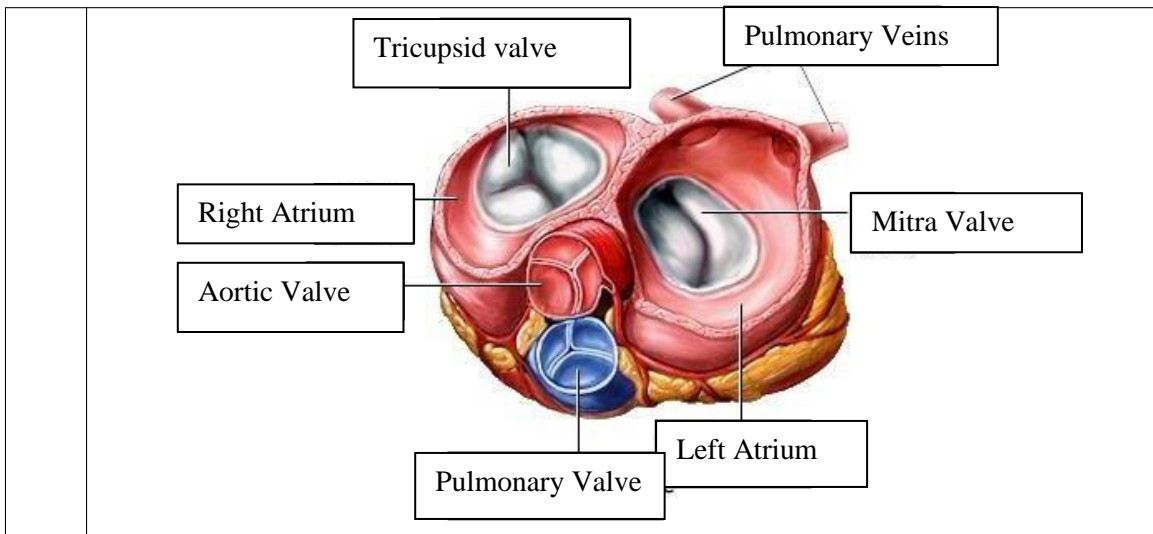


WORKSHEETS (LEMBAR KERJA)

Mata Kuliah	: Anatomi
Materi	: Anatomi Cardiovaskuler
NIM/Nama Mahasiswa	: 2110101066/Areta Maurindha Pratiwi

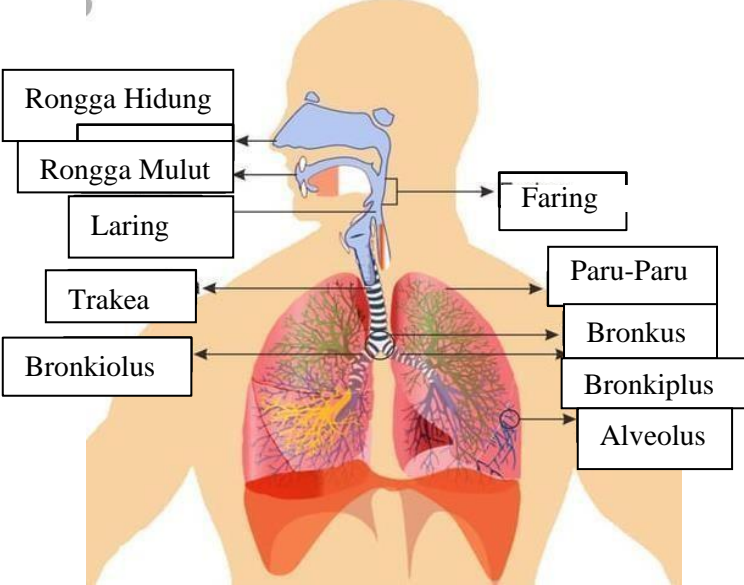
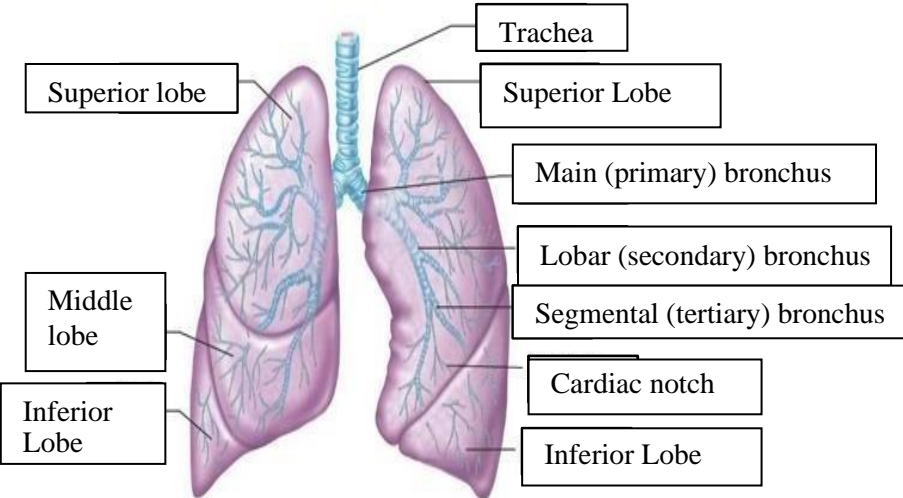
No	Keterangan	Pembahasan
1		 <p>This diagram shows a cross-section of the heart wall. The layers from the inside out are the Endocardium, Myocardium, and Epicardium. The Interventricular Arseptum (Septum) is shown separating the two ventricles. Labels include: Right Atrium, Left Atrium, Ventrikel Kiri (Left Ventricle), Ventrikel Kanan (Right Ventricle), Myocardium, Epicardium, Endocardium, and Interventricul Arseptum.</p>
	 <p>This diagram shows a cross-section of the heart with its major vessels and valves. Labels on the left side include: Vena Kav Superior (Superior Vena Cava), A.Pulmona is dekstra (Right Pulmonary Artery), Pulmonalis veins (Pulmonary Veins), Right Atrium, Tricusvid Valve (Tricuspid Valve), Right ventricle, and Inferior Vena Cava (Inferior Vena Cava). Labels on the right side include: Aorta, Pulmonary Arte i (Pulmonary Artery), Pulmonary vein, Left Atrium, Pulmonary valve, Mitral valve, Left Ventricl (Left Ventricle), and Cardiac Muscle.</p>	



WORKSHEETS (LEMBAR KERJA)

Mata Kuliah	: Anatomi
Materi	: Anatomi Respirasi
NIM>Nama Mahasiswa	: 2110101066/Areta Maurindha Pratiwi

No	Keterangan	Pembahasan
1		<p>An anatomical diagram of the human respiratory system. It shows the nasal cavity leading to the pharynx, which branches into the trachea (windpipe) and the esophagus. The trachea leads to the bronchi, which branch into bronchioles and finally reach the lungs (paru-paru kanan and paru-paru kiri). The lungs are surrounded by the pleura, and the diaphragm is located at the base of the thoracic cavity. Labels with leader lines identify each of these parts.</p>

No	Keterangan	Pembahasan
		 <p>Diagram of the human respiratory system with labels: Rongga Hidung, Rongga Mulut, Laring, Trakea, Bronkiolus, Faring, Paru-Paru, Bronkus, Bronkiplus, Alveolus.</p>
		 <p>Detailed diagram of the lungs with labels: Superior lobe, Middle lobe, Inferior Lobe, Trachea, Superior Lobe, Main (primary) bronchus, Lobar (secondary) bronchus, Segmental (tertiary) bronchus, Cardiac notch, Inferior Lobe.</p>

