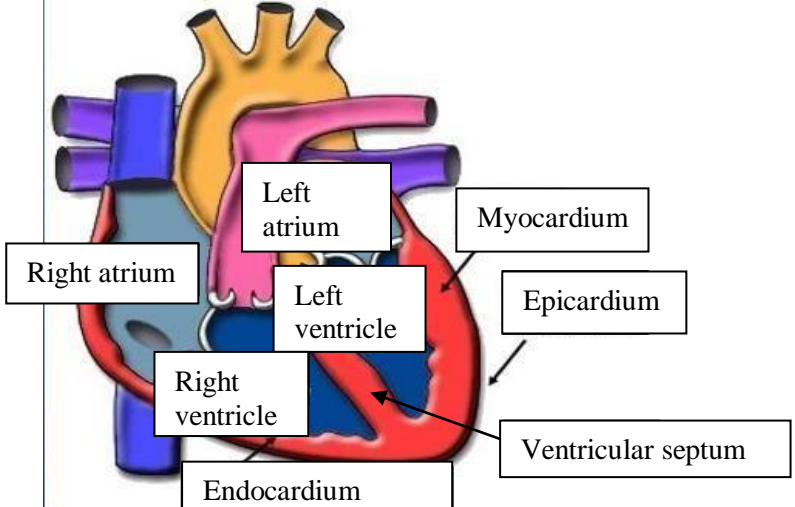
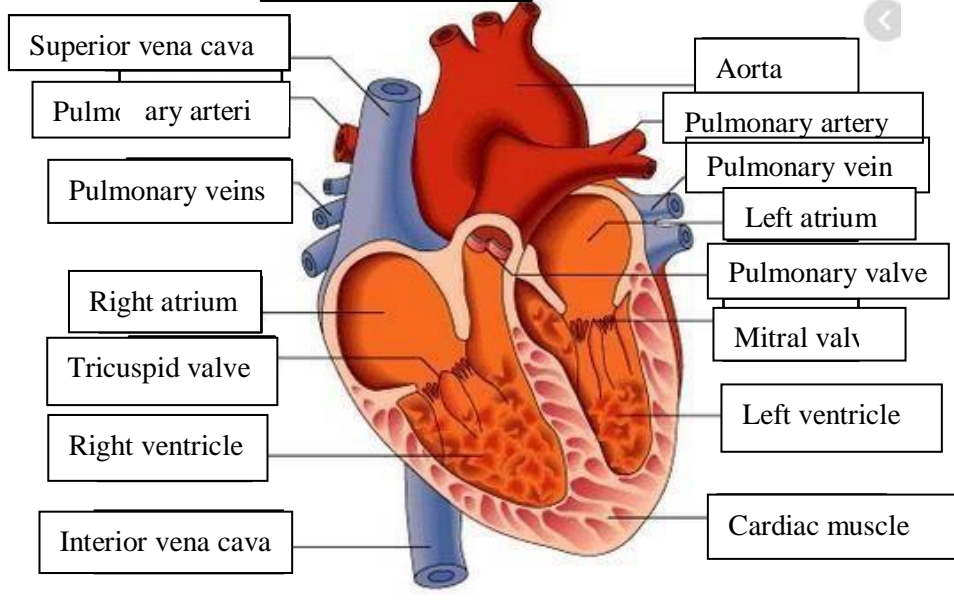
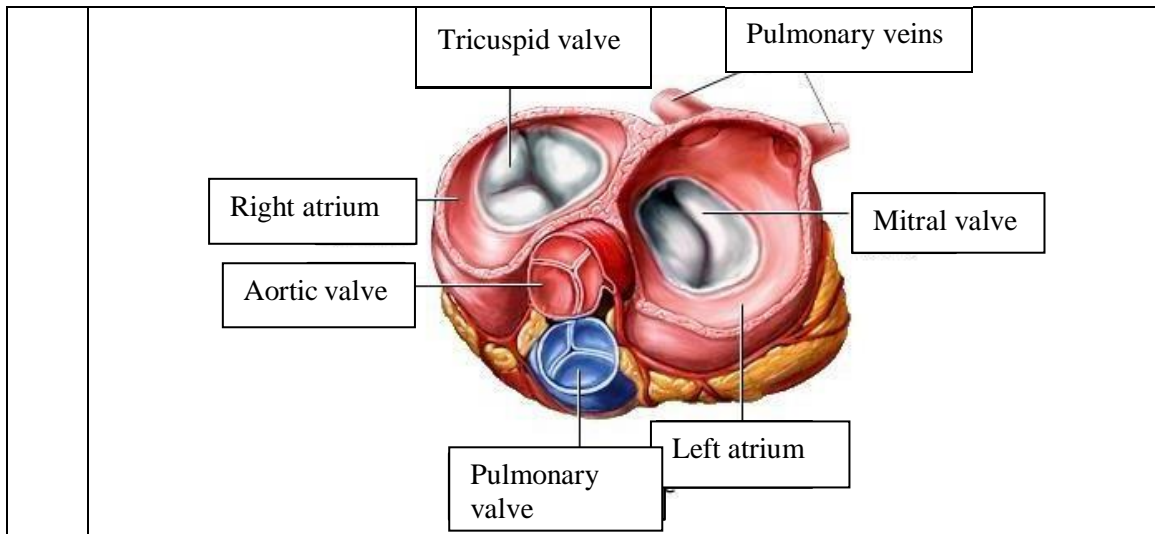


WORKSHEETS (LEMBAR KERJA)

| | |
|------------------------------|--|
| Mata Kuliah | : Anatomi |
| Materi | : Anatomi Cardiovaskuler |
| NIM>Nama Mahasiswa | : 2110101051 / Tjahya Pramudyaning Sumantri |

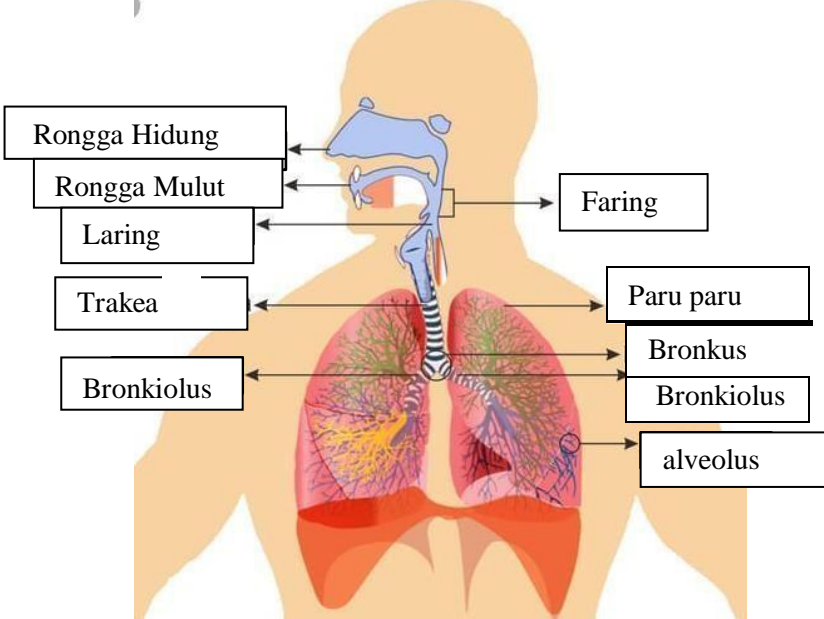
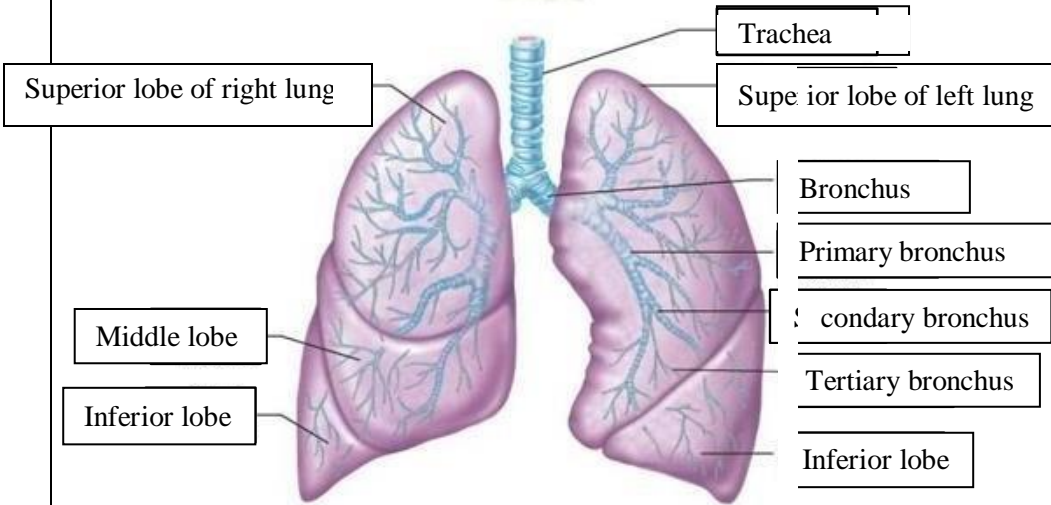
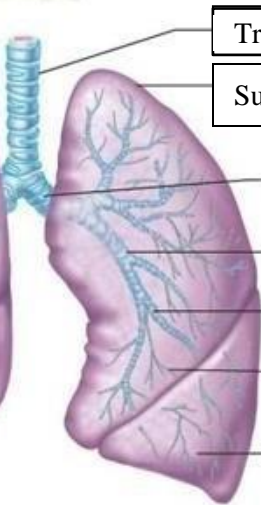
| No | Keterangan | Pembahasan |
|----|------------|--|
| 1 | |  |
| | |  |



WORKSHEETS (LEMBAR KERJA)

| | |
|------------------------------|---------------------------|
| Mata Kuliah | : Anatomi |
| Materi | : Anatomi Respirasi |
| NIM>Nama Mahasiswa | : MARIANA ULFA_2110101111 |

| No | Keterangan | Pembahasan |
|----|---|------------|
| 1 | <p>An anatomical diagram of the human respiratory system. It shows the nasal cavity (Rongga hidung), pharynx (Faring), larynx (Laring), trachea (Trakea), bronchi (Bronchus), bronchioles (Bronkiolus), and the two lungs (Right lobes and Left lobes). The pleura (Pluera) is shown covering the lungs, and the diaphragm (Diafragma) is at the base. Labels with leader lines identify each part.</p> | |

| No | Keterangan | Pembahasan |
|----|---|---|
| | |  <p>Diagram of the human respiratory system with labels: Rongga Hidung, Rongga Mulut, Laring, Trakea, Bronkiolus, Faring, Paru paru, Bronkus, Bronkiolus, alveolus.</p> |
| |  <p>Labels for lung lobes: Superior lobe of right lung, Middle lobe, Inferior lobe, Superior lobe of left lung, Inferior lobe.</p> |  <p>Labels for bronchial structure: Trachea, Bronchus, Primary bronchus, Secondary bronchus, Tertiary bronchus.</p> |

