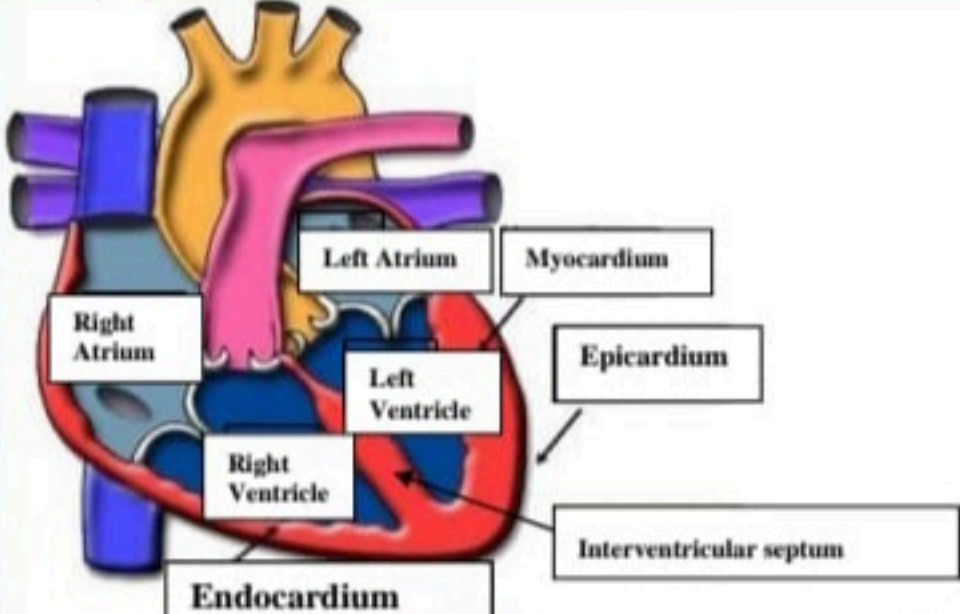
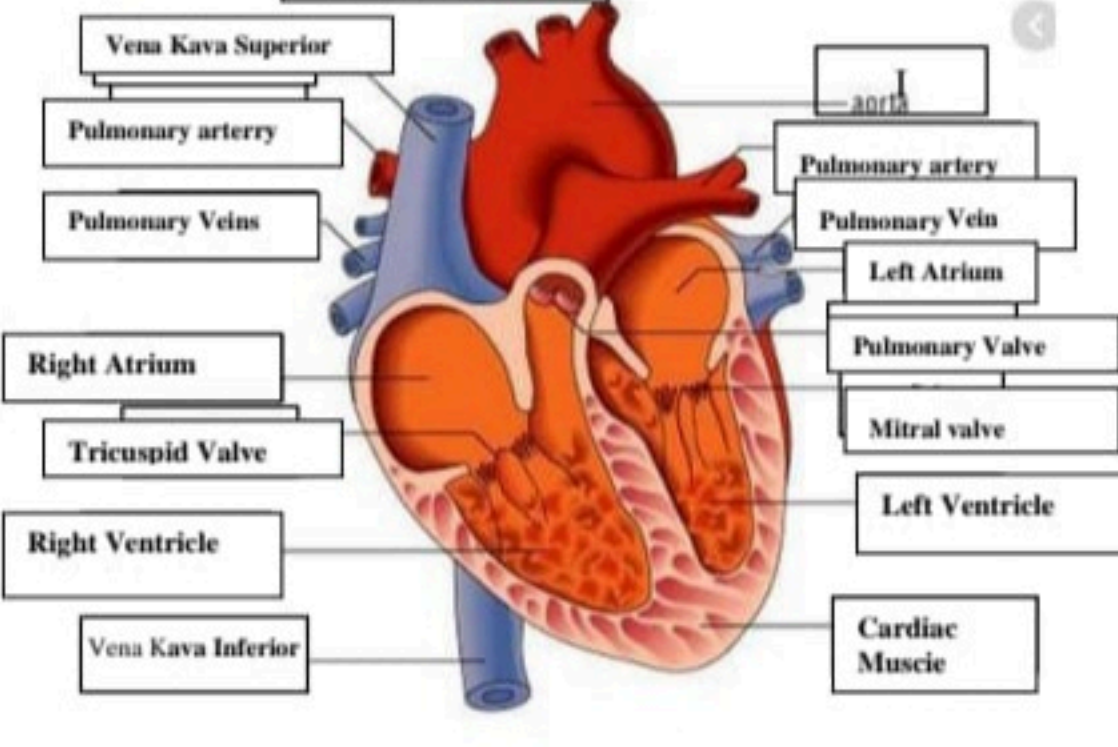
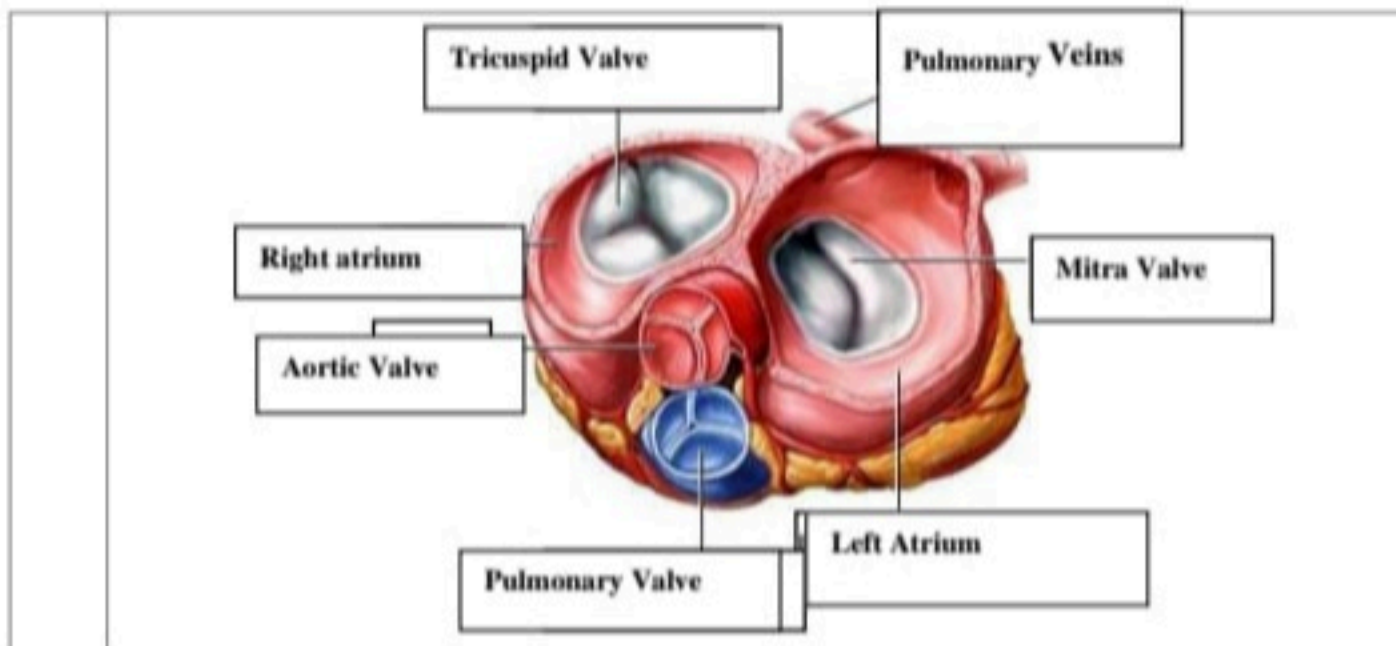


**WORKSHEETS (LEMBAR KERJA)**

<b>Mata Kuliah</b>	: Anatomi
<b>Materi</b>	: Anatomi Cardiovaskuler
<b>NIM&gt;Nama Mahasiswa</b>	: 2110101010/Rasya Captiani

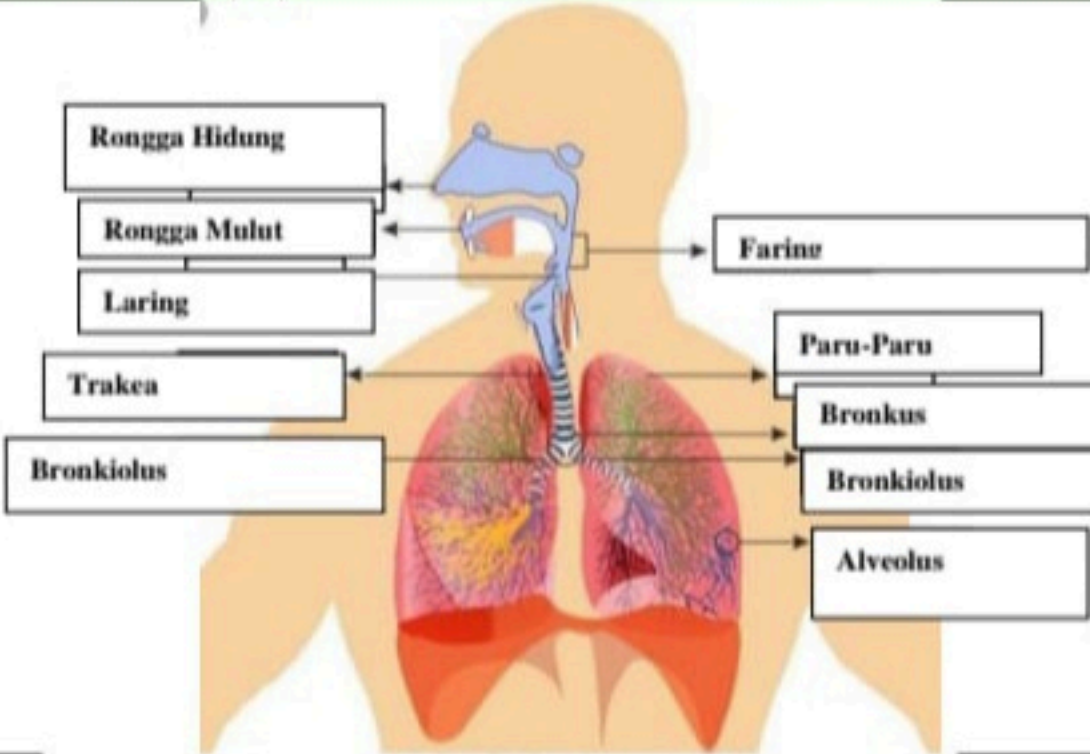
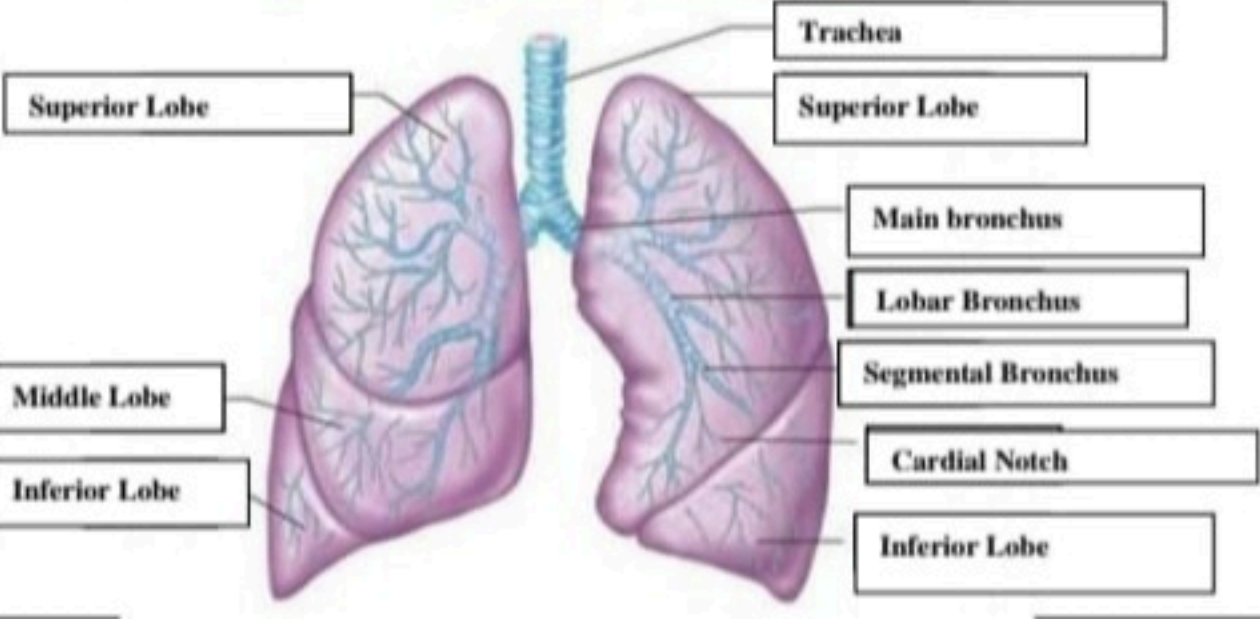
No	Keterangan	Pembahasan
1		
		



**WORKSHEETS (LEMBAR KERJA)**

<b>Mata Kuliah</b>	: Anatomi
<b>Materi</b>	: Anatomi Respirasi
<b>NIM&gt;Nama Mahasiswa</b>	: 2110101010/Rasya Captiani

No	Keterangan	Pembahasan
1	<p>An anatomical diagram of the human respiratory system. Labels on the left side include: Faring, Laring, Bronkus, Paru-Paru kanan, Pleura, and Diafragma. Labels on the right side include: Rongga Hidung, Trakea, Bronkiolus, Bronkus, and Paru-Paru kiri. The diagram shows the nasal cavity, larynx, trachea, bronchi, bronchioles, and the two lungs, with the diaphragm at the base.</p>	

No	Keterangan	Pembahasan
		 <p>Diagram of the human respiratory system with labels:</p> <ul style="list-style-type: none"> <li>Rongga Hidung</li> <li>Rongga Mulut</li> <li>Laring</li> <li>Trakea</li> <li>Bronkiolus</li> <li>Faringe</li> <li>Paru-Paru</li> <li>Bronkus</li> <li>Bronkiolus</li> <li>Alveolus</li> </ul>
		 <p>Detailed diagram of the lungs with labels:</p> <ul style="list-style-type: none"> <li>Superior Lobe</li> <li>Middle Lobe</li> <li>Inferior Lobe</li> <li>Trachea</li> <li>Superior Lobe</li> <li>Main bronchus</li> <li>Lobar Bronchus</li> <li>Segmental Bronchus</li> <li>Cardial Notch</li> <li>Inferior Lobe</li> </ul>