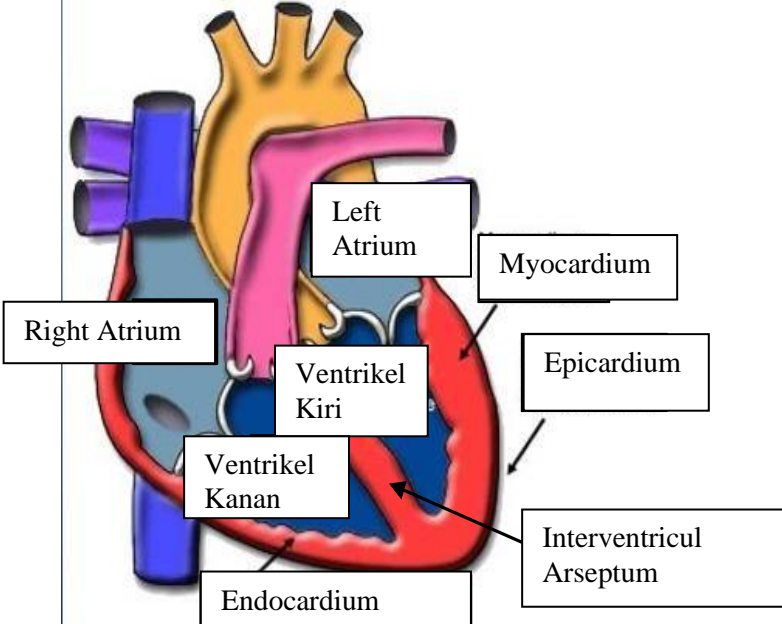
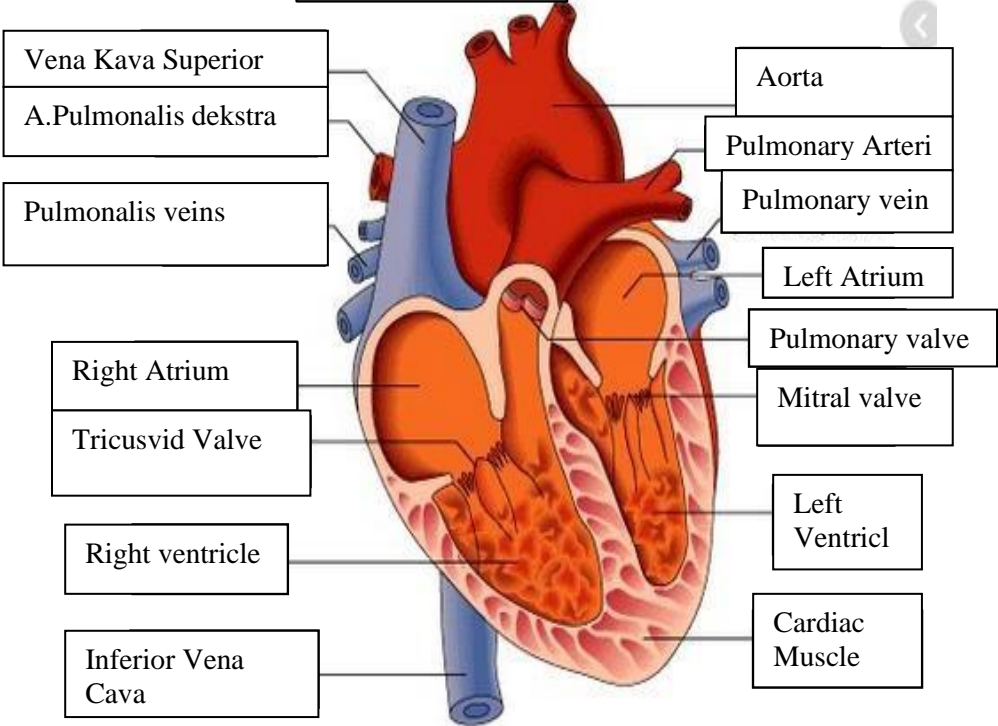
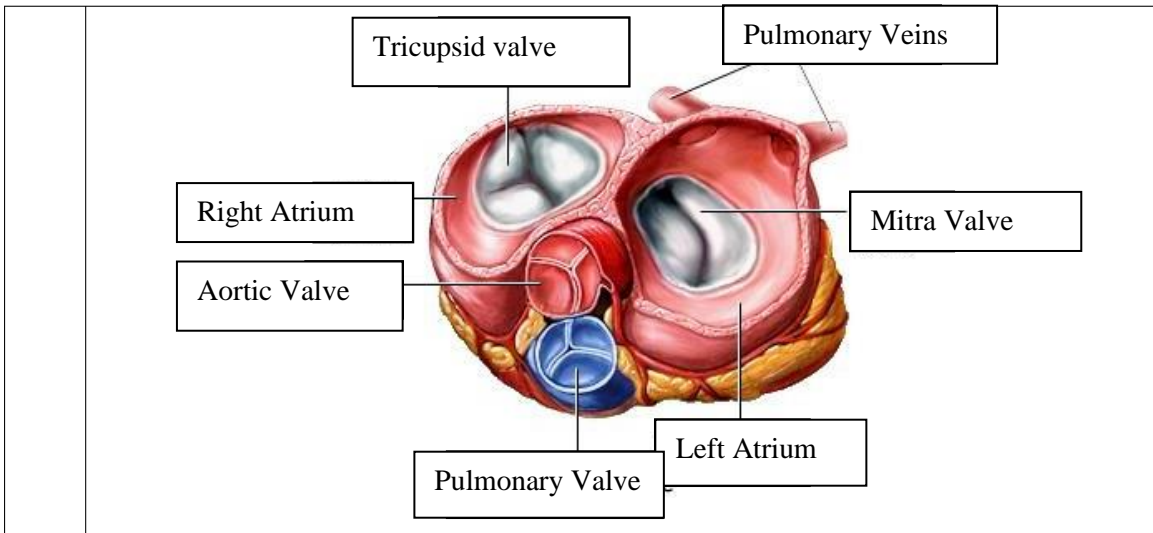


**WORKSHEETS (LEMBAR KERJA)**

<b>Mata Kuliah</b>	: <b>Anatomi</b>
<b>Materi</b>	: <b>Anatomi Cardiovaskuler</b>
<b>NIM/Nama Mahasiswa</b>	: <b>2110101112/ Mufidah</b>

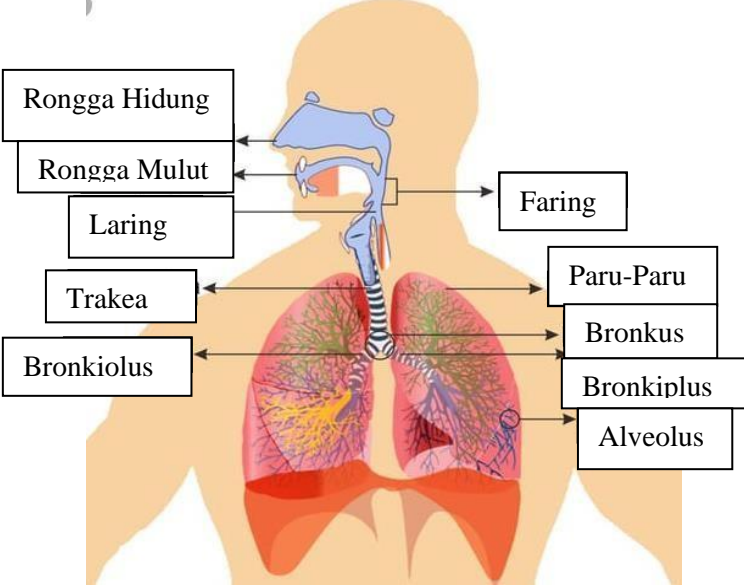
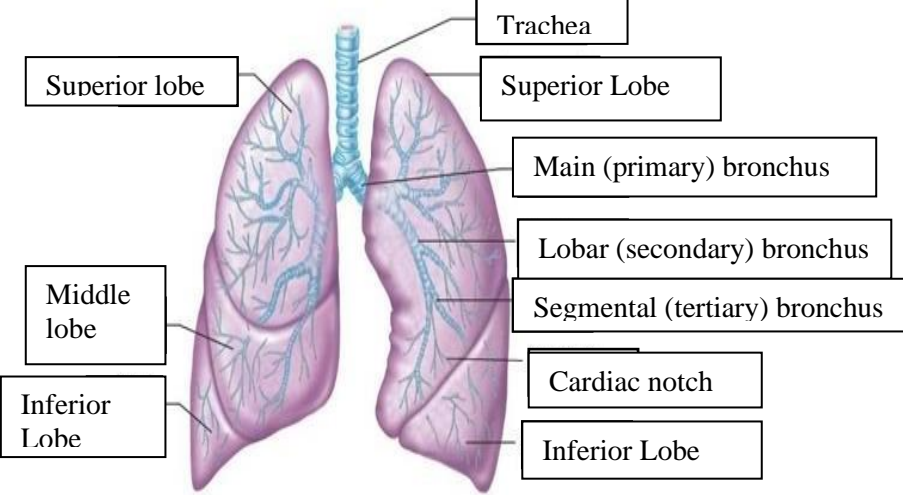
No	Keterangan	Pembahasan
1		 <p>This diagram shows a cross-section of the heart wall with the following labels: Right Atrium, Left Atrium, Myocardium, Epicardium, Endocardium, Ventrikel Kiri (Left Ventricle), Ventrikel Kanan (Right Ventricle), and Interventricul Arseptum (Interventricular Septum).</p>
		 <p>This diagram shows a cross-section of the heart with the following labels: Vena Kava Superior, A.Pulmonalis dekstra, Pulmonalis veins, Right Atrium, Tricusvid Valve, Right ventricle, Inferior Vena Cava, Aorta, Pulmonary Arteri, Pulmonary vein, Left Atrium, Pulmonary valve, Mitral valve, Left Ventricl, and Cardiac Muscle.</p>



**WORKSHEETS (LEMBAR KERJA)**

<b>Mata Kuliah</b>	: Anatomi
<b>Materi</b>	: Anatomi Respirasi
<b>NIM&gt;Nama Mahasiswa</b>	: 2110101112/ Mufidah

No	Keterangan	Pembahasan
1	<p>An anatomical diagram of the human respiratory system, showing the upper and lower respiratory tracts. The diagram is labeled with the following parts:</p> <ul style="list-style-type: none"> <li>Pharynx</li> <li>Esophagus</li> <li>Bronkus</li> <li>Paru Paru Kanan</li> <li>Pleura</li> <li>Nasal Cavity</li> <li>Traches</li> <li>Bronkiolus</li> <li>Bronkus</li> <li>Paru-Paru Kiri</li> <li>Diafragma</li> </ul>	

No	Keterangan	Pembahasan
		 <p>Diagram of the human respiratory system with labels:</p> <ul style="list-style-type: none"> <li>Rongga Hidung</li> <li>Rongga Mulut</li> <li>Laring</li> <li>Trakea</li> <li>Bronkiolus</li> <li>Faring</li> <li>Paru-Paru</li> <li>Bronkus</li> <li>Bronkiplus</li> <li>Alveolus</li> </ul>
		 <p>Detailed diagram of the lungs with labels:</p> <ul style="list-style-type: none"> <li>Superior lobe</li> <li>Middle lobe</li> <li>Inferior Lobe</li> <li>Trachea</li> <li>Superior Lobe</li> <li>Main (primary) bronchus</li> <li>Lobar (secondary) bronchus</li> <li>Segmental (tertiary) bronchus</li> <li>Cardiac notch</li> <li>Inferior Lobe</li> </ul>

