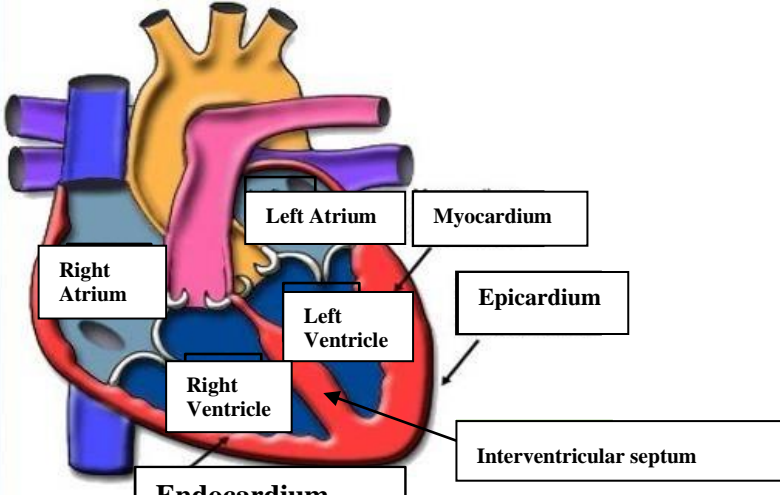
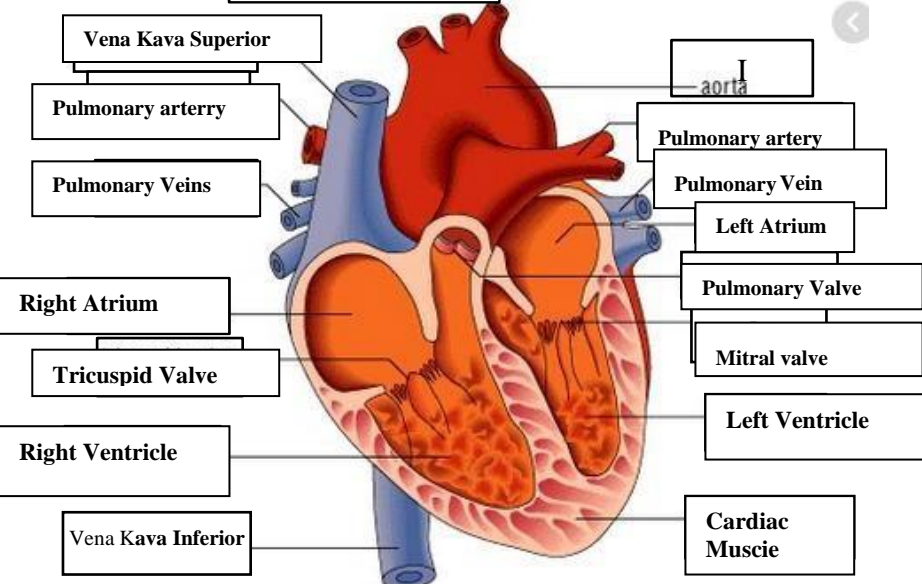
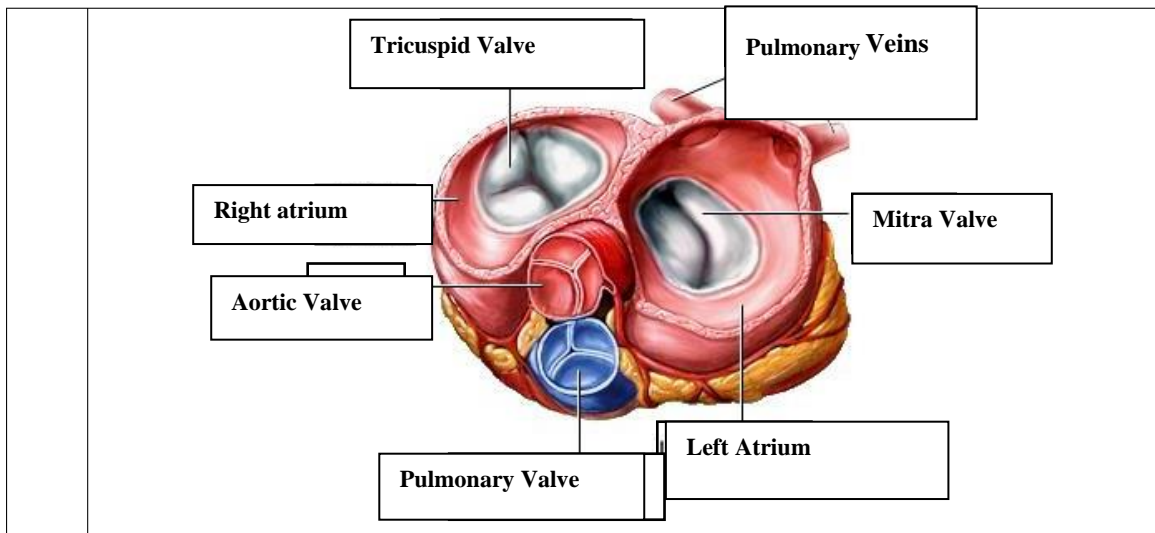


WORKSHEETS (LEMBAR KERJA)

Mata Kuliah	: Anatomi
Materi	: Anatomi Cardiovaskuler
NIM>Nama Mahasiswa	: Rahmi Maisarah

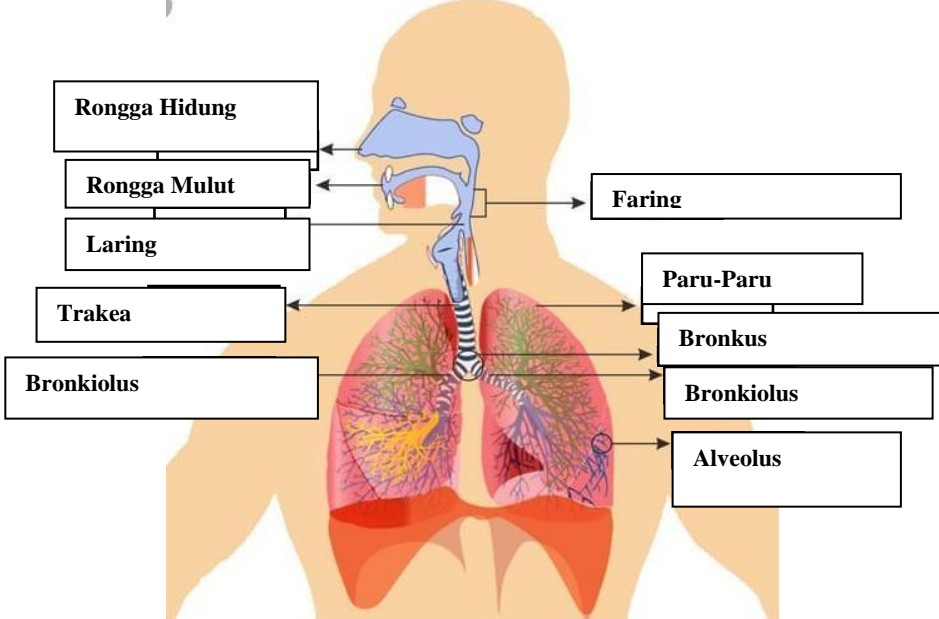
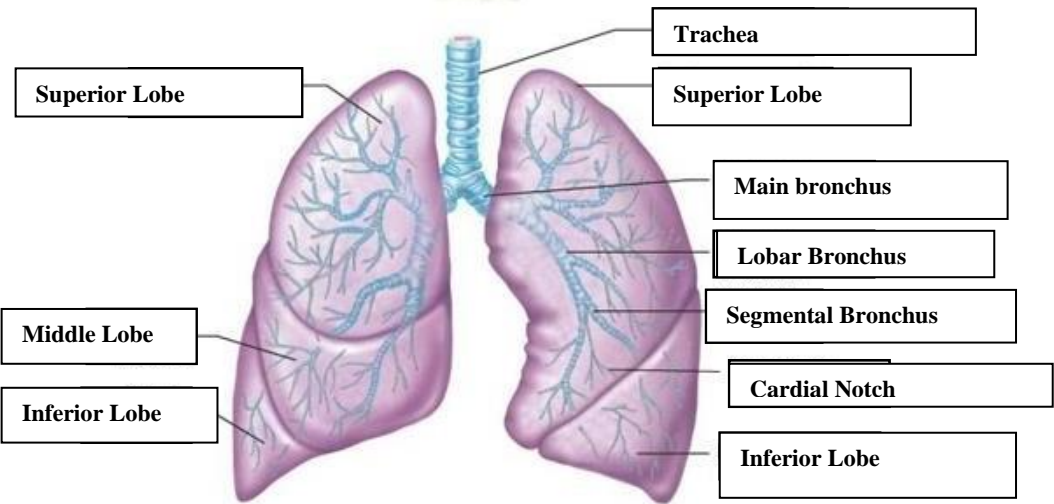
No	Keterangan	Pembahasan
1		 <p>Labels in diagram: Right Atrium, Left Atrium, Myocardium, Epicardium, Left Ventricle, Right Ventricle, Interventricular septum, Endocardium.</p>
		 <p>Labels in diagram: Vena Kava Superior, Pulmonary artery, Pulmonary Veins, Right Atrium, Tricuspid Valve, Right Ventricle, Vena Kava Inferior, aorta, Pulmonary artery, Pulmonary Vein, Left Atrium, Pulmonary Valve, Mitral valve, Left Ventricle, Cardiac Muscie.</p>



WORKSHEETS (LEMBAR KERJA)

Mata Kuliah	: Anatomi
Materi	: Anatomi Respirasi
NIM>Nama Mahasiswa	: Rahmi Maisarah

No	Keterangan	Pembahasan
1	<p>An anatomical diagram of the human respiratory system. It shows the nasal cavity (Rongga Hidung), pharynx (Faring), larynx (Laring), trachea (Trakea), bronchi (Bronkus), bronchioles (Bronkiolus), and lungs (Paru-Paru kanan and Paru-Paru kiri). The pleura and diaphragm (Diafragma) are also labeled. Labels with leader lines point to each of these structures.</p>	

No	Keterangan	Pembahasan
		 <p>Diagram of the human respiratory system with labels:</p> <ul style="list-style-type: none"> Rongga Hidung Rongga Mulut Laring Trakea Bronkiolus Faring Paru-Paru Bronkus Bronkiolus Alveolus
		 <p>Detailed diagram of the lungs with labels:</p> <ul style="list-style-type: none"> Superior Lobe Middle Lobe Inferior Lobe Trachea Superior Lobe Main bronchus Lobar Bronchus Segmental Bronchus Cardial Notch Inferior Lobe

