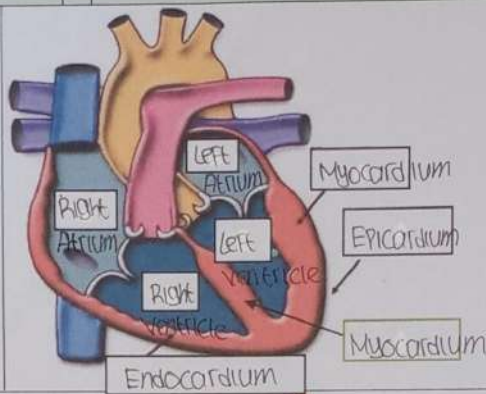
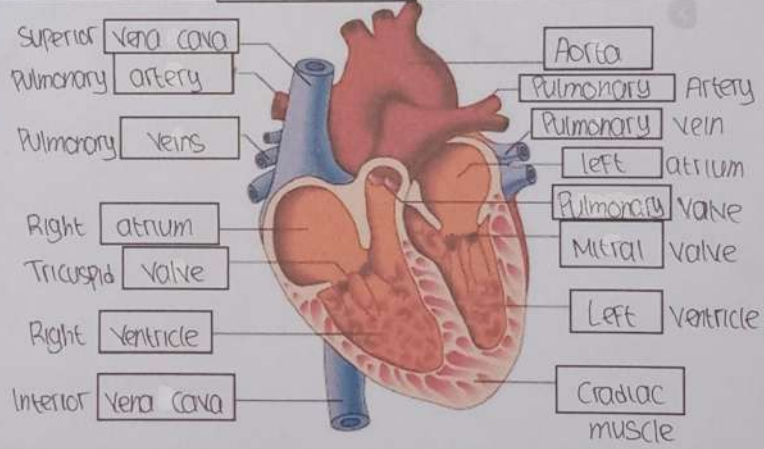
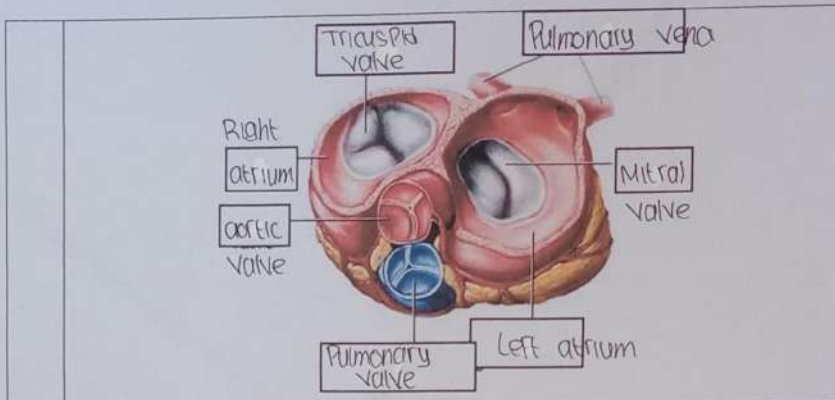


**WORKSHEETS (LEMBAR KERJA)**

Mata Kuliah	: Anatomi
Materi	: Anatomi Cardiovaskuler
NIM>Nama Mahasiswa	: Nindra Arlindawati / 211010197

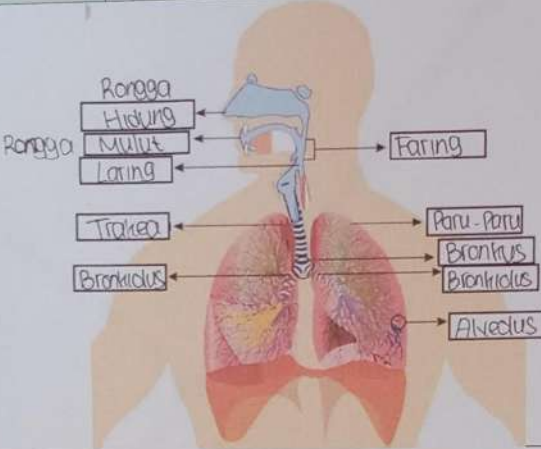
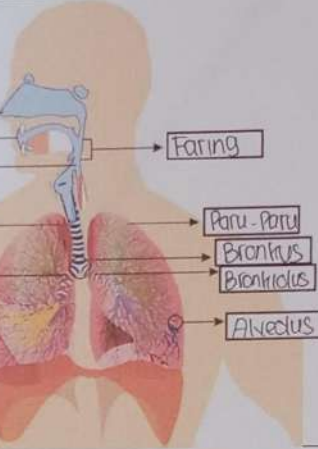
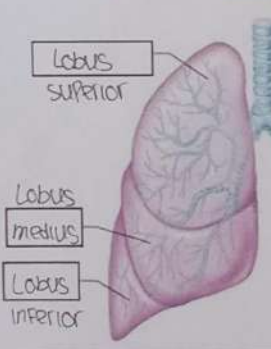
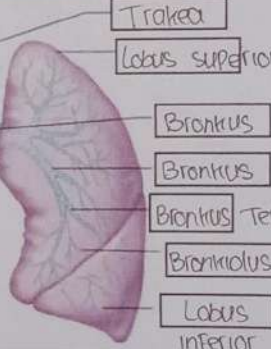
No	Keterangan	Pembahasan
1		
		



**WORKSHEETS (LEMBAR KERJA)**

Mata Kuliah	: Anatomi
Materi	: Anatomi Respirasi
NIM>Nama Mahasiswa	: Nindra Arlindawati / 2110101097

No	Keterangan	Pembahasan
1	<p>An anatomical diagram of the human respiratory system. Labels on the left side include Faring, Laring, Bronkus, Paru-paru kanan, Pleura, and Diafragma. Labels on the right side include Rongga Hidung, Trakea, Bronkiolus, Bronkus, and Paru-paru kiri.</p>	

No	Keterangan	Pembahasan
	 <p>Rongga Hidung Rongga Mulut Laring Trakea Bronkiolus</p>	 <p>Faring Paru-paru Bronkiolus Alveolus</p>
	 <p>Lobus superior Lobus medius Lobus inferior</p>	 <p>Trakea Lobus superior Bronkiolus Bronkiolus sekunder Bronkiolus Tersier Bronkiolus Lobus inferior</p>