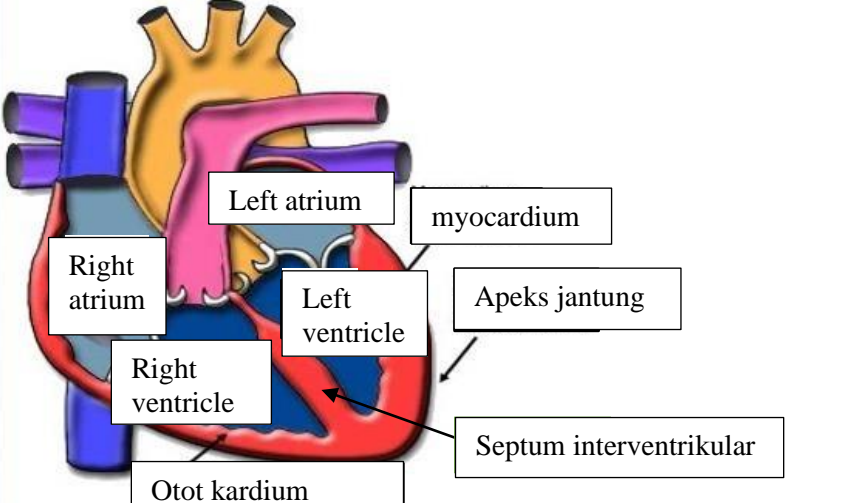
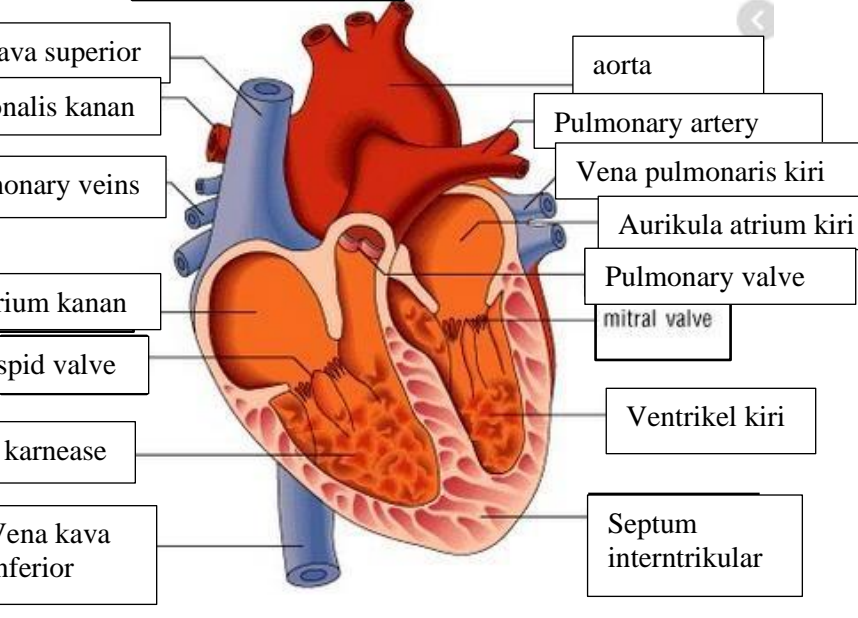
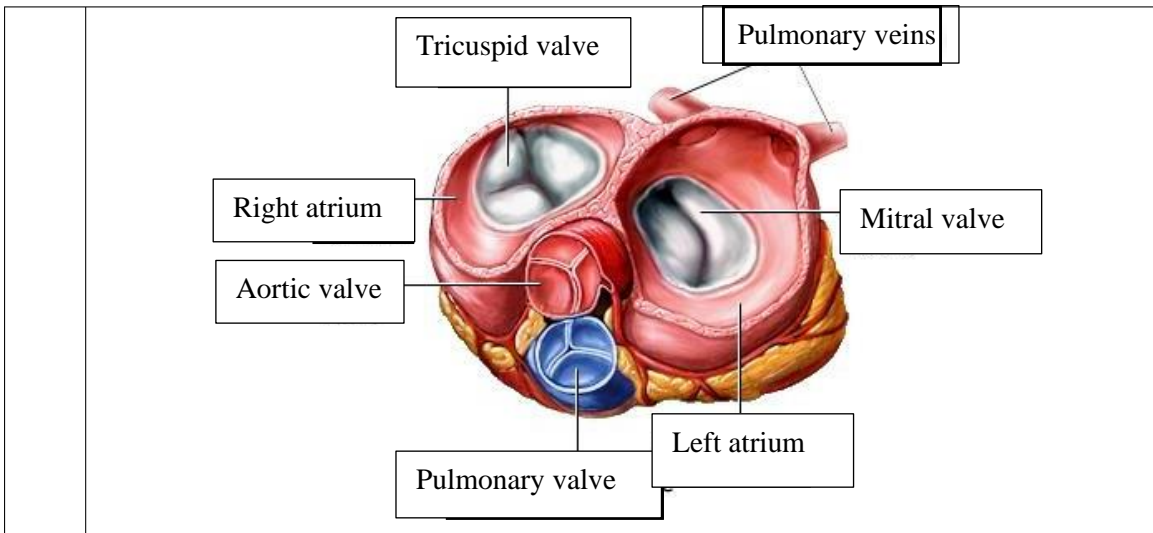


WORKSHEETS (LEMBAR KERJA)

Mata Kuliah	: Anatomi
Materi	: Anatomi Cardiovaskuler
NIM>Nama Mahasiswa	: 2110101104/Lyla aleyda lasawedi

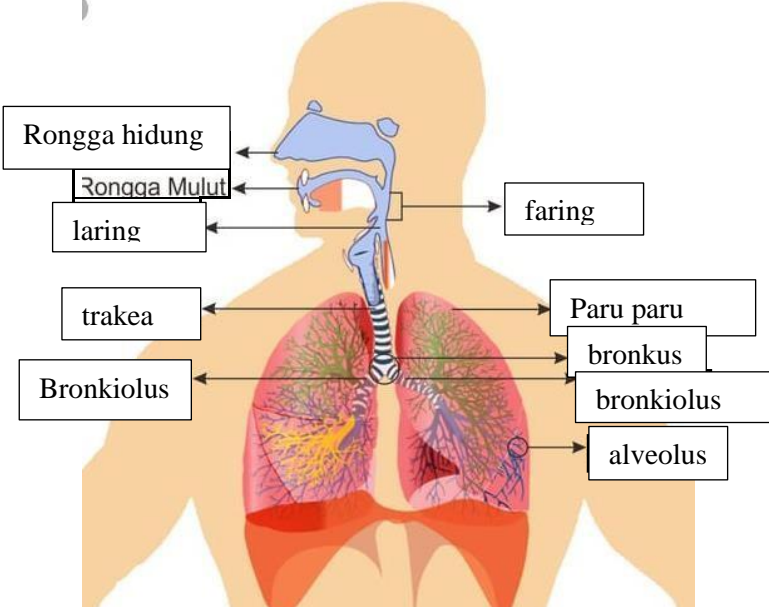
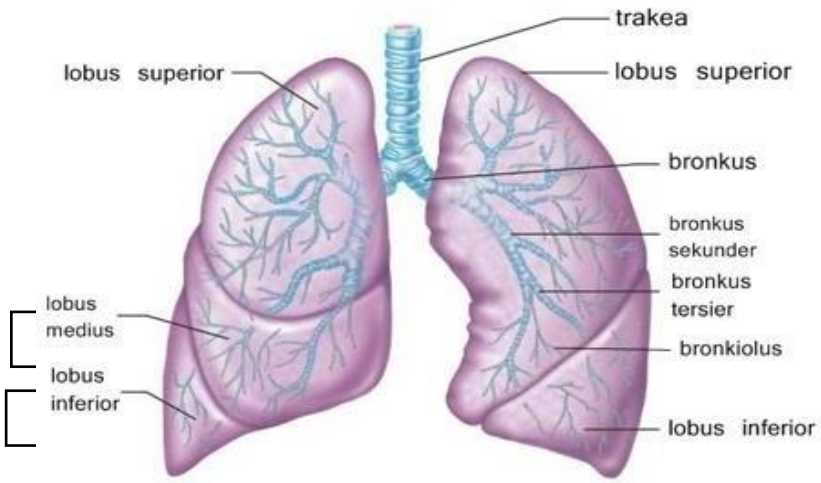
No	Keterangan	Pembahasan
1		
		



WORKSHEETS (LEMBAR KERJA)

Mata Kuliah	: Anatomi
Materi	: Anatomi Respirasi
NIM>Nama Mahasiswa	: 2110101104/Lyla aleyda lasawedi

No	Keterangan	Pembahasan
1	<p>An anatomical diagram of the human respiratory system. It shows the nasal cavity (Rongga hidung), pharynx (faring), larynx with epiglottis (epiglotis), trachea (trakea), bronchi (Bronkus kanan and Bronkus kiri), bronchioles (bronkiolus and bronkiole), alveoli (alveolus), pleura, and the abdominal cavity (Rongga perut). Labels with leader lines identify each part.</p>	

No	Keterangan	Pembahasan
		 <p>Diagram of the human respiratory system with labels: Rongga hidung, Rongga Mulut, laring, trakea, Bronkiolus, faring, Paru paru, bronkus, bronkiolus, and alveolus.</p>
		 <p>Detailed diagram of the lungs with labels: trakea, lobus superior, lobus superior, bronkus, bronkus sekunder, bronkus tersier, bronkiolus, lobus inferior, lobus inferior, lobus medius, and lobus inferior.</p>

