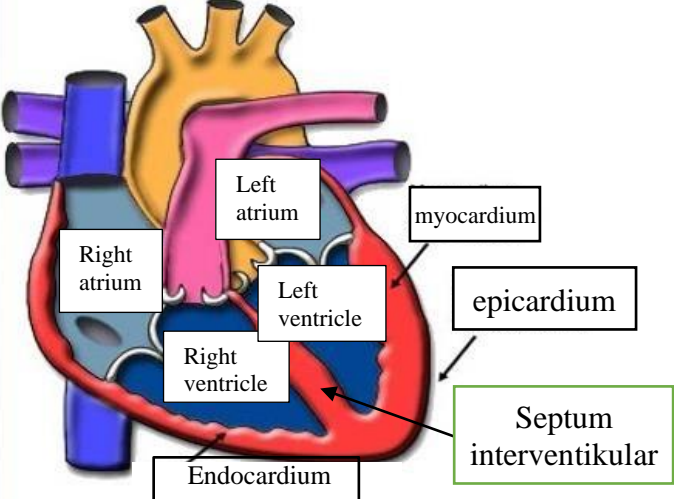
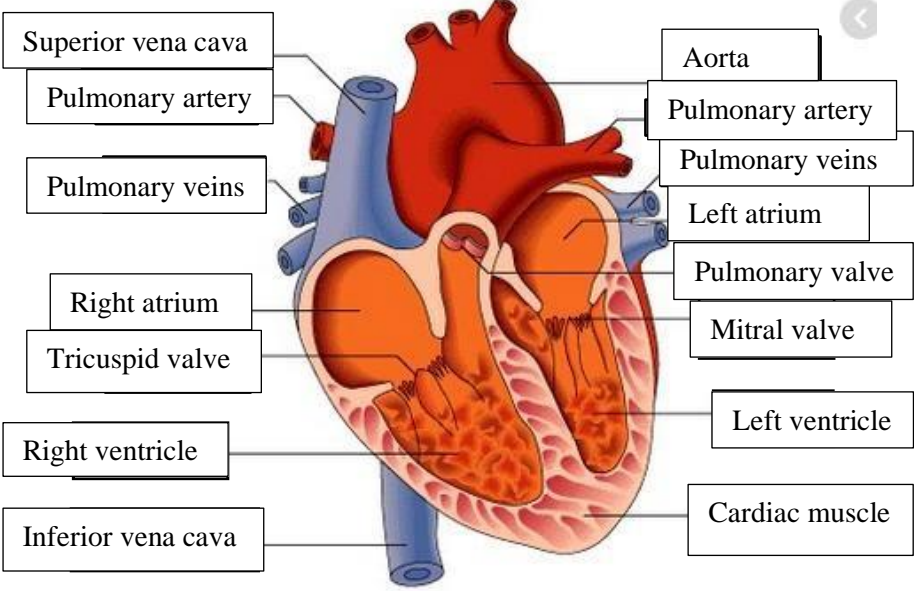
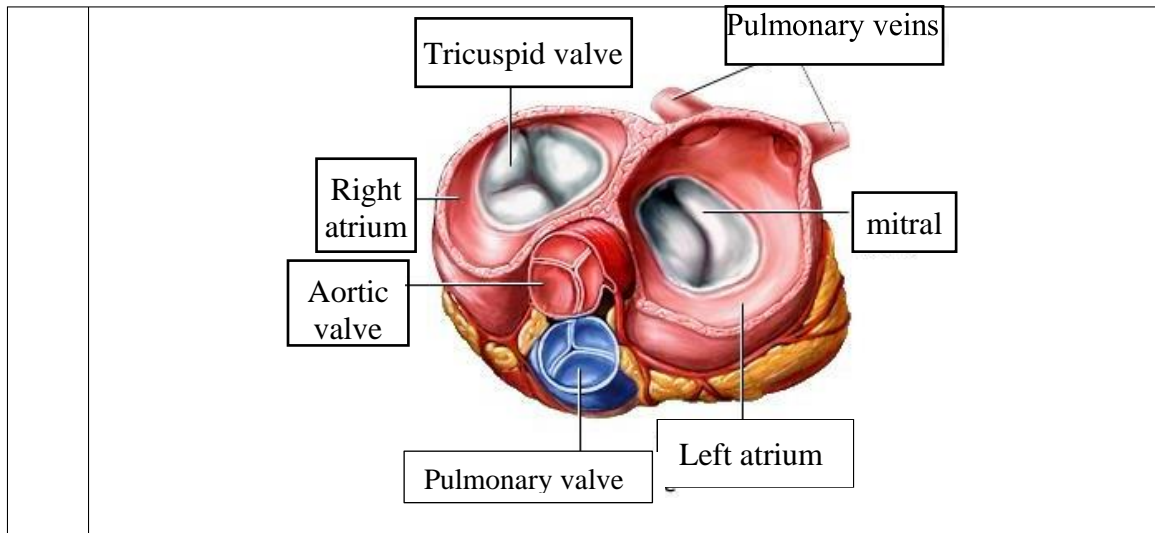


**WORKSHEETS (LEMBAR KERJA)**

<b>Mata Kuliah</b>	: <b>Anatomi</b>
<b>Materi</b>	: <b>Anatomi Cardiovaskuler</b>
<b>NIM&gt;Nama Mahasiswa</b>	: <b>2110101088/Shalihati Al Izzati</b>

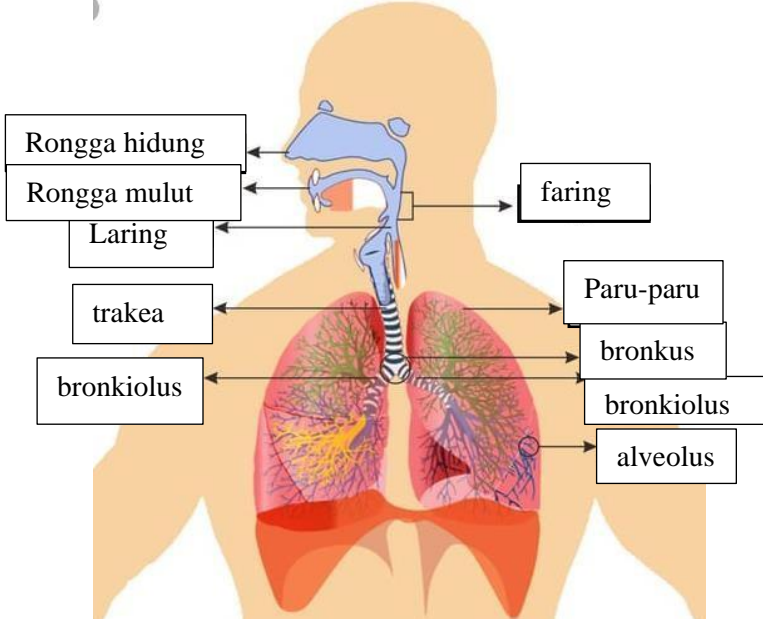
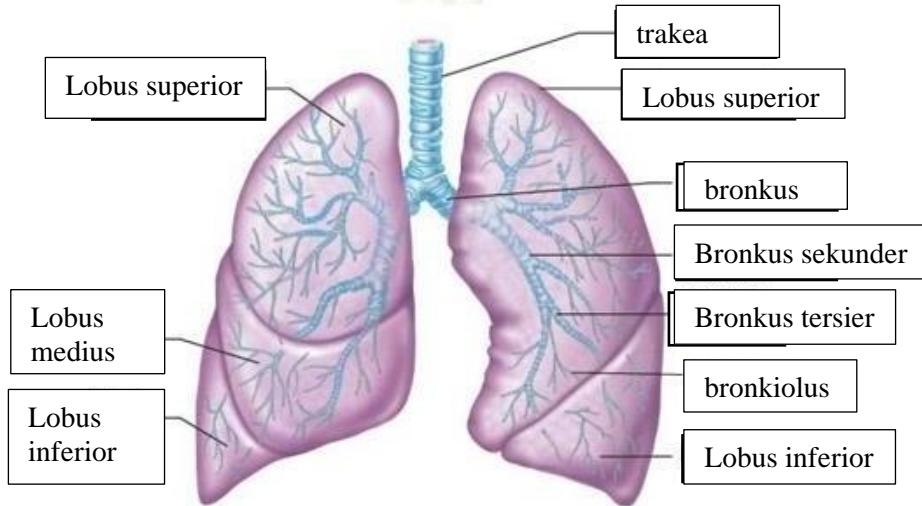
No	Keterangan	Pembahasan
1		
		



**WORKSHEETS (LEMBAR KERJA)**

<b>Mata Kuliah</b>	: Anatomi
<b>Materi</b>	: Anatomi Respirasi
<b>NIM&gt;Nama Mahasiswa</b>	: 2110101088/Shalihati Al Izzati

No	Keterangan	Pembahasan
1		<p>An anatomical diagram of the human respiratory system. Labels include: faring (pharynx), laring (larynx), bronkus (bronchus), Paru-paru kanan (right lung), pleura, diafragma (diaphragm), Rongga hidung (nasal cavity), trakea (trachea), bronkiolus (bronchioles), bronkus (bronchus), Paru-paru kiri (left lung).</p>

No	Keterangan	Pembahasan
		 <p>Diagram of the human respiratory system with labels: Rongga hidung, Rongga mulut, Laring, trakea, bronkiolus, faring, Paru-paru, bronkus, bronkiolus, and alveolus.</p>
		 <p>Detailed diagram of the lungs with labels: Lobus superior, Lobus medius, Lobus inferior, trakea, Lobus superior, bronkus, Bronkus sekunder, Bronkus tersier, bronkiolus, and Lobus inferior.</p>

