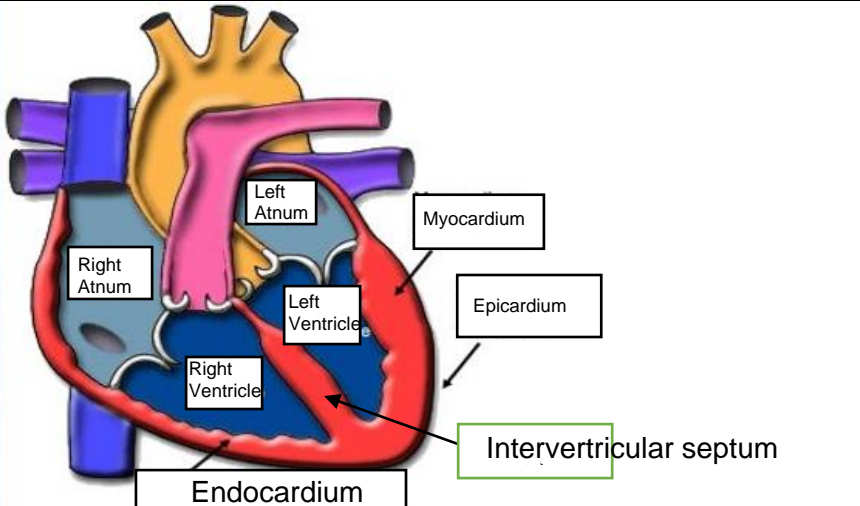
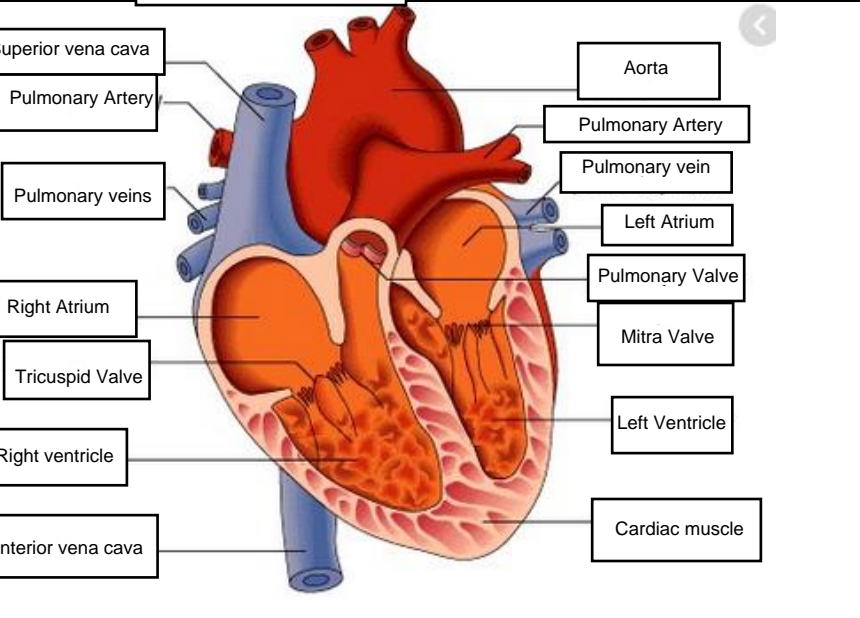
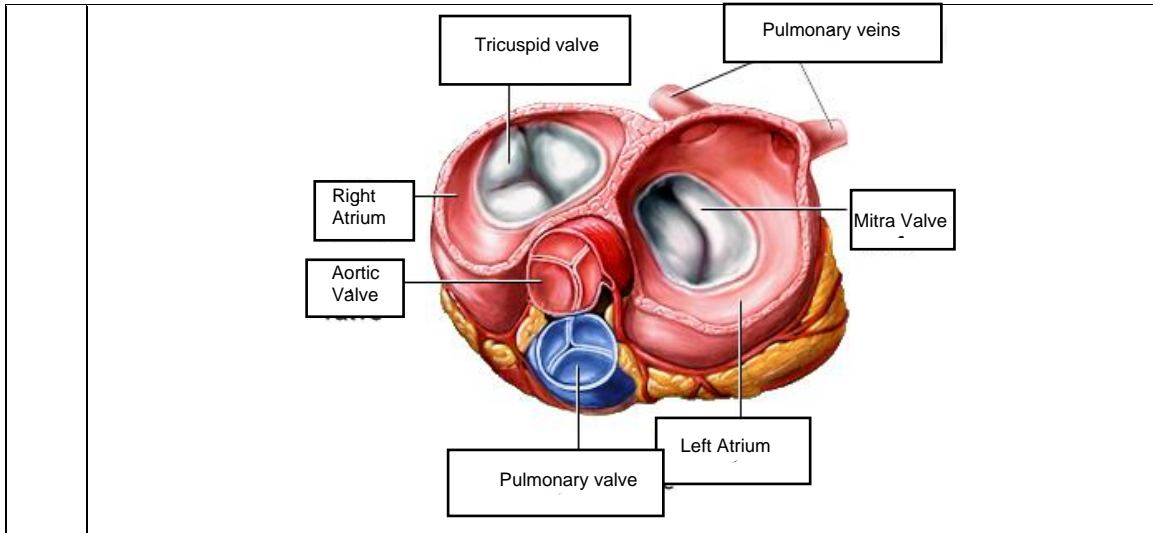


WORKSHEETS (LEMBAR KERJA)

Mata Kuliah	: Anatomi
Materi	: Anatomi Cardiovaskuler
NIM>Nama Mahasiswa	: 2110101092/Dinanda Dwi Setyorini

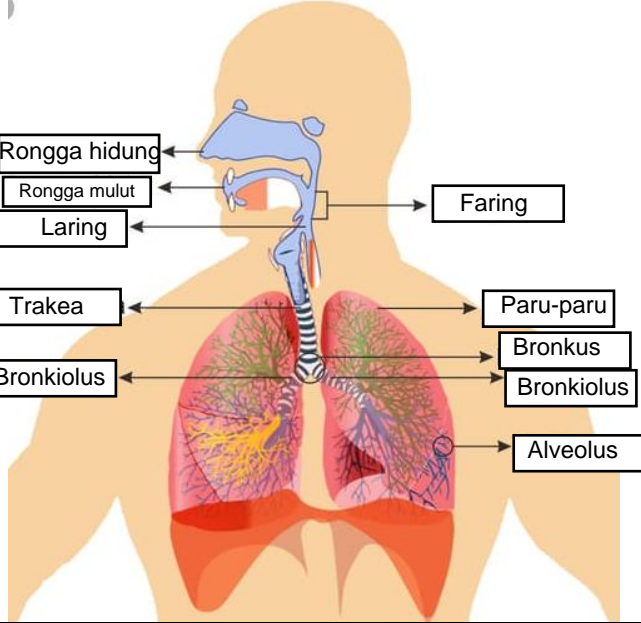
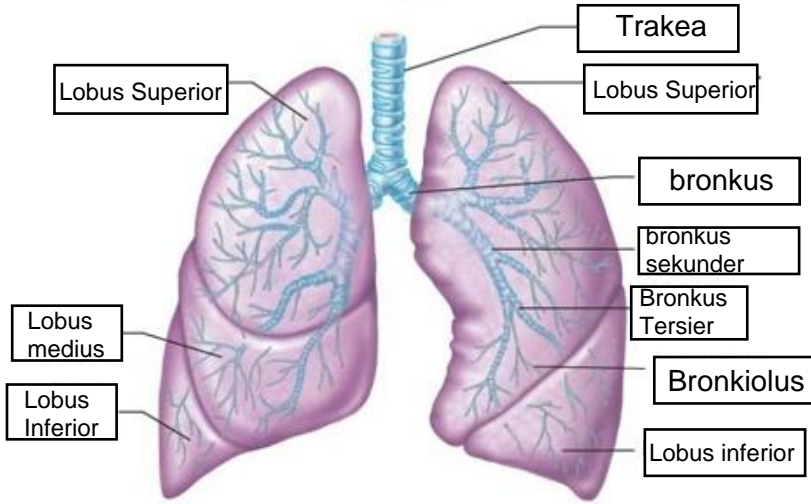
No	Keterangan	Pembahasan
1		
		



WORKSHEETS (LEMBAR KERJA)

Mata Kuliah	: Anatomi
Materi	: Anatomi Respirasi
NIM>Nama Mahasiswa	: 2110101092/Dinanda Dwi Setyorini

No	Keterangan	Pembahasan
1	<p>An anatomical diagram of the human respiratory system. Labels include: Faring, Laring, Bronkus, Paru-paru kanan, Pleura, Diafragma, Rongga hidung, Trakea, Bronkiolus, Bronkus, and Paru-paru Kiri.</p>	

No	Keterangan	Pembahasan
		 <p>Diagram of the human respiratory system with labels: Rongga hidung, Rongga mulut, Laring, Faring, Trakea, Paru-paru, Bronkus, Bronkiolus, Alveolus.</p>
		 <p>Detailed diagram of the lungs with labels: Lobus Superior, Lobus medius, Lobus Inferior, Trakea, Lobus Superior, bronkus, bronkus sekunder, Bronkus Tersier, Bronkiolus, Lobus inferior.</p>

