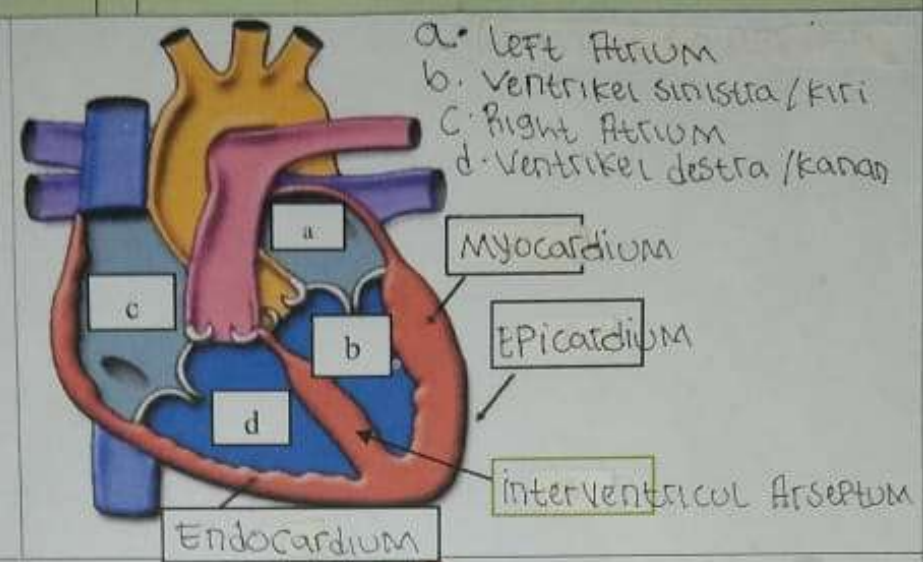
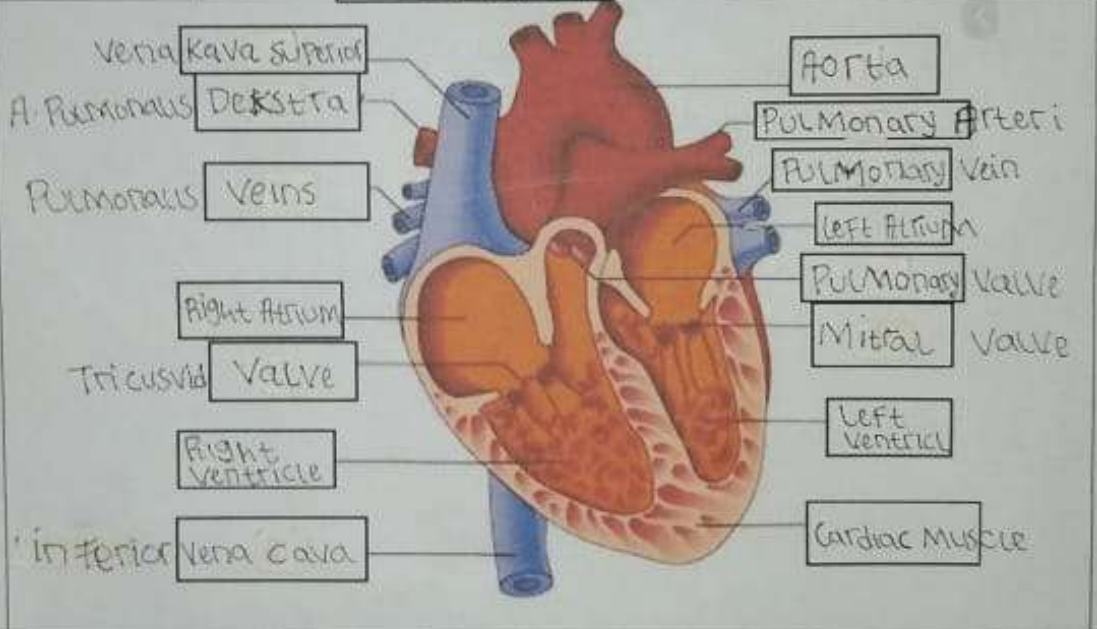
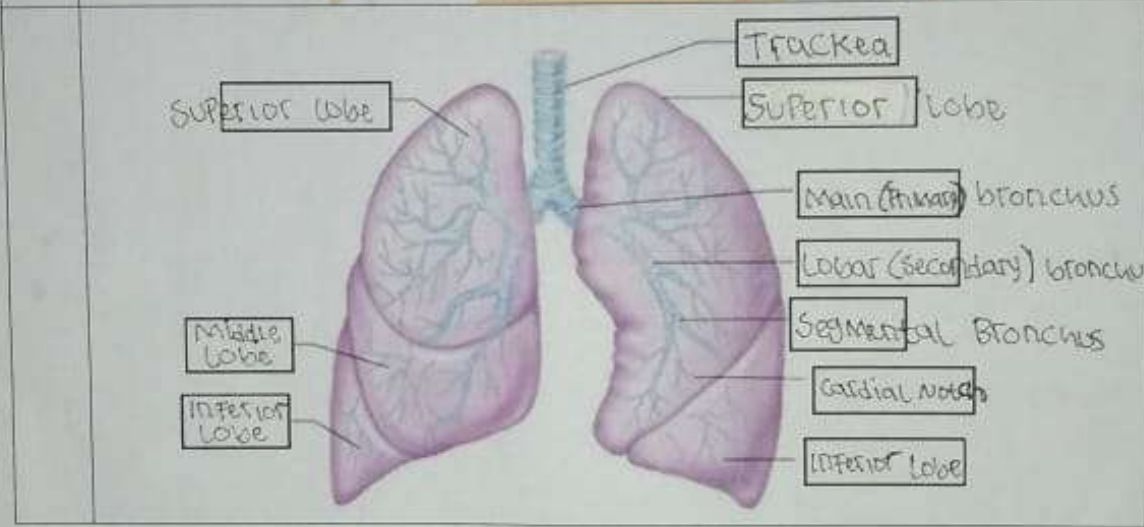
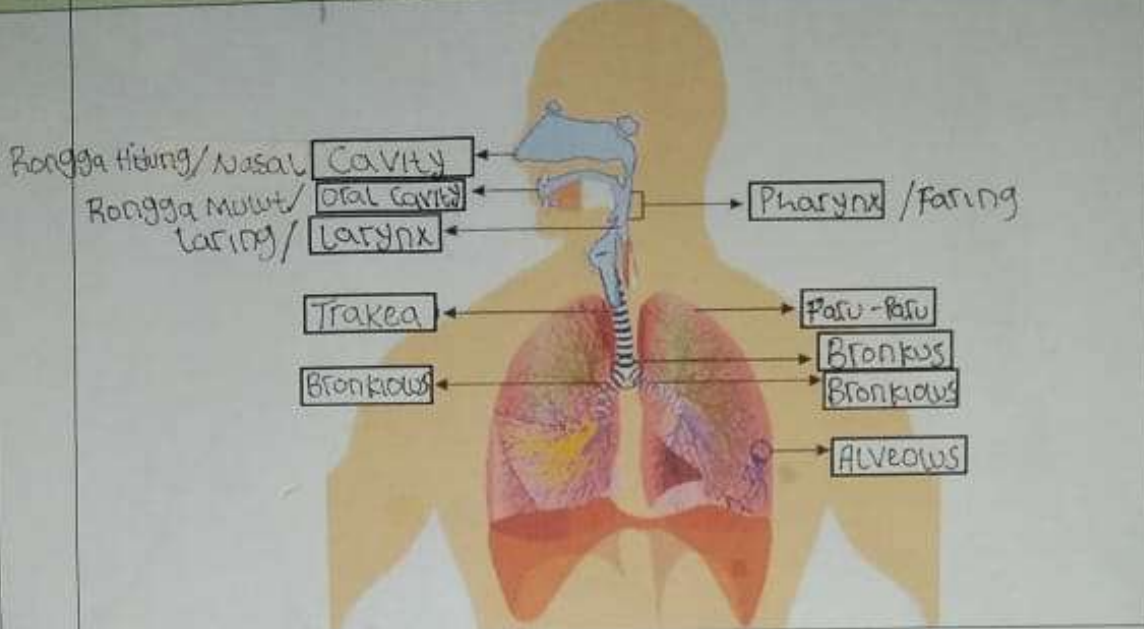


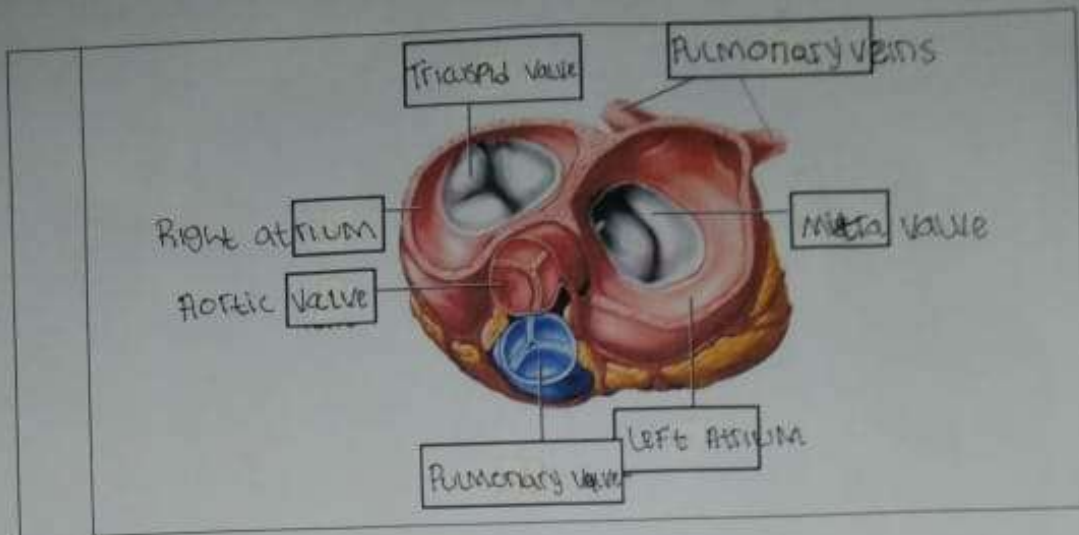
**WORKSHEETS (LEMBAR KERJA)**

Mata Kuliah	: Anatomi
Materi	: Anatomi Kardiovaskuler
NIM>Nama Mahasiswa	: 2110101131 / SRI REDEKI

No	Keterangan	Pembahasan
1		 <p>                     a. Left Atrium                      b. Ventrikel sinistra / kiri                      c. Right Atrium                      d. Ventrikel dextra / kanan                 </p> <p>                     Myocardium                      Epicardium                      Interventricular Septum                      Endocardium                 </p>
		 <p>                     Vena Kava Superior                      A. Pulmonalis DEXTRA                      Pulmonalis Veins                      Right Atrium                      Tricuspid Valve                      Right Ventricle                      Inferior Vena Cava                 </p> <p>                     Aorta                      Pulmonary Arteri                      Pulmonary Vein                      Left Atrium                      Pulmonary Valve                      Mitral Valve                      Left Ventricle                      Cardiac Muscle                 </p>

No	Keterangan	Pembahasan
----	------------	------------





**WORKSHEETS (LEMBAR KERJA)**

Mata Kuliah	: Anatomi
Materi	: Anatomi Respirasi
NIM>Nama Mahasiswa	: 2110101131 / SRI REDEKI

No	Keterangan	Pembahasan
1	<p>Handwritten labels for the respiratory system diagram:</p> <ul style="list-style-type: none"> <li>Pharynx</li> <li>Esophagus</li> <li>Bronchus</li> <li>Paro-paro Kanan</li> <li>Pleura</li> <li>Nasal Cavity</li> <li>Trachea</li> <li>Bronkiolus</li> <li>Bronkus</li> <li>Paro-paro Kiri</li> </ul>	

Diaphragma