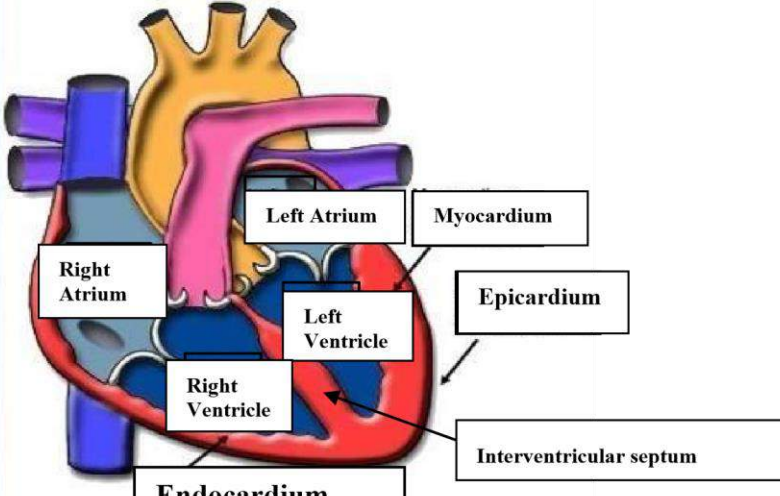
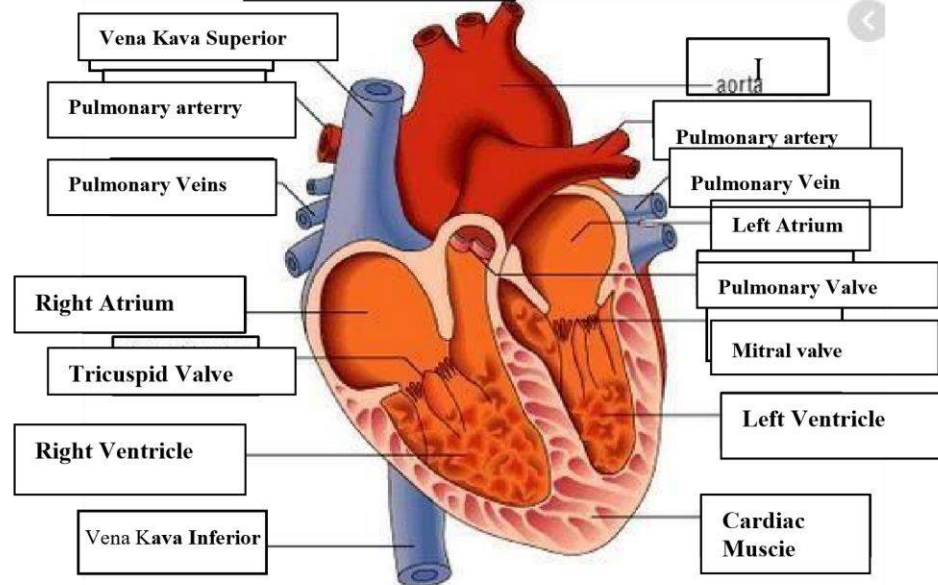
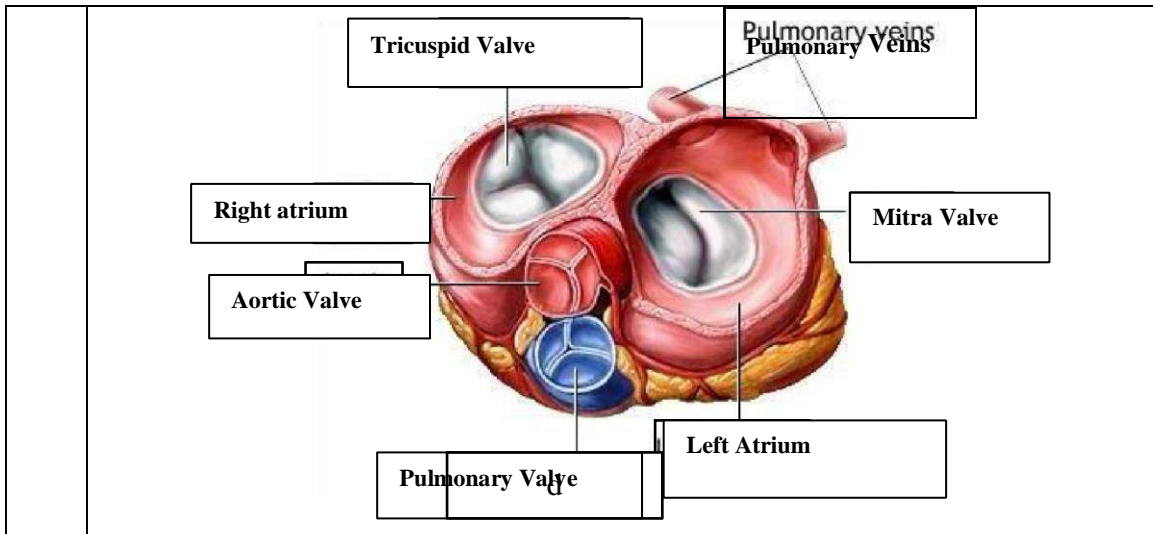


**WORKSHEETS (LEMBAR KERJA)**

<b>Mata Kuliah</b>	: Anatomi
<b>Materi</b>	: Anatomi Cardiovaskuler
<b>NIM&gt;Nama Mahasiswa</b>	: 2110101135/Ani khoeriyatul mardiyah

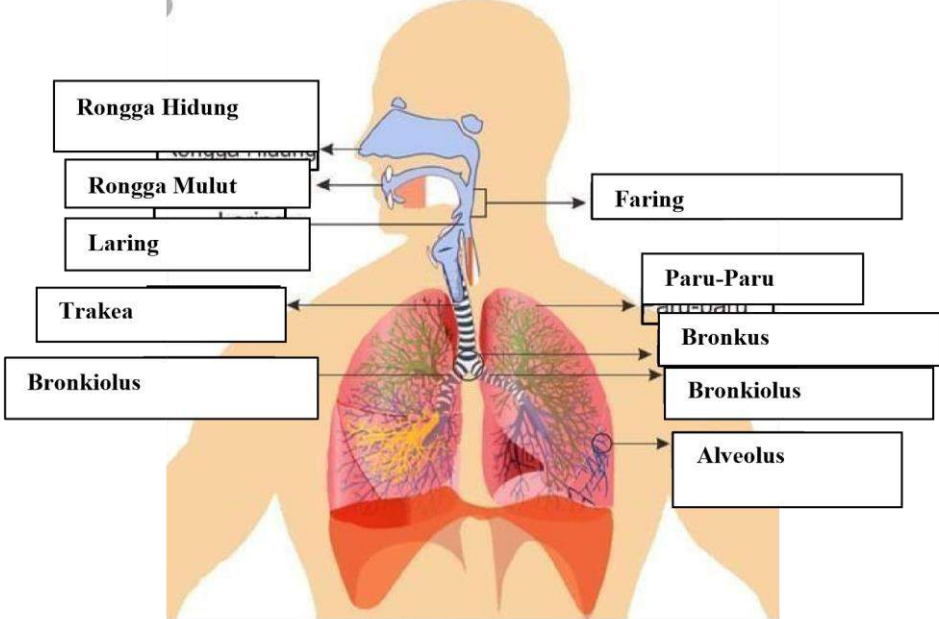
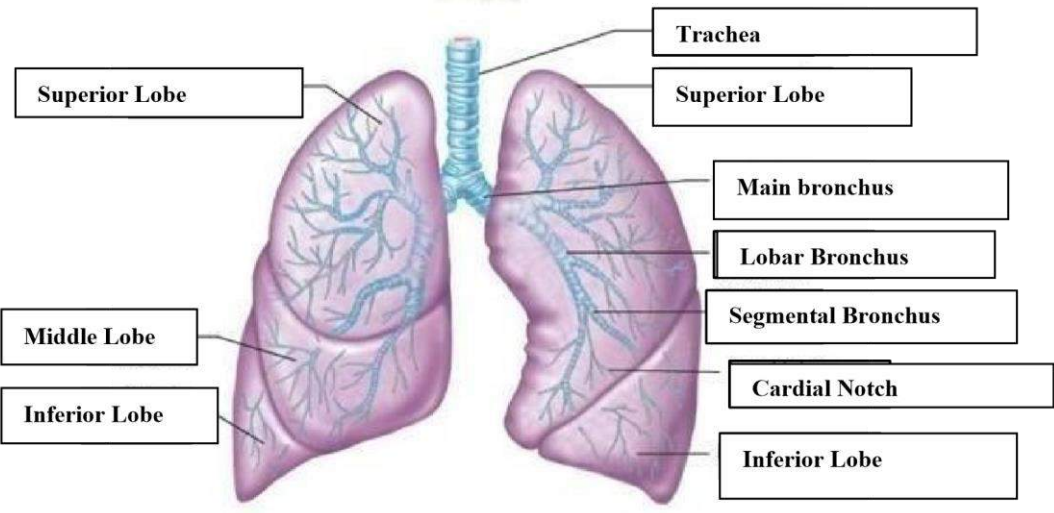
No	Keterangan	Pembahasan
1		
		



**WORKSHEETS (LEMBAR KERJA)**

<b>Mata Kuliah</b>	<b>: Anatomi</b>
<b>Materi</b>	<b>: Anatomi Respirasi</b>
<b>NIM&gt;Nama Mahasiswa</b>	<b>: 2110101135/Ani Khoeriyatul Mardiyah</b>

No	Keterangan	Pembahasan
1	<p>An anatomical diagram of the human respiratory system. Labels with leader lines point to the following parts: Faring, Laring, Bronkus, Paru Paru kanan, Pleura, Diafragma, Rongga Hidung, Trakea, Bronkiolus, Bronkus, and Paru-Paru kiri.</p>	

No	Keterangan	Pembahasan
		 <p>Diagram of the human respiratory system with labels:</p> <ul style="list-style-type: none"> <li>Rongga Hidung</li> <li>Rongga Mulut</li> <li>Laring</li> <li>Trakea</li> <li>Bronkiolus</li> <li>Faring</li> <li>Paru-Paru</li> <li>Bronkus</li> <li>Bronkiolus</li> <li>Alveolus</li> </ul>
		 <p>Detailed diagram of the lungs with labels:</p> <ul style="list-style-type: none"> <li>Superior Lobe</li> <li>Middle Lobe</li> <li>Inferior Lobe</li> <li>Trachea</li> <li>Superior Lobe</li> <li>Main bronchus</li> <li>Lobar Bronchus</li> <li>Segmental Bronchus</li> <li>Cardial Notch</li> <li>Inferior Lobe</li> </ul>