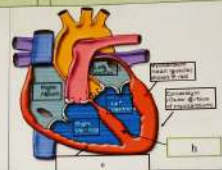
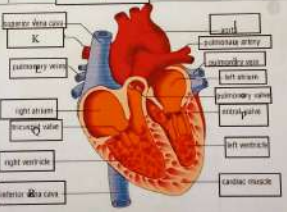
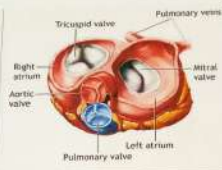


**WORKSHEETS (LEMBAR KERJA)**

Mata Kuliah : Anatomi  
 Materi : Anatomi Cardiovaskuler  
 NIM>Nama Mahasiswa : 210101126 / Debi Aggr. Soglin

No	Keterangan	Pembahasan
1		<div style="border: 1px solid black; padding: 2px; width: fit-content; margin-bottom: 5px;">h</div>  <div style="display: flex; justify-content: space-around; margin-top: 5px;"> <div style="border: 1px solid black; padding: 2px; width: 20%;">k</div> <div style="border: 1px solid black; padding: 2px; width: 20%;">d</div> <div style="border: 1px solid black; padding: 2px; width: 20%;">f</div> </div>

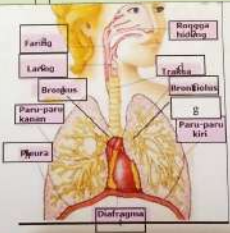
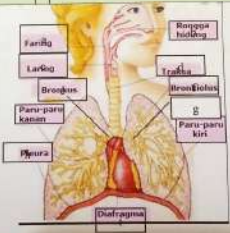


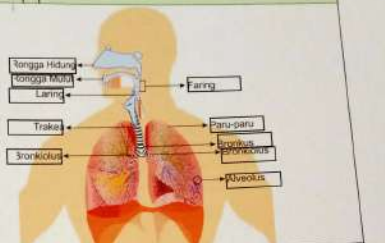
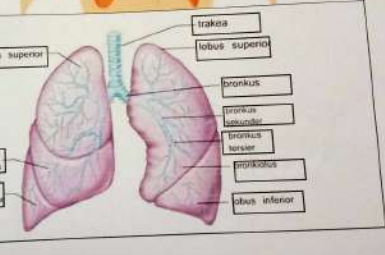
h

c

**WORKSHEETS (LEMBAR KERJA)**

Mata Kuliah : Anatomi  
 Materi : Anatomi Respirasi  
 NIM>Nama Mahasiswa : 210101126 / Debi Aggr. Soglin

No	Keterangan	Pembahasan
1		<div style="border: 1px solid black; padding: 2px; width: fit-content; margin-bottom: 5px;">h</div> 

No	Keterangan	Pembahasan
		 <p>Labels in diagram: Tongga Hidung, Tongga Mulut, Laring, Faring, Trakea, Bronchus, Bronkiolus, Alveolus, Papan-gatu.</p>
		 <p>Labels in diagram: lobus superior, lobus inferior, lobus medialis, lobus superior, lobus inferior, trakea, bronkus, bronkus superior, bronkus inferior, bronkiolus.</p>