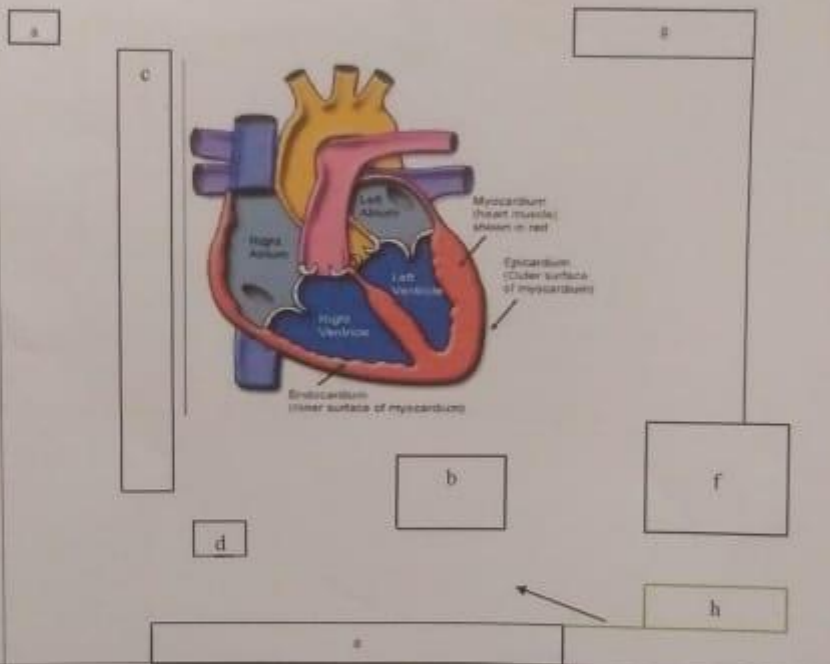
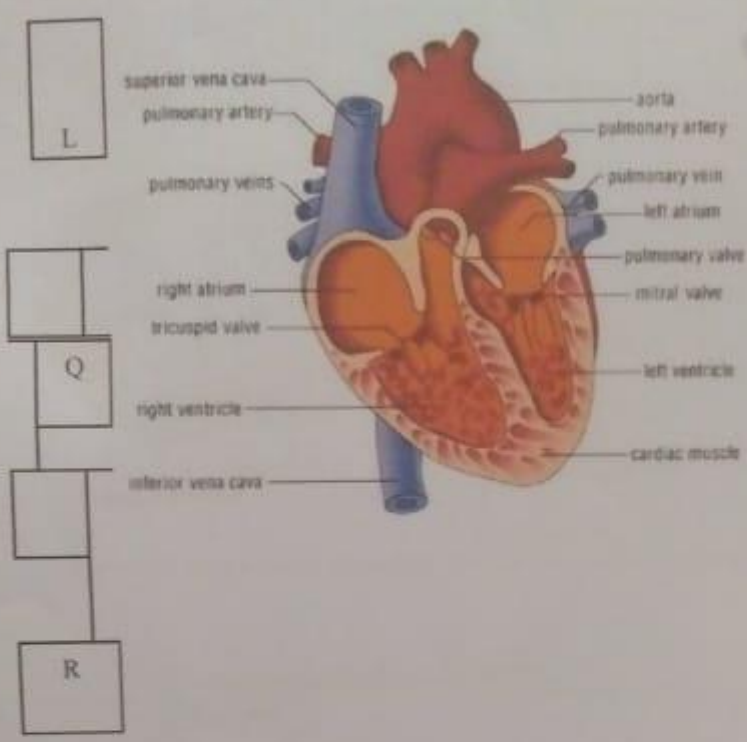


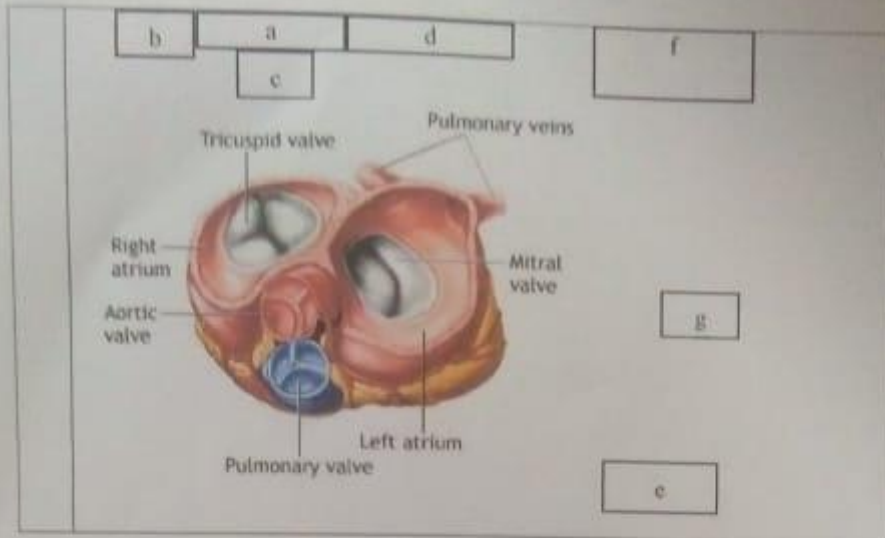
Mata Kuliah : Anatomi  
 Materi : Anatomi Sistem  
 NIM/ NAMA : 2110101075 / IIS wahyuningrasih

No	Keterangan	Pembahasan
1	 <p>The diagram shows a cross-section of the heart wall with the following labels:</p> <ul style="list-style-type: none"> <li><b>a</b>: Right Atrium</li> <li><b>b</b>: Left Atrium</li> <li><b>c</b>: Right Ventricle</li> <li><b>d</b>: Left Ventricle</li> <li><b>e</b>: Myocardium (heart muscle) shown in red</li> <li><b>f</b>: Epicardium (outer surface of myocardium)</li> <li><b>g</b>: Endocardium (inner surface of myocardium)</li> <li><b>h</b>: Coronary Artery</li> <li><b>i</b>: Coronary Vein</li> <li><b>j</b>: Pericardium</li> <li><b>k</b>: Myocardium</li> </ul>	



**WORKSHEETS (LEMBAR KERJA)**

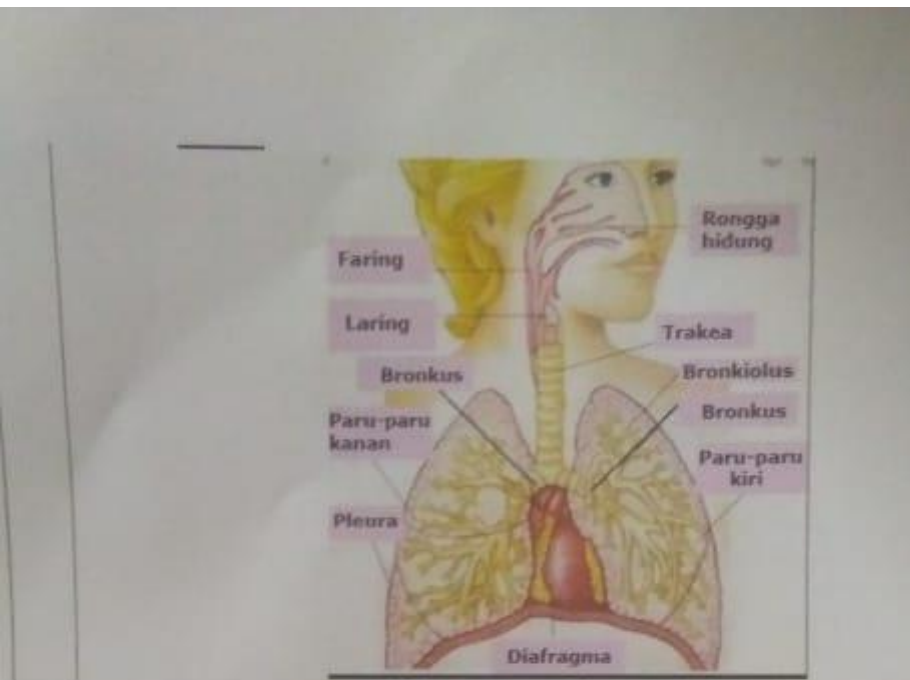
Kuliah : Anatomi  
 ri : Anatomi Cardiovasuler  
 /Nama Mahasiswa : 2110101075 / IIS Wahyuning Sih



**WORKSHEETS (LEMBAR KERJA)**

Mata Kuliah : Anatomi  
 Materi : Anatomi Respirasi  
 NIM>Nama Mahasiswa :

No	Keterangan	Pembahasan
1	<p>A crossword puzzle grid with the following letters placed:</p> <ul style="list-style-type: none"> <li>Vertical: a, c, e, h</li> <li>Horizontal: b, d, f, g, i</li> </ul>	



**Keterangan** **Pembahasan**

