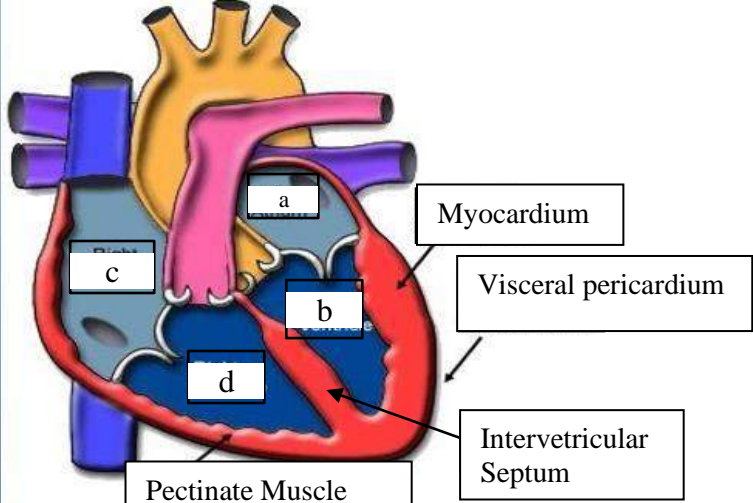
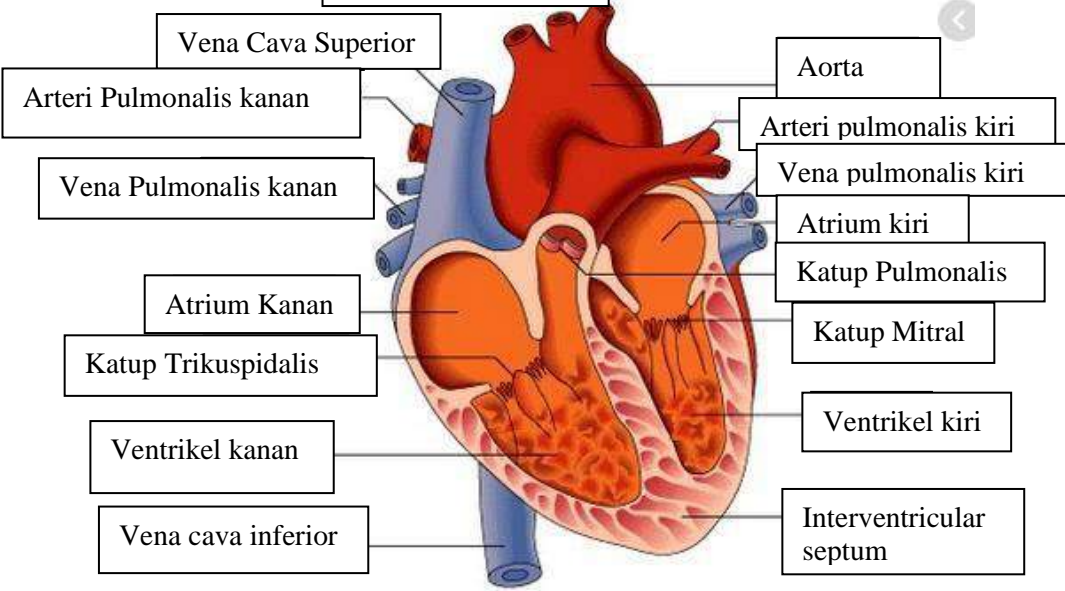
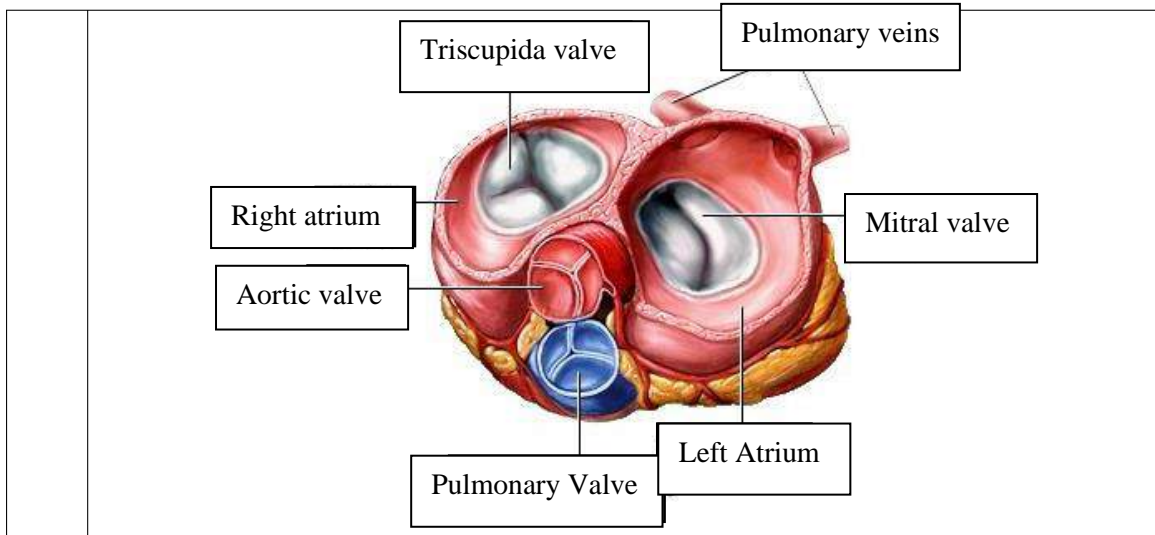


WORKSHEETS (LEMBAR KERJA)

Mata Kuliah	: Anatomi
Materi	: Anatomi Cardiovaskuler
NIM>Nama Mahasiswa	: 2110101134/Aisyah Mutiara Agustin

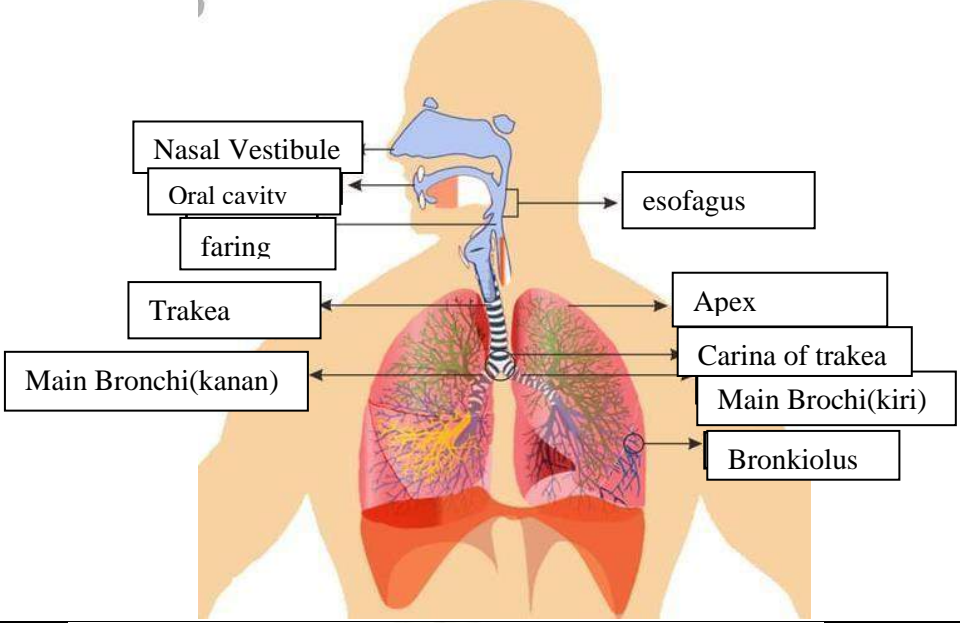
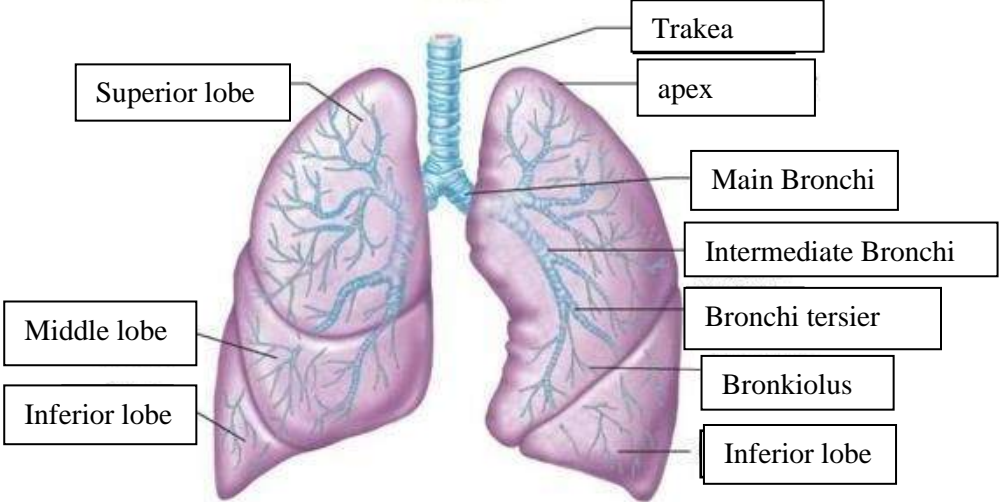
No	Keterangan	Pembahasan
1		
		



WORKSHEETS (LEMBAR KERJA)

Mata Kuliah	: Anatomi
Materi	: Anatomi Respirasi
NIM>Nama Mahasiswa	: 2110101134/Aisyah Mutiara Agustin

No	Keterangan	Pembahasan
1	<p>An anatomical diagram of the human respiratory system. Labels with leader lines point to: Faring, Laring, Bronkiolus, Paru paru kanan, Diafragma, Trakea, Bronkus, Alveolus, and a partially visible 'Rongga' (cavity) with a 'b' label. There is also a pink box with the letter 'e' near the larynx.</p>	

No	Keterangan	Pembahasan
		 <p>This diagram illustrates the human respiratory system. Labels on the left side include: Nasal Vestibule, Oral cavity, faring, Trakea, and Main Bronchi(kanan). Labels on the right side include: esofagus, Apex, Carina of trakea, Main Brochi(kiri), and Bronkiolus.</p>
		 <p>This diagram shows a detailed view of the lungs and the lower respiratory tract. Labels on the left side include: Superior lobe, Middle lobe, and Inferior lobe. Labels on the right side include: Trakea, apex, Main Bronchi, Intermediate Bronchi, Bronchi tersier, Bronkiolus, and Inferior lobe.</p>

