

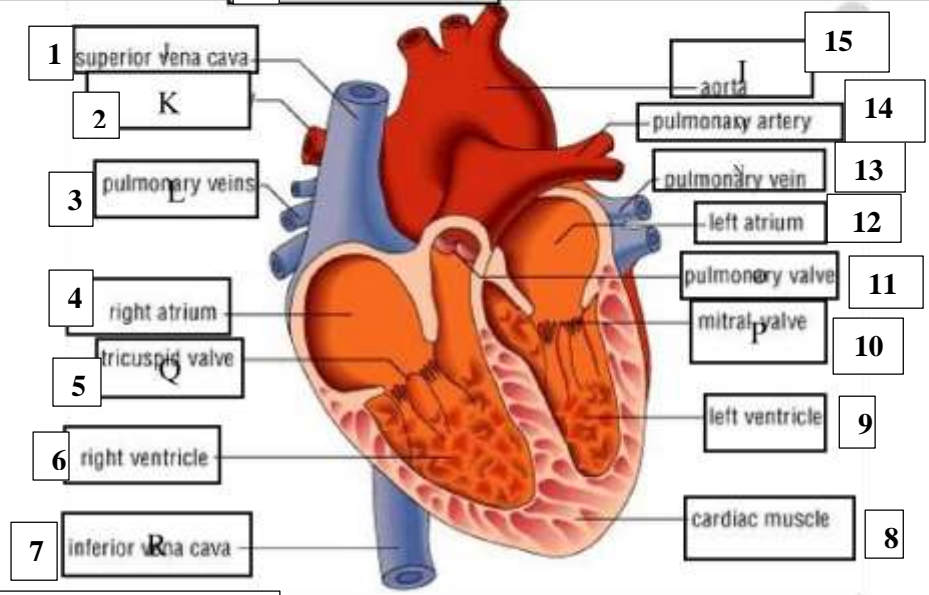
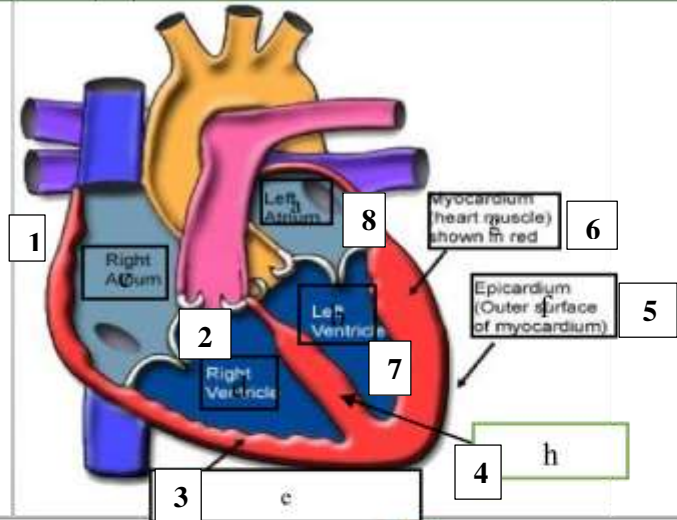
WORKSHEETS (LEMBAR KERJA)

Mata Kuliah : Anatomi
Materi : Anatomi Cardiovaskuler
NIM>Nama Mahasiswa : 2110101078/Sabilla Ratu Cetrin

No	Keterangan	Pembahasan
----	------------	------------

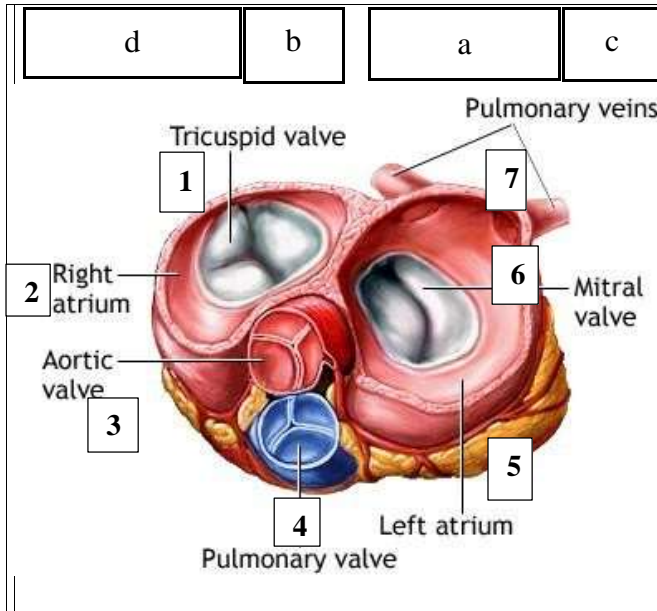
Keterangan Gambar:

1. Atrium kanan
2. Ventrikel kanan
3. Otot jantung
4. Septum interventrikular
5. Epicardium
6. Miokardium
7. Ventrikel kiri
8. Atrium kiri



Keterangan Gambar:

1. Vena kava superior
2. Arteri pilmonalis kanan
3. Vena pulmonalis
4. Atrium kanan
5. Katup triskupid
6. Ventrikel kanan
7. Vena kava interior
8. Otot jantung
9. Ventrikel kiri
10. Katup mitral
11. Katup pulmonalis
12. Atrium kiri
13. Vena pulmonalis
14. Arteri pulmonalis
15. aorta



Keterangan gambar:

1. Katup tricuspid
2. Atrium kanan
3. Katup aorta
4. Katup pulmonal
5. Atrium kiri
6. Katup mitral
7. Vena pulmonalis

WORKSHEETS (LEMBAR KERJA)

Mata Kuliah	: Anatomi
Materi	: Anatomi Respirasi
NIM>Nama Mahasiswa	: 2110101078/ Sabilla Ratu Cetrin

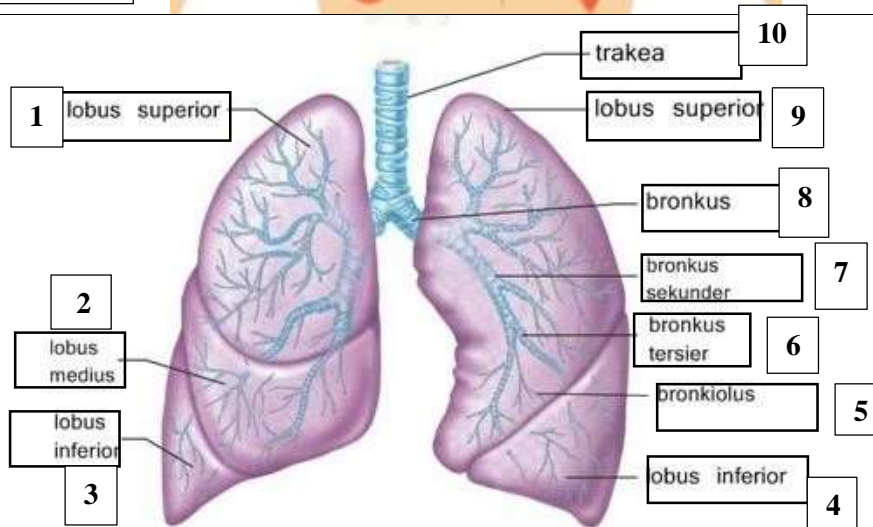
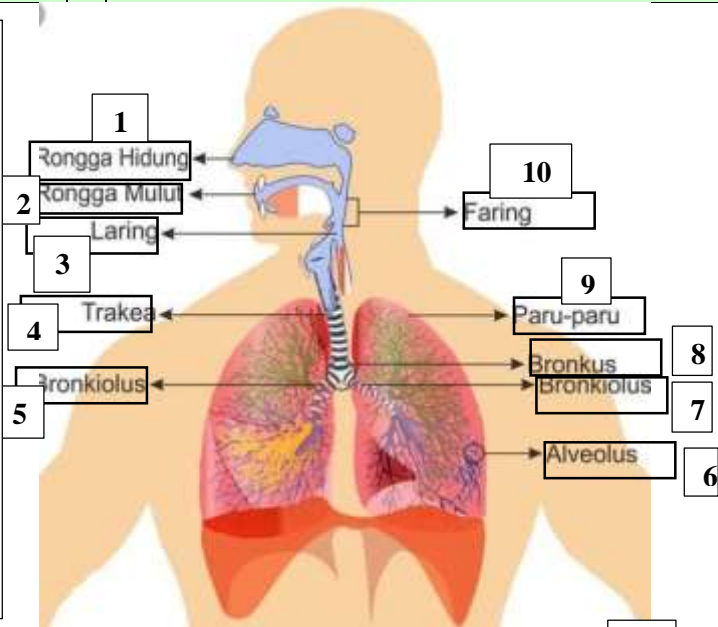
No	Keterangan	Pembahasan
1		

<p>Keterangan Gambar:</p> <ol style="list-style-type: none"> 1. Faring 2. Laring 3. Bronkus 4. Paru-paru kanan 5. Pleura 6. Diafragma 7. Paru-paru kiri 8. Bronkus perantara 9. Bronkiolus 10. Trakea 11. Rongga hidung

No	Keterangan	Pembahasan
----	------------	------------

Keterangan Gambar:

1. Rongga hidung
2. Rongga mulut
3. laring
4. Trakea
5. Bronkiolus
6. Alveolus
7. Bronkiolus
8. Bronkus
9. Paru-paru
10. faring



Keterangan gambar:

1. Lobus superior
2. Lobus medius
3. Lobus inferior
4. Lobus inferior
5. Bronkiolus
6. Bronkus tersier
7. Bronkus skunder
8. Bronkus
9. Lobus superior
10. trakea