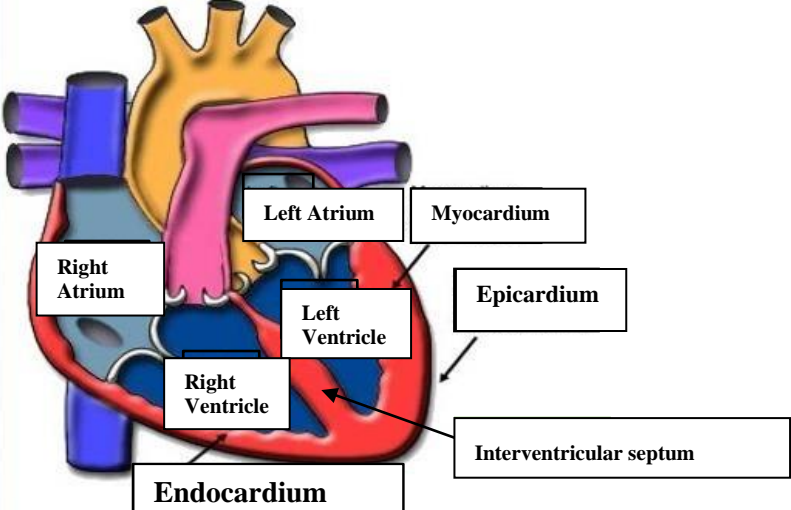
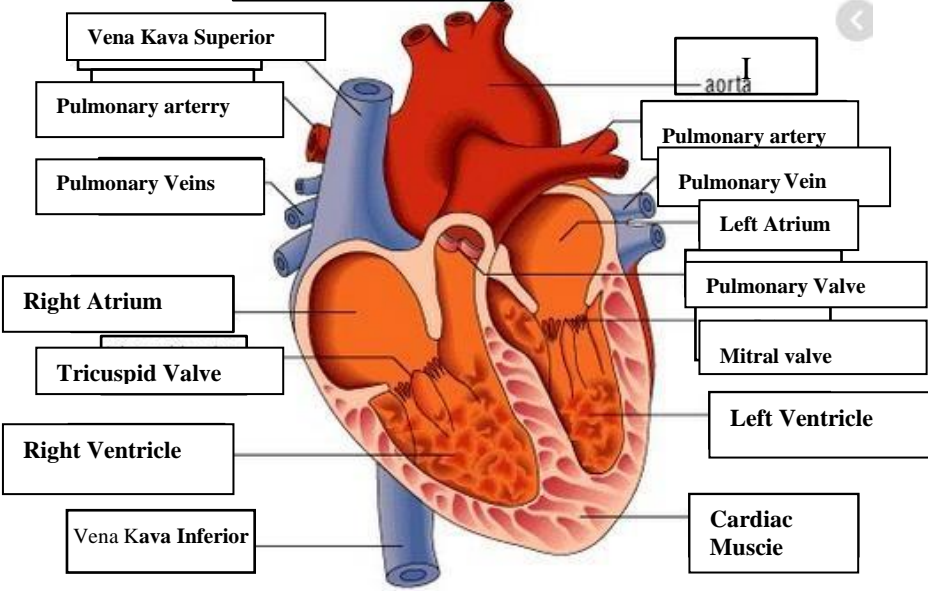
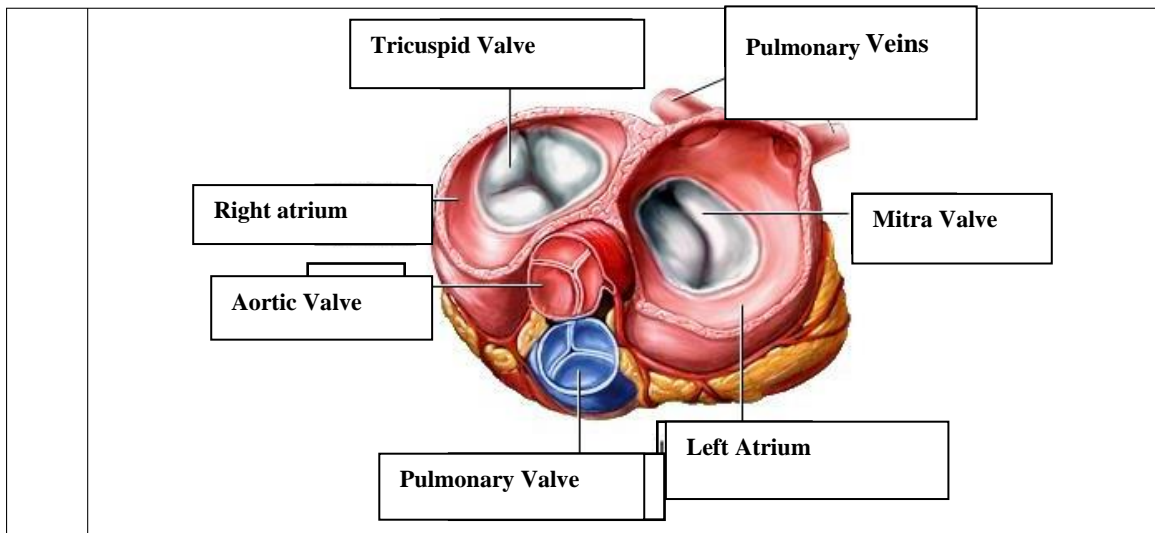


WORKSHEETS (LEMBAR KERJA)

Mata Kuliah	: Anatomi
Materi	: Anatomi Cardiovaskuler
NIM>Nama Mahasiswa	: nurul sabillah

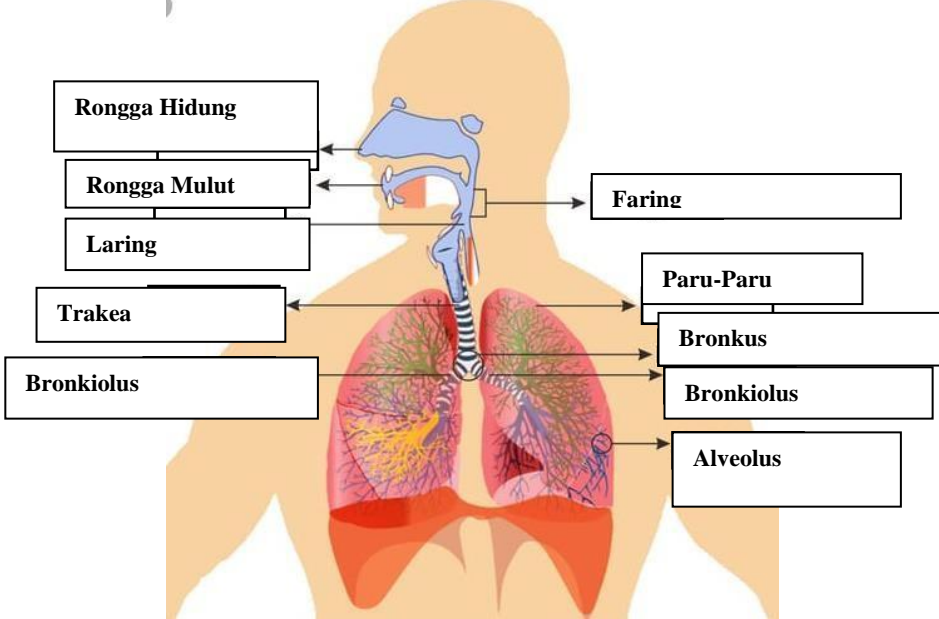
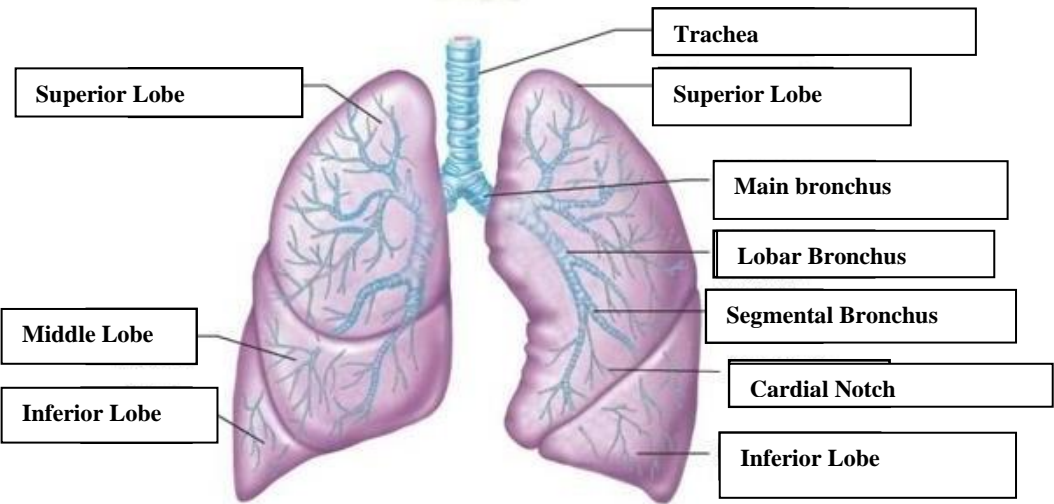
No	Keterangan	Pembahasan
1		 <p>This diagram shows a cross-section of the heart wall with the following labels: Right Atrium, Left Atrium, Right Ventricle, Left Ventricle, Myocardium, Epicardium, Endocardium, and Interventricular septum. An arrow on the left points towards the diagram.</p>
		 <p>This diagram shows a cross-section of the heart with the following labels: Vena Kava Superior, Pulmonary artery, Pulmonary Veins, Right Atrium, Tricuspid Valve, Right Ventricle, Vena Kava Inferior, aorta, Pulmonary Valve, Left Atrium, Mitral valve, Left Ventricle, and Cardiac Muscie.</p>



WORKSHEETS (LEMBAR KERJA)

Mata Kuliah	: Anatomi
Materi	: Anatomi Respirasi
NIM>Nama Mahasiswa	: nurul sabillah

No	Keterangan	Pembahasan
1	<p>An anatomical diagram of the human respiratory system. It shows the nasal cavity (Rongga Hidung), pharynx (Faring), larynx (Laring), trachea (Trakea), bronchi (Bronkus), bronchioles (Bronkiolus), and lungs (Paru-Paru kanan and Paru-Paru kiri). The pleura and diaphragm (Diafragma) are also labeled. Labels with leader lines point to each of these structures.</p>	

No	Keterangan	Pembahasan
		 <p>Diagram illustrating the human respiratory system with labels:</p> <ul style="list-style-type: none"> Rongga Hidung Rongga Mulut Laring Trakea Bronkiolus Faring Paru-Paru Bronkus Bronkiolus Alveolus
		 <p>Diagram illustrating the structure of the lungs with labels:</p> <ul style="list-style-type: none"> Superior Lobe Middle Lobe Inferior Lobe Trachea Superior Lobe Main bronchus Lobar Bronchus Segmental Bronchus Cardial Notch Inferior Lobe

