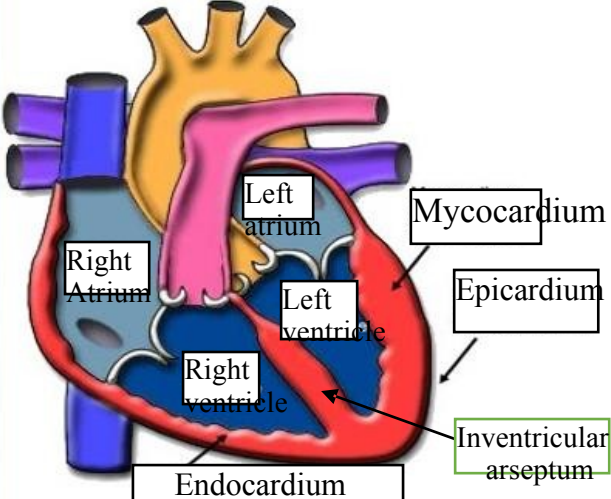
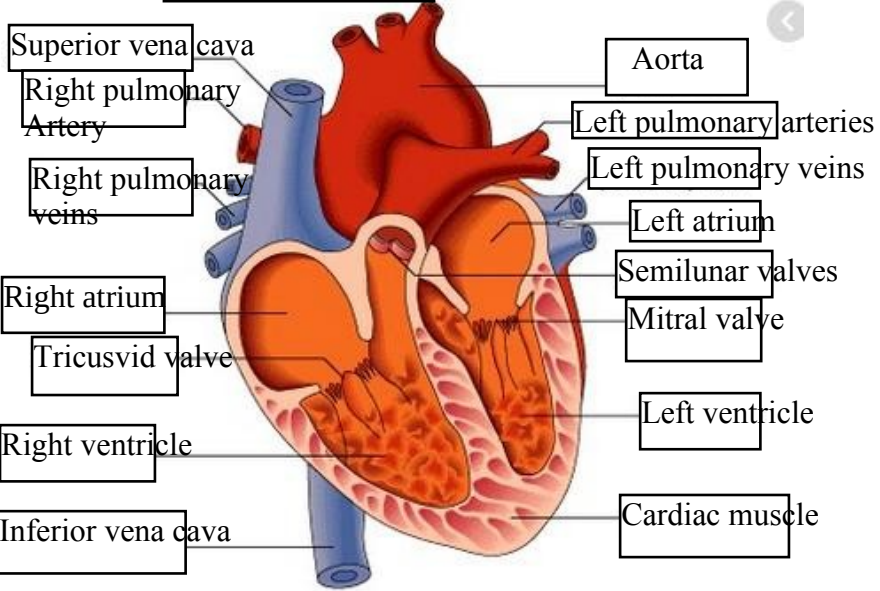
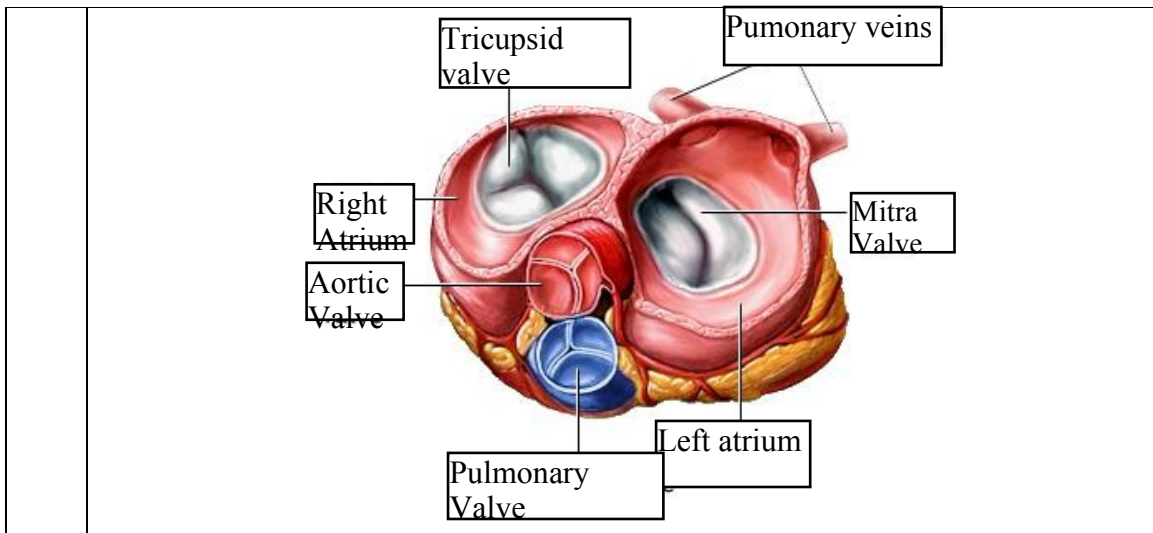


**WORKSHEETS (LEMBAR KERJA)**

<b>Mata Kuliah</b>	: Anatomi
<b>Materi</b>	: Anatomi Cardiovaskuler
<b>NIM&gt;Nama Mahasiswa</b>	: 2110101133/AQILA HANA AMADEA

No	Keterangan	Pembahasan
1		
		



**WORKSHEETS (LEMBAR KERJA)**

<b>Mata Kuliah</b>	: Anatomi
<b>Materi</b>	: Anatomi Respirasi
<b>NIM&gt;Nama Mahasiswa</b>	: 2110101133/Aqila Hana Amadea

No	Keterangan	Pembahasan
1	<p>An anatomical diagram of the human respiratory system. Labels with leader lines point to: pharynx, Esophagus, Bronkus, Paru-paru kanan, Pleura, Nasal cavity, Traches, Bronkiolus, Bronkus, Paru-paru Kiri, and Diafragma.</p>	

No	Keterangan	Pembahasan
----	------------	------------

