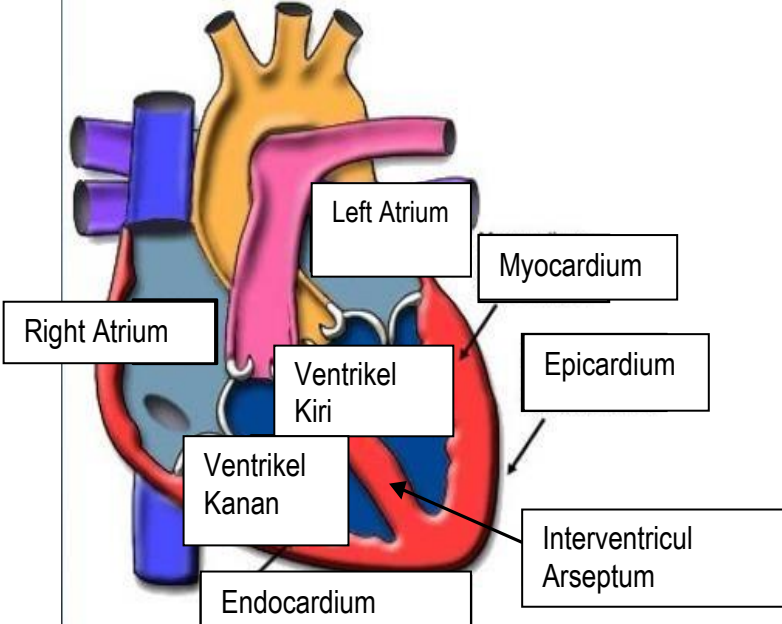
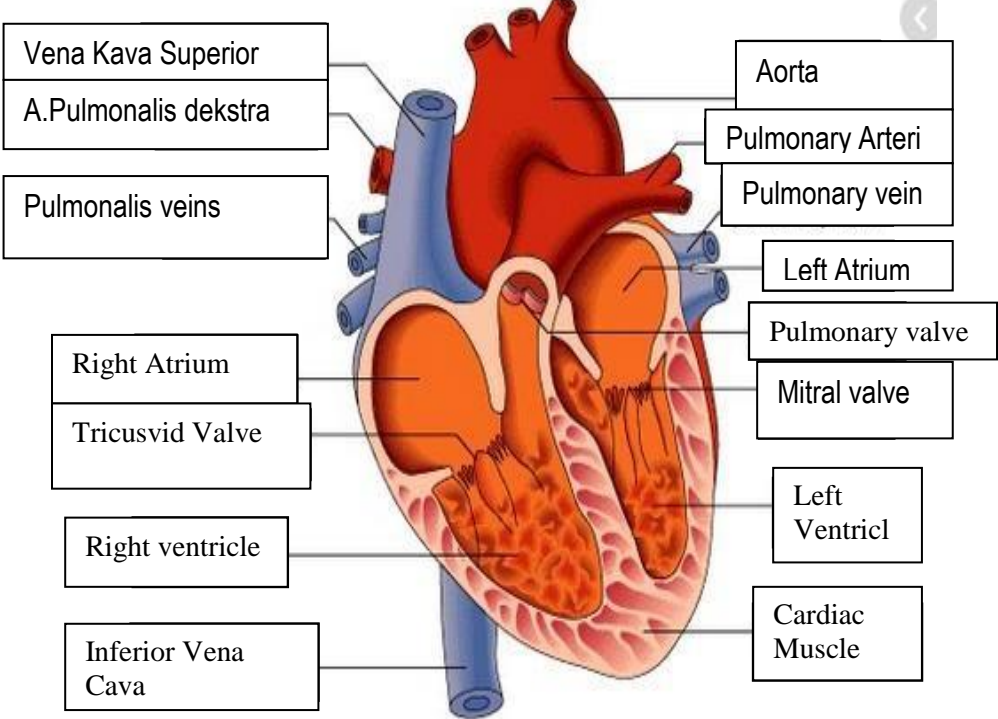
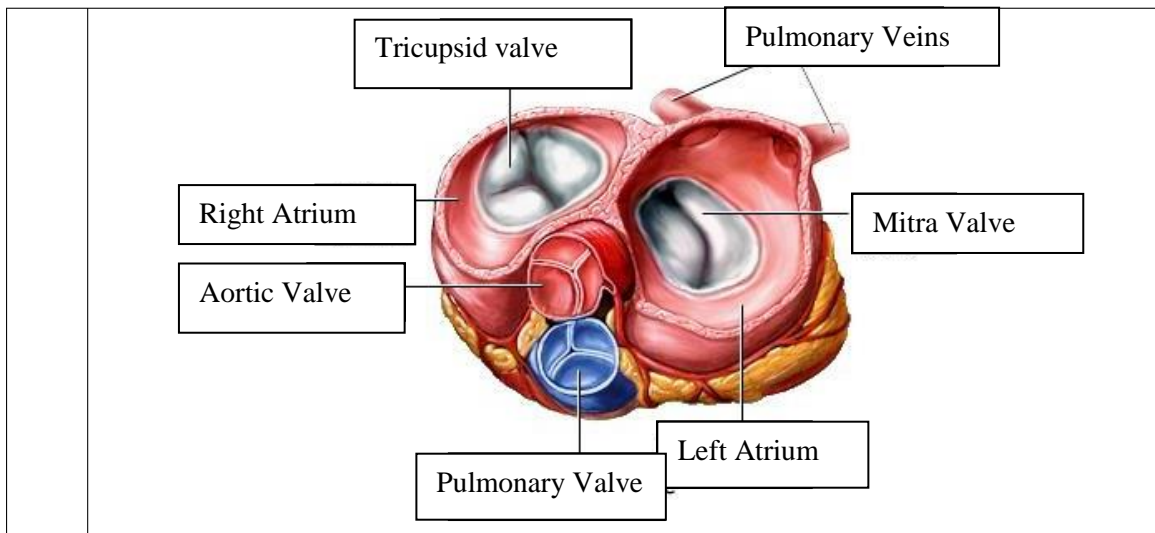


WORKSHEETS (LEMBAR KERJA)

Mata Kuliah	: Anatomi
Materi	: Anatomi Cardiovaskuler
NIM/Nama Mahasiswa	: Musyarofah /2110101129

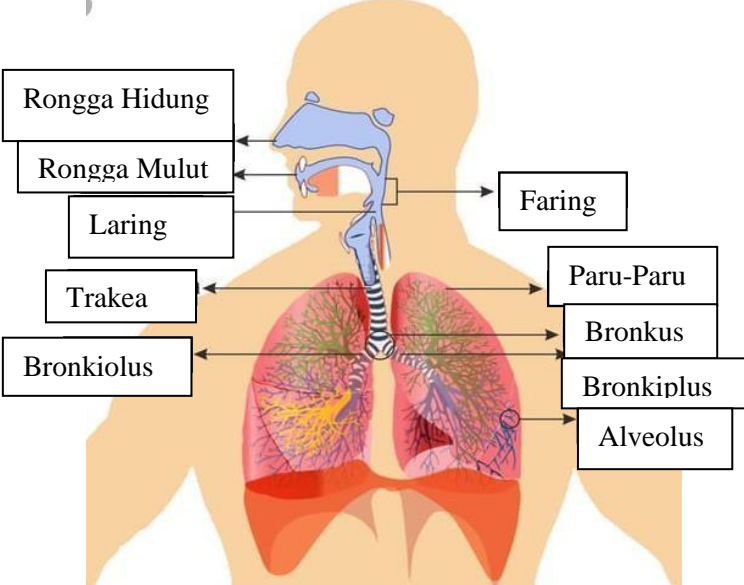
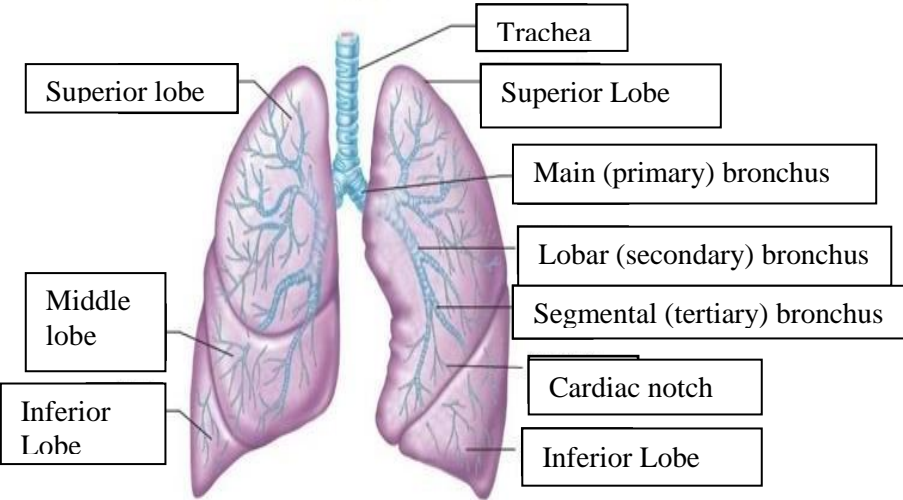
No	Keterangan	Pembahasan
1		 <p>This diagram shows a cross-section of the heart wall with the following labeled parts:</p> <ul style="list-style-type: none"> Left Atrium Myocardium Right Atrium Ventrikel Kiri Epicardium Ventrikel Kanan Interventricular Arseptum Endocardium
	<p>Vena Kava Superior</p> <p>A.Pulmonalis dekstra</p> <p>Pulmonalis veins</p> <p>Right Atrium</p> <p>Tricusvid Valve</p> <p>Right ventricle</p> <p>Inferior Vena Cava</p>	 <p>This diagram shows a cross-section of the heart with the following labeled parts:</p> <ul style="list-style-type: none"> Aorta Pulmonary Arteri Pulmonary vein Left Atrium Pulmonary valve Mitral valve Left Ventricl Cardiac Muscle



WORKSHEETS (LEMBAR KERJA)

Mata Kuliah	: Anatomi
Materi	: Anatomi Respirasi
NIM>Nama Mahasiswa	: Musyarofah/2110101129

No	Keterangan	Pembahasan
1	<p>An anatomical diagram of the human respiratory system, showing the airway from the nasal cavity to the lungs and the diaphragm. The diagram is labeled with the following parts:</p> <ul style="list-style-type: none"> Pharynx Nasal Cavity Esophagus Trachea Bronchus Bronkiolus Paru Paru Kanan Bronchus Paru-Paru Kiri Pleura Diafragma 	

No	Keterangan	Pembahasan
		 <p>Diagram of the human respiratory system with the following labels:</p> <ul style="list-style-type: none"> Rongga Hidung Rongga Mulut Laring Trakea Bronkiolus Faring Paru-Paru Bronkus Bronkiplus Alveolus
		 <p>Diagram of the lungs with the following labels:</p> <ul style="list-style-type: none"> Superior lobe Middle lobe Inferior Lobe Trachea Superior Lobe Main (primary) bronchus Lobar (secondary) bronchus Segmental (tertiary) bronchus Cardiac notch Inferior Lobe

