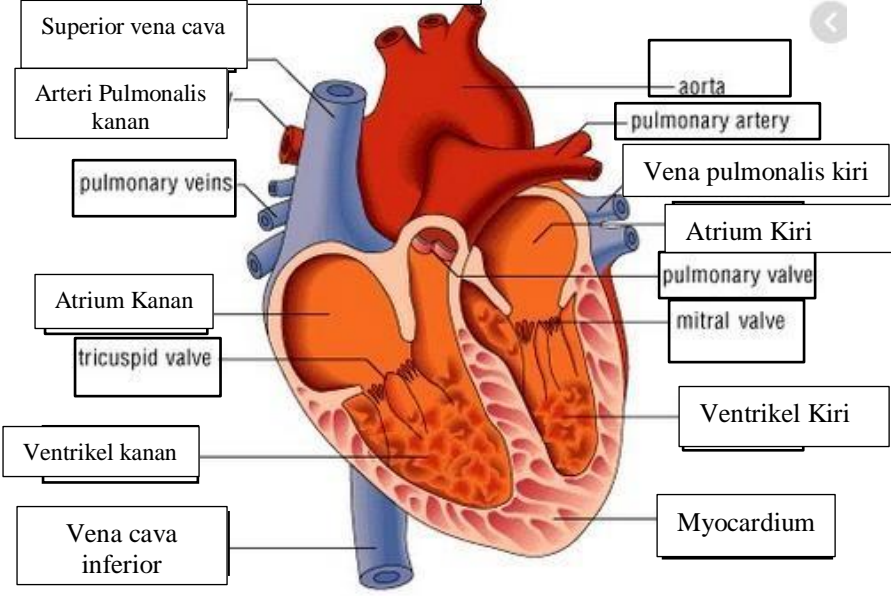
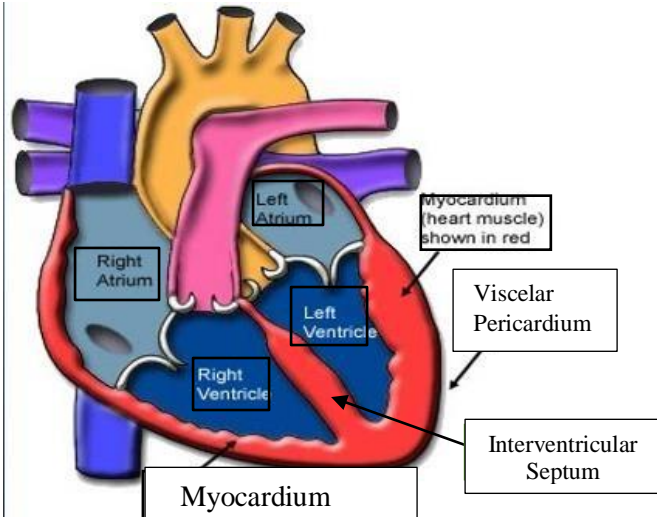


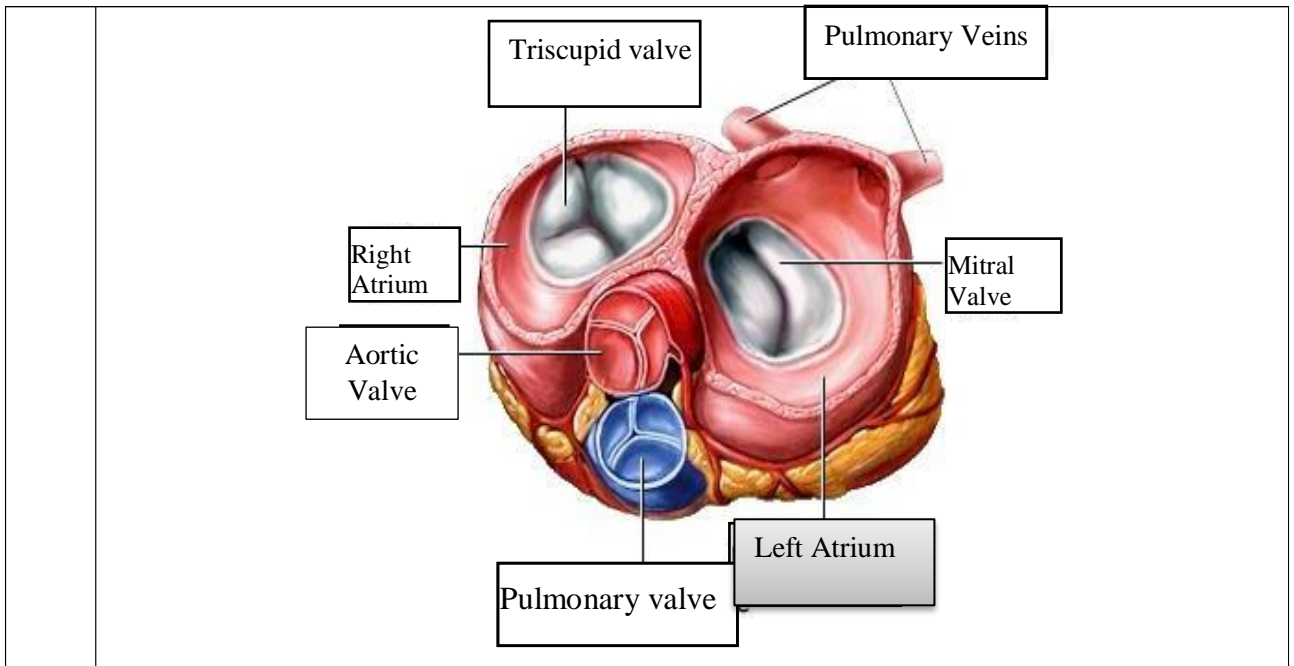
WORKSHEETS (LEMBAR KERJA)

Mata Kuliah	:	Anatomi
Materi	:	Anatomi Cardiovaskuler
NIM>Nama Mahasiswa		2110101127/Thasya Ananda

No	Keterangan	Pembahasan
----	------------	------------

1

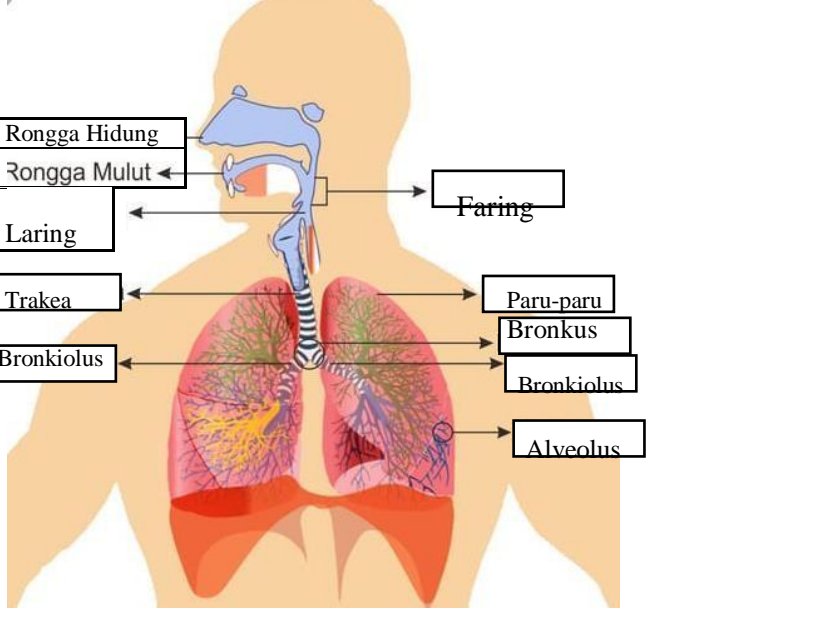
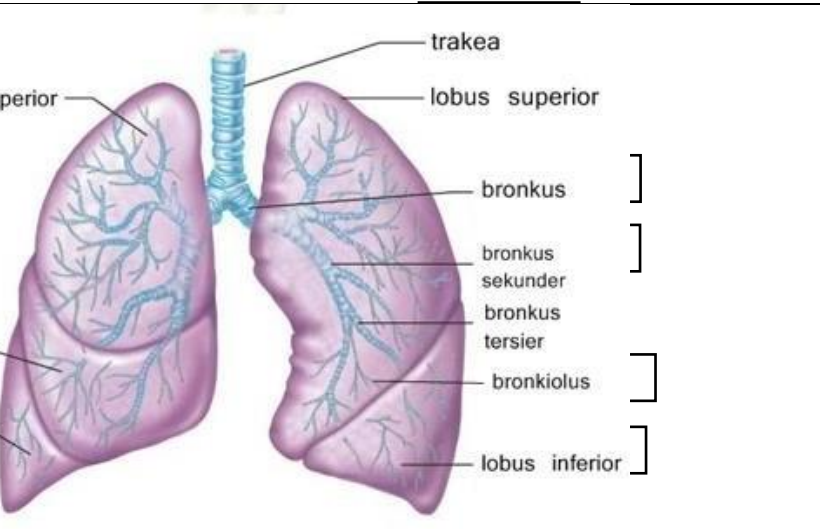




WORKSHEETS (LEMBAR KERJA)

Mata Kuliah	: Anatomi
Materi	: Anatomi Respirasi
NIM>Nama Mahasiswa	: 2110101127/Thasya Ananda

No	Keterangan	Pembahasan
1	<p>An anatomical diagram of the human respiratory system. Labels include: Faring, Laring, Bronkus, Paru-paru kanan, Pleura, Diafragma, Rongga hidung, Trakea, Bronkiolus, Bronkus, and Paru-paru kiri.</p>	

No	Keterangan	Pembahasan
		 <p>Diagram of the human respiratory system with labels: Rongga Hidung, Rongga Mulut, Laring, Trakea, Bronkiolus, Faring, Paru-paru, Bronkus, and Alveolus.</p>
		 <p>Detailed diagram of the lungs with labels: trakea, lobus superior, lobus medius, lobus inferior, bronkus, bronkus sekunder, bronkus tersier, bronkiolus, and lobus inferior.</p>