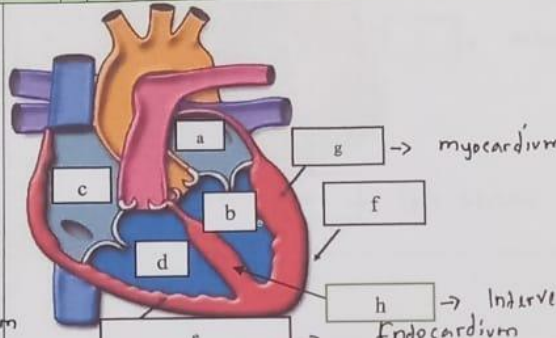
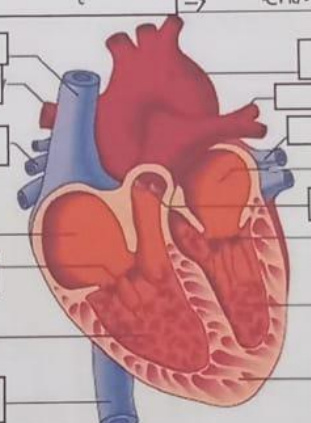
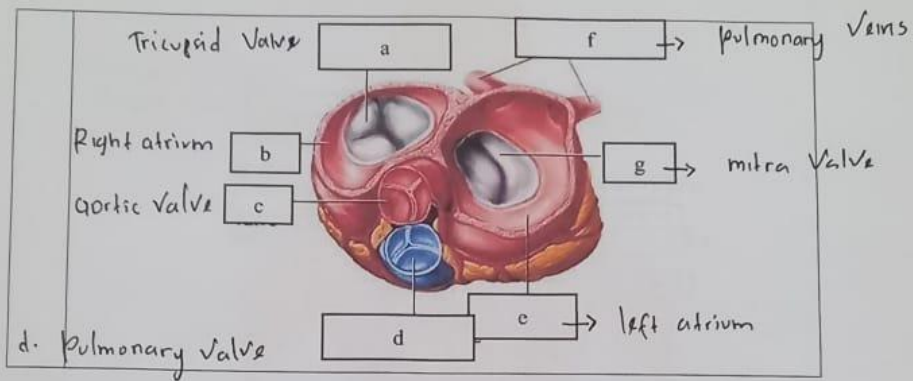


WORKSHEETS (LEMBAR KERJA)

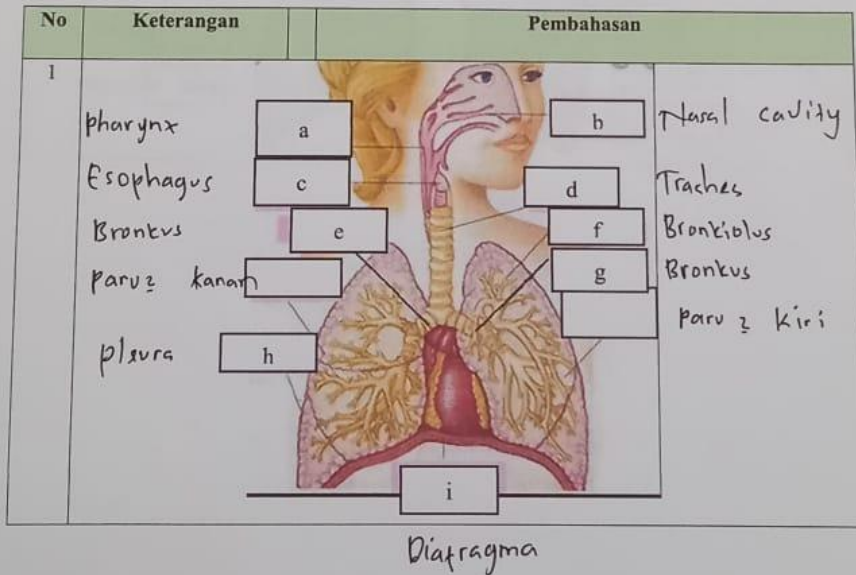
Mata Kuliah	: Anatomi
Materi	: Anatomi Cardiovaskuler
NIM>Nama Mahasiswa	: 2110101093 / Nurul Fajila

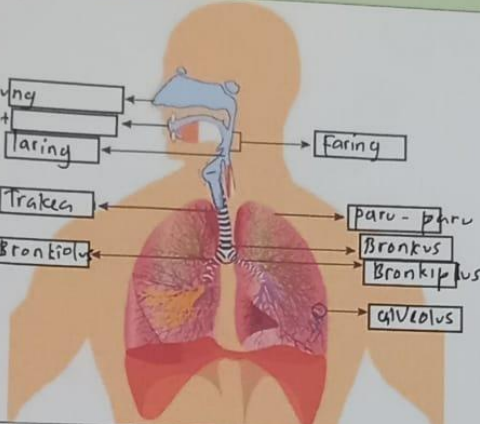
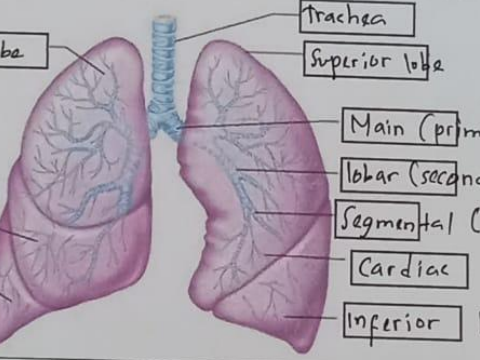
No	Keterangan	Pembahasan
1	<p>a. left atrium</p> <p>b. Vertikal Kiri</p> <p>c. Right atrium</p> <p>d. Vertikal Kanan</p> <p>f. Epicardium</p>	 <p>g → myocardium</p> <p>f</p> <p>h → Interventricular Septum</p> <p>e → Endocardium</p>
	<p>Vena kava superior J</p> <p>pulmonalis dextra K</p> <p>pulmonalis Venis L</p> <p>Right atrium</p> <p>tricuspid Valve Q</p> <p>Right Ventricle</p> <p>Inferior Vena Cava R</p>	 <p>I aorta</p> <p>M pulmonalis arteri</p> <p>N pulmonalis Vain</p> <p>O left atrium</p> <p>P pulmonalis Valve</p> <p>left Ventricle</p> <p>cardiac muscle</p>



WORKSHEETS (LEMBAR KERJA)

Mata Kuliah	: Anatomi
Materi	: Anatomi Respirasi
NIM>Nama Mahasiswa	:



No	Keterangan	Pembahasan
	<p>Rongga hidung</p> <p>Rongga mulut</p> <p>Laring</p> <p>Trakea</p> <p>Bronkiolus</p>	 <p>Faring</p> <p>paru-paru</p> <p>Bronkus</p> <p>Bronkiolus</p> <p>alveolus</p>
	<p>Superior lobe</p> <p>Middle lobe</p> <p>Inferior lobe</p>	 <p>Trachea</p> <p>Superior lobe</p> <p>Main (primary) bronchus</p> <p>lobar (secondary) bronchus</p> <p>Segmental (tertiary) bronchus</p> <p>Cardiac notch</p> <p>Inferior lobe</p>