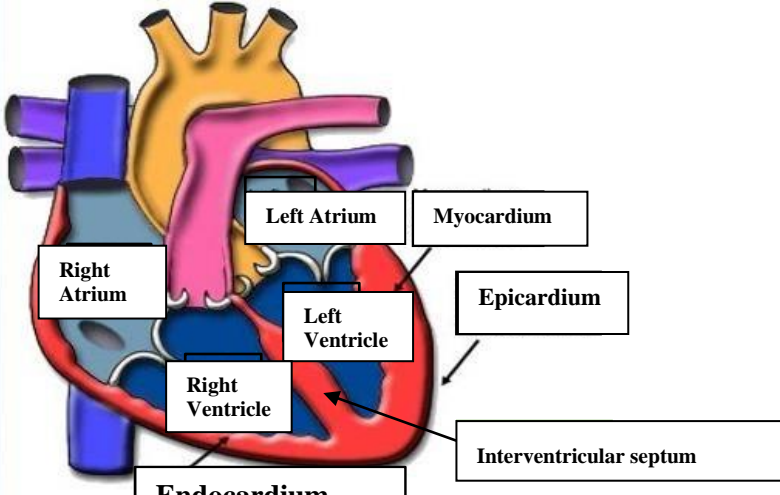
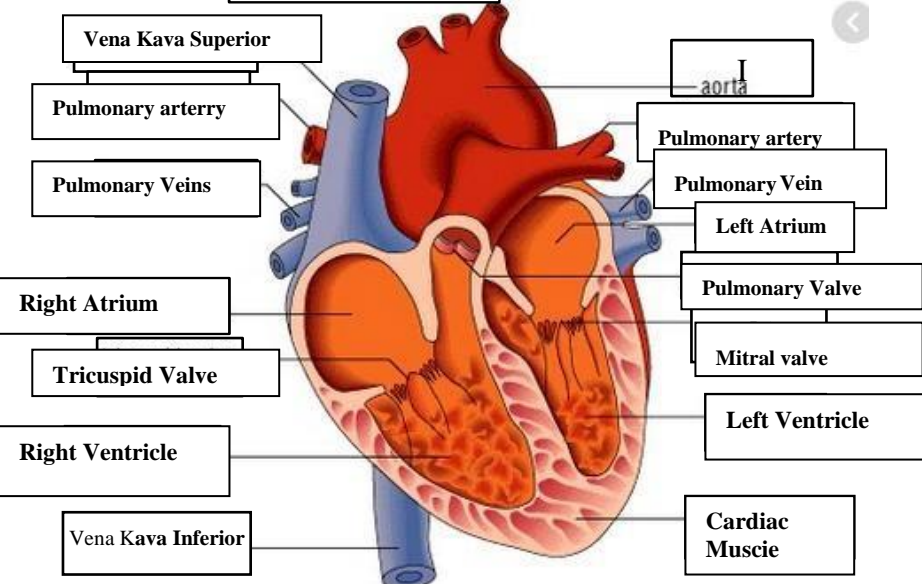
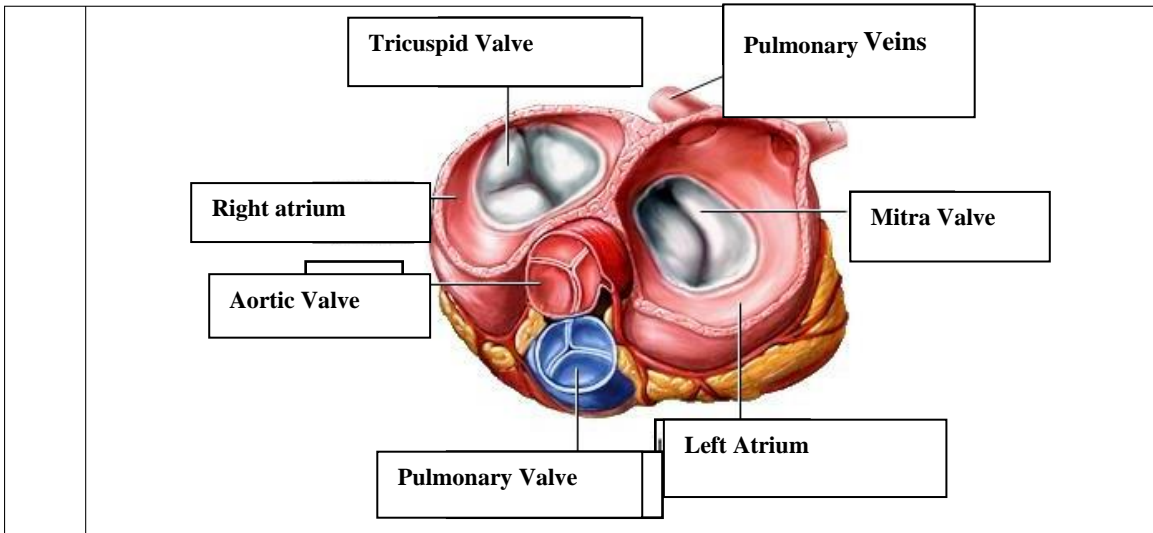


WORKSHEETS (LEMBAR KERJA)

Mata Kuliah	: Anatomi
Materi	: Anatomi Cardiovaskuler
NIM>Nama Mahasiswa	: <i>Erlina Erlina</i>

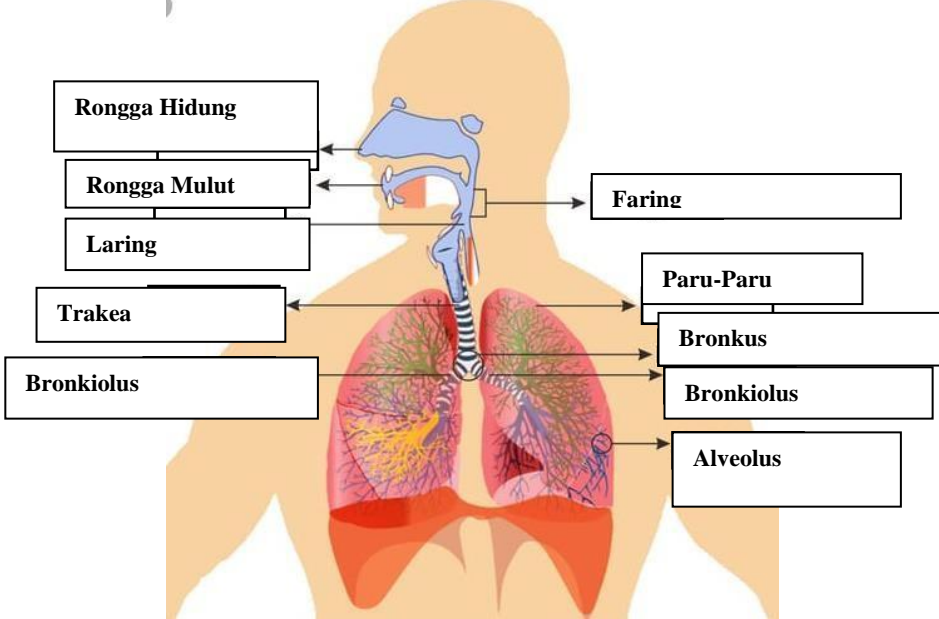
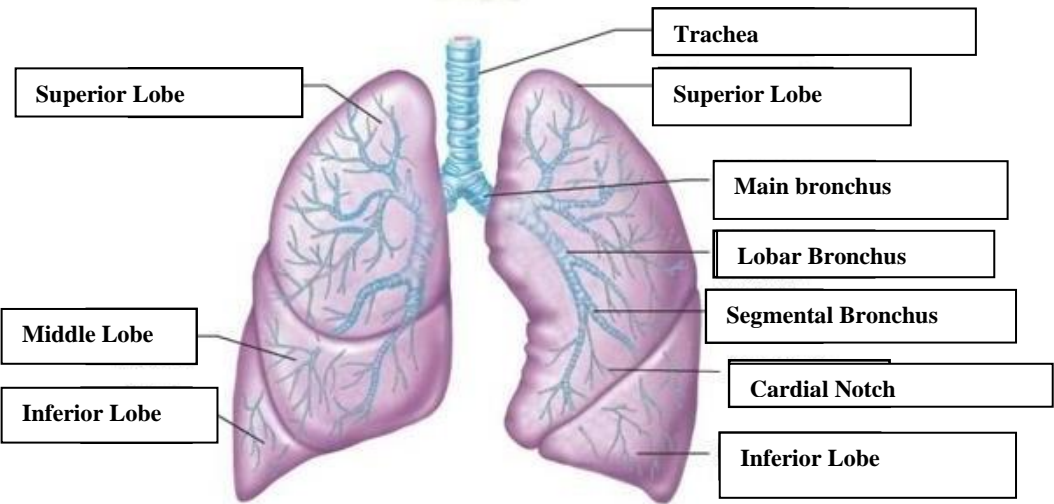
No	Keterangan	Pembahasan
1		 <p>This diagram shows a cross-section of the heart wall with the following labels: Right Atrium, Left Atrium, Myocardium, Epicardium, Left Ventricle, Right Ventricle, Interventricular septum, and Endocardium.</p>
		 <p>This diagram shows a cross-section of the heart chambers and valves with the following labels: Vena Kava Superior, Pulmonary artery, Pulmonary Veins, Right Atrium, Tricuspid Valve, Right Ventricle, Vena Kava Inferior, aorta, Pulmonary artery, Pulmonary Vein, Left Atrium, Pulmonary Valve, Mitral valve, Left Ventricle, and Cardiac Muscie.</p>



WORKSHEETS (LEMBAR KERJA)

Mata Kuliah	: Anatomi
Materi	: Anatomi Respirasi
NIM>Nama Mahasiswa	: 2110101125/Sári Ismi Harsih

No	Keterangan	Pembahasan
1	<p>An anatomical diagram of the human respiratory system. Labels include: Faring (throat), Laring (voice box), Bronkus (bronchi), Paru-Paru kanan (right lung), Pleura (lung lining), Diafragma (diaphragm), Rongga Hidung (nasal cavity), Trakea (trachea), Bronkiolus (bronchioles), Bronkus (bronchi), and Paru-Paru kiri (left lung).</p>	

No	Keterangan	Pembahasan
		 <p>Diagram of the human respiratory system with labels:</p> <ul style="list-style-type: none"> Rongga Hidung Rongga Mulut Laring Trakea Bronkiolus Faring Paru-Paru Bronkus Bronkiolus Alveolus
		 <p>Detailed diagram of the lungs with labels:</p> <ul style="list-style-type: none"> Superior Lobe Middle Lobe Inferior Lobe Trachea Superior Lobe Main bronchus Lobar Bronchus Segmental Bronchus Cardial Notch Inferior Lobe

