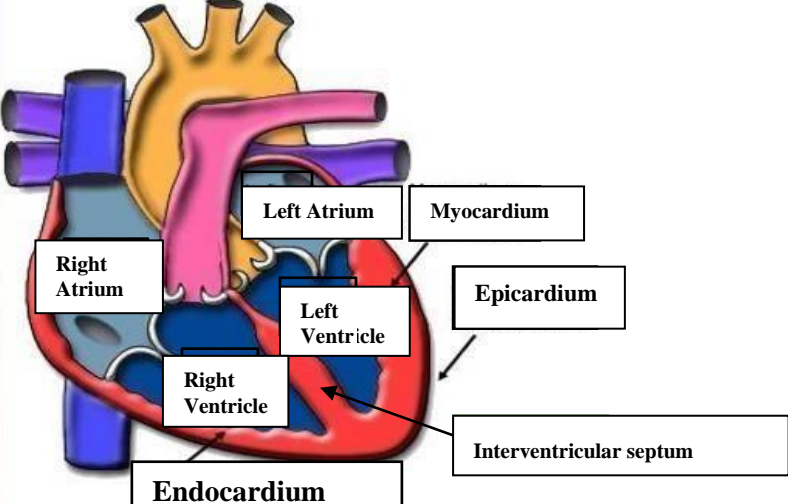
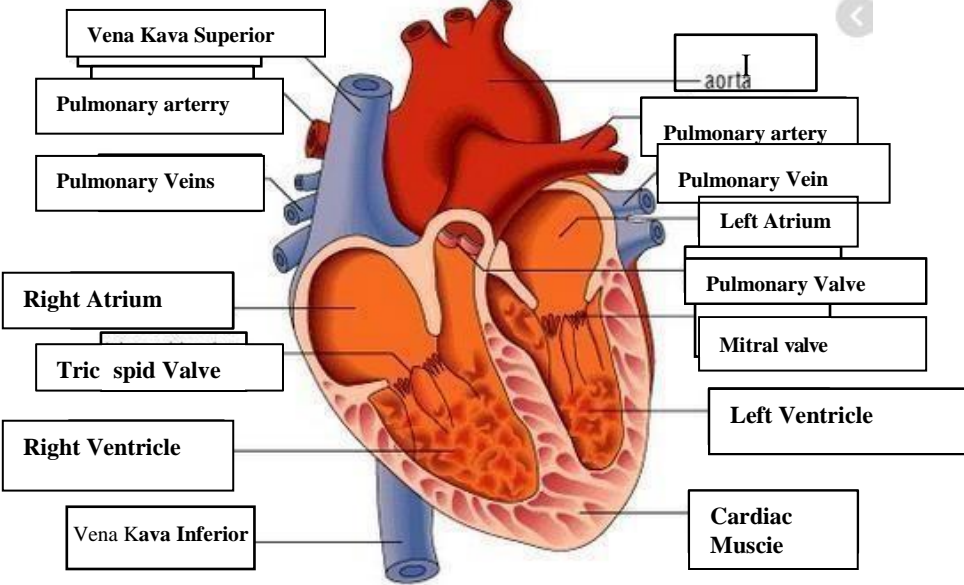
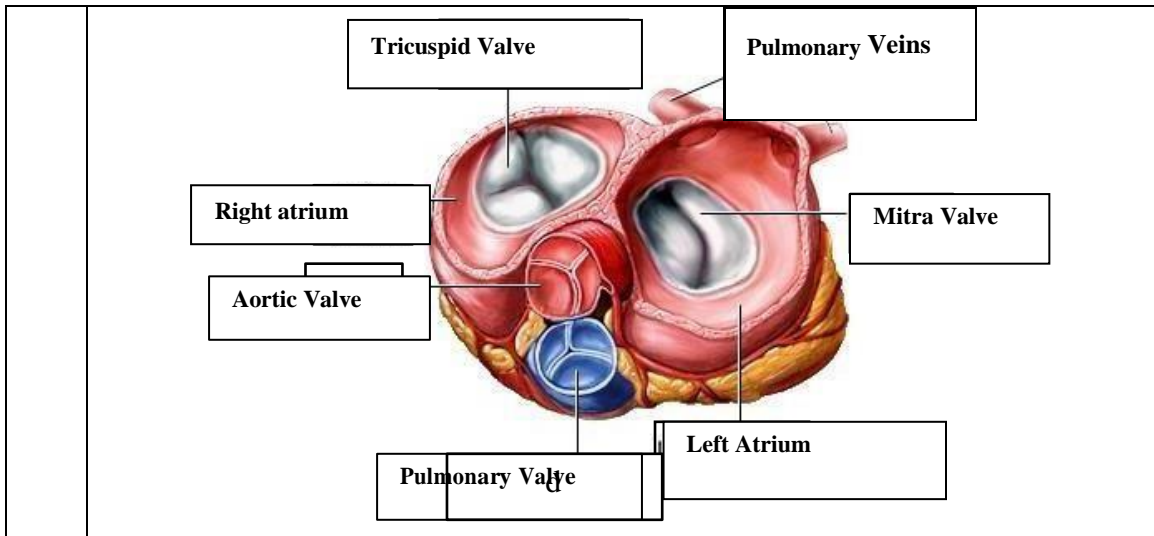


**WORKSHEETS (LEMBAR KERJA)**

<b>Mata Kuliah</b>	: Anatomi
<b>Materi</b>	: Anatomi Cardiovaskuler
<b>NIM&gt;Nama Mahasiswa</b>	: 2110101072/ fera widiawati

No	Keterangan	Pembahasan
1		
		



**WORKSHEETS (LEMBAR KERJA)**

<b>Mata Kuliah</b>	: Anatomi
<b>Materi</b>	: Anatomi Respirasi
<b>NIM&gt;Nama Mahasiswa</b>	: 2110101108 / JULITA MUTIARA

No	Keterangan	Pembahasan
1	<p>An anatomical diagram of the human respiratory system. It shows the nasal cavity (Rongga Hidung) leading to the pharynx (Faring), larynx (Laring), and trachea (Trakea). The trachea branches into bronchi (Bronkus) and bronchioles (Bronkiolus), which lead to the lungs (Paru-Paru kanan and Paru-Paru kiri). The lungs are surrounded by the pleura (Pleura). The diaphragm (Diafragma) is shown at the base of the thoracic cavity. Labels are in white boxes with black text, connected to the structures by thin black lines.</p>	

No	Keterangan	Pembahasan
----	------------	------------

