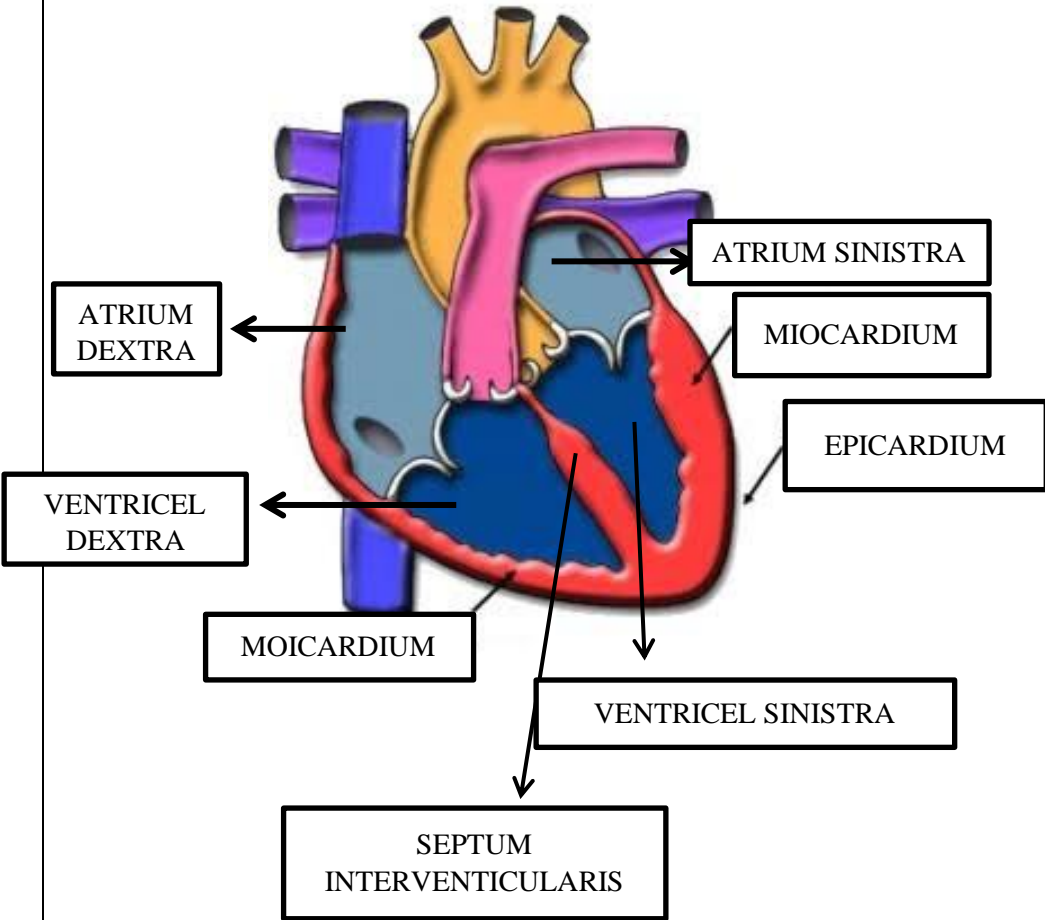
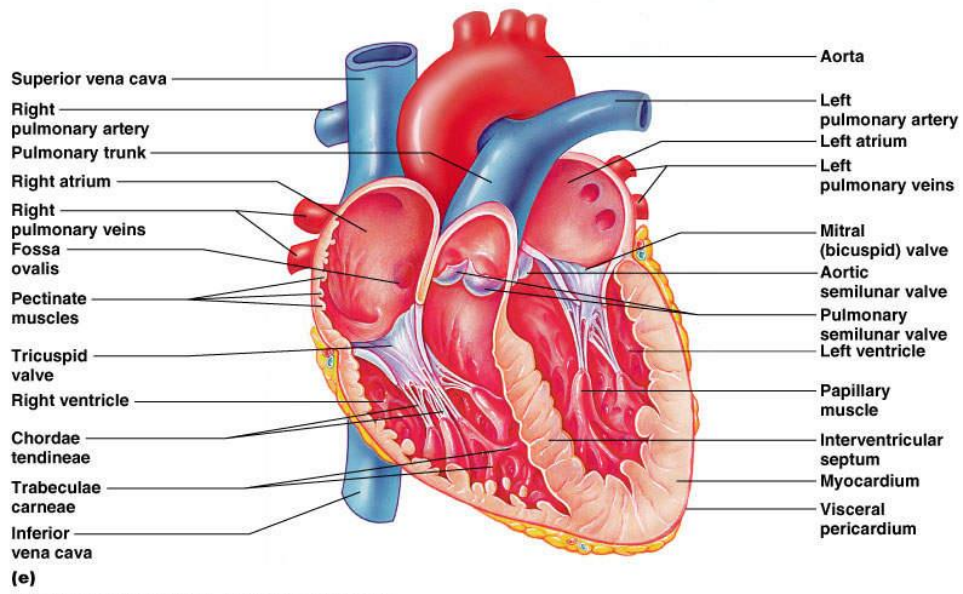


WORKSHEETS (LEMBAR KERJA)

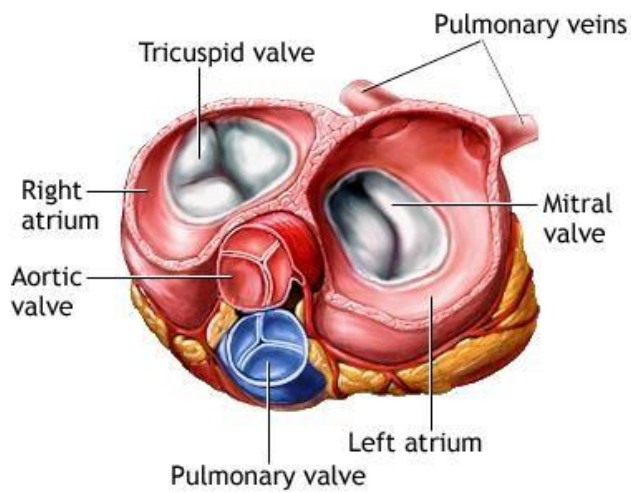
Mata Kuliah : Anatomi
Materi : Anatomi Cardiovaskuler
NIM>Nama Mahasiswa : 2110101070 / REGITA RIZQIANA RIFANINGTYAS CHABIB

N O	KETERANGAN	PEMBAH ASAN
1.	 <p>The diagram shows a cross-section of the heart wall. The outermost layer is labeled EPICARDIUM. The middle layer is labeled MIOCARDIUM (with a typo 'MOICARDIUM' in the label). The innermost layer is the endocardium. The chambers shown are the ATRIUM SINISTRA (top right), ATRIUM DEXTRA (top left), VENTRICLEL DEXTRA (bottom left), and VENTRICLEL SINISTRA (bottom right). The SEPTUM INTERVENTICULARIS is the wall between the two ventricles.</p>	

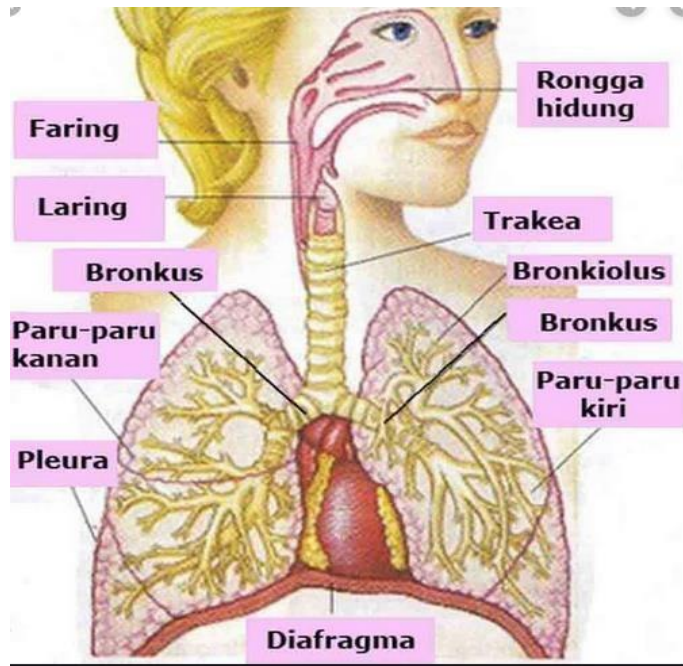
2.



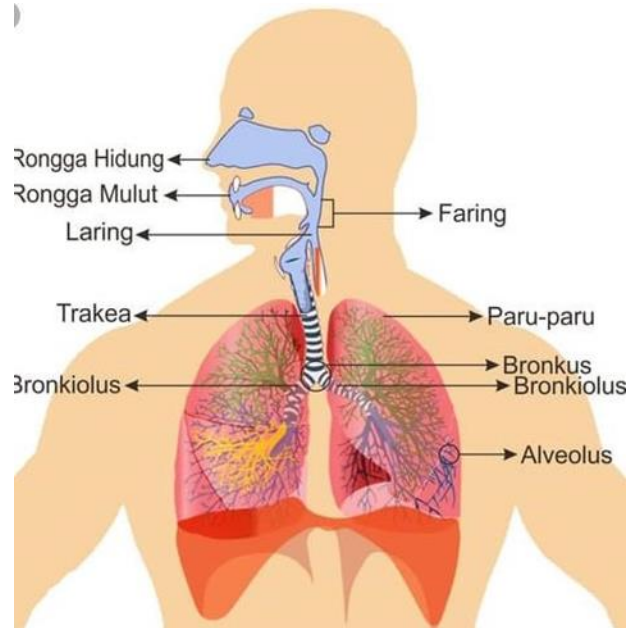
3.



4.



5.



6.

