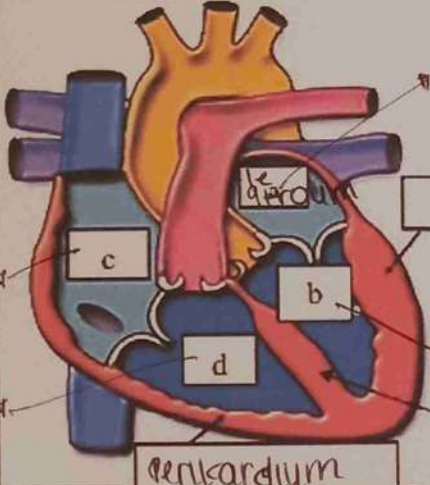
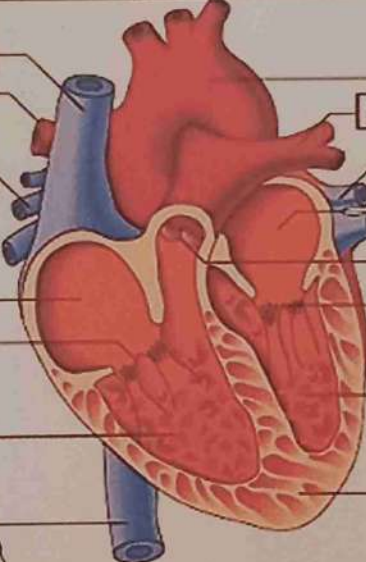
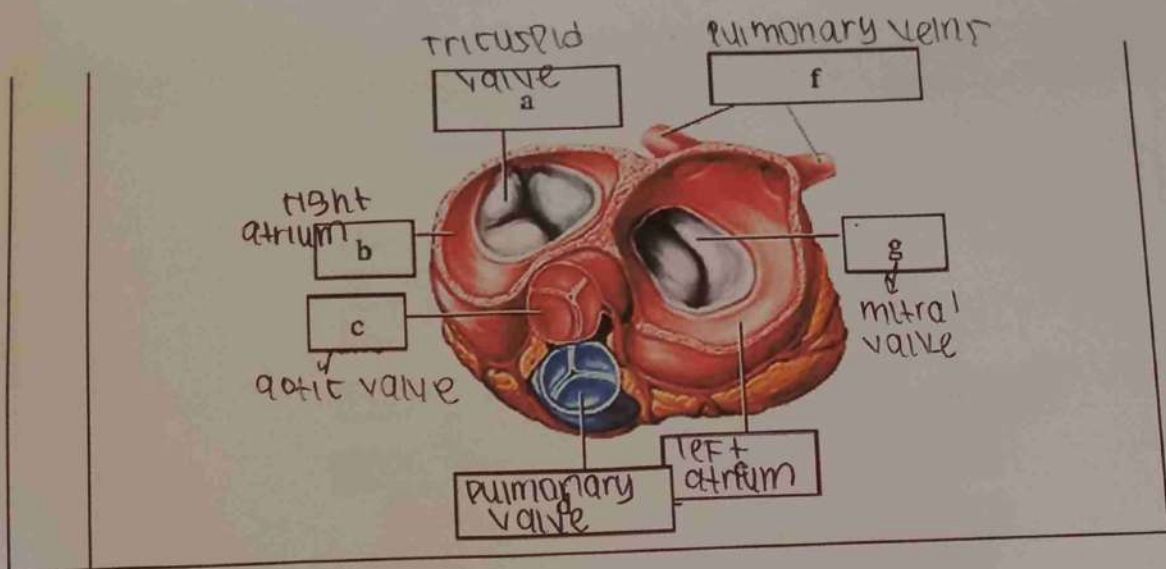


WORKSHEETS (LEMBAR KERJA)

Mata Kuliah : Anatomi
 Materi : Anatomi Cardiovaskuler
 NIM>Nama Mahasiswa : 2110101119/Khusnul Hotimah

No	Keterangan	Pembahasan
1	<p>tight atrium</p> <p>Ventrikel dextra</p>	 <p>atrium sinistra</p> <p>myocardium</p> <p>epicardium</p> <p>ventrikel sinistra</p> <p>endokardium</p> <p>perikardium</p> <p>g</p> <p>f</p> <p>b</p> <p>d</p> <p>c</p> <p>h</p>
	<p>Pulmonary artery</p> <p>Pulmonary veins</p> <p>tricuspid valve</p> <p>right atrium</p> <p>right ventricle</p> <p>inferior vena cava</p> <p>superior vena cava</p> <p>K</p> <p>L</p> <p>Q</p>	 <p>aorta</p> <p>pulmonary artery</p> <p>pulmonary vein</p> <p>left atrium</p> <p>o</p> <p>p</p> <p>left ventricle</p> <p>cardiac muscle</p> <p>pulmonary valve</p> <p>mitral valve</p>



WORKSHEETS (LEMBAR KERJA)

Mata Kuliah : Anatomi
 Materi : Anatomi Respirasi
 NIM>Nama Mahasiswa : 210101119 / KHUSNUL HOTIMAH

No	Keterangan	Pembahasan
1	<p>A hand-drawn anatomical diagram of the human respiratory system, showing the trachea, bronchi, and lungs. The labels are as follows:</p> <ul style="list-style-type: none"> Faring Laring bronkus paru-paru kanan Pleura rongga hidung trachea bronkiolus g paru-paru kiri Diaphragma 	

No	Keterangan	Pembahasan
----	------------	------------

