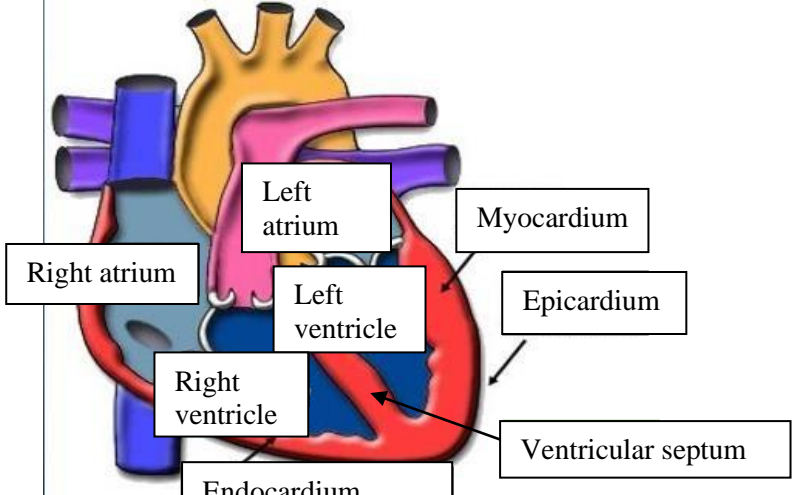
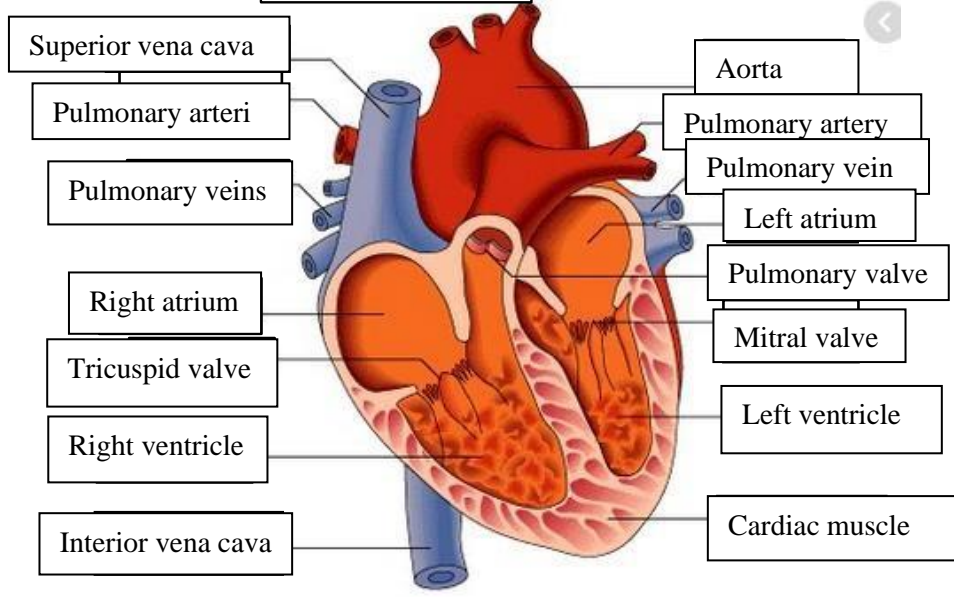
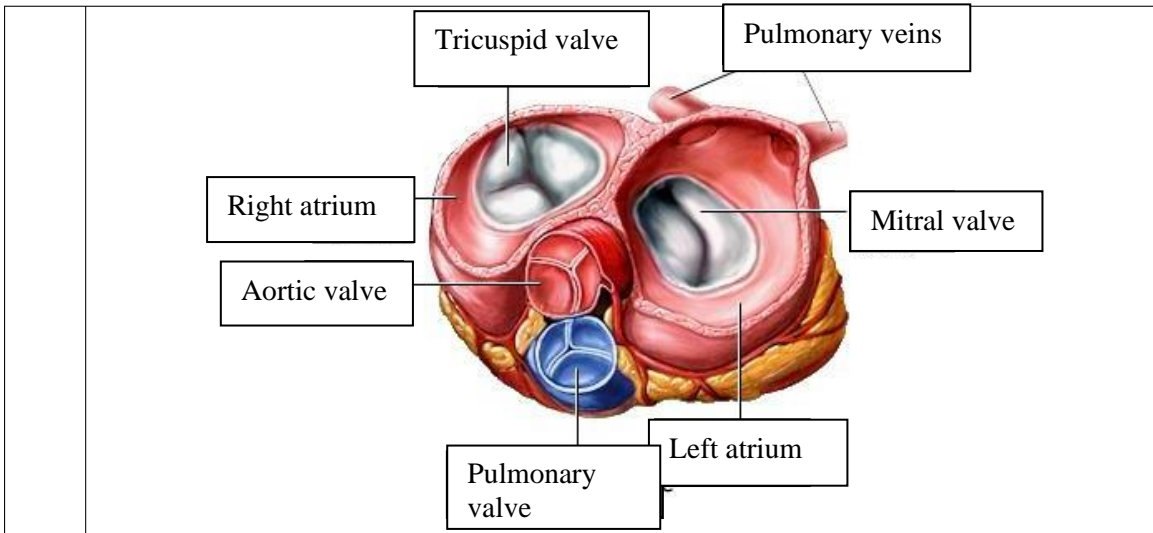


**WORKSHEETS (LEMBAR KERJA)**

<b>Mata Kuliah</b>	: <b>Anatomi</b>
<b>Materi</b>	: <b>Anatomi Cardiovaskuler</b>
<b>NIM&gt;Nama Mahasiswa</b>	: <b>MARIANA ULFA_2110101111</b>

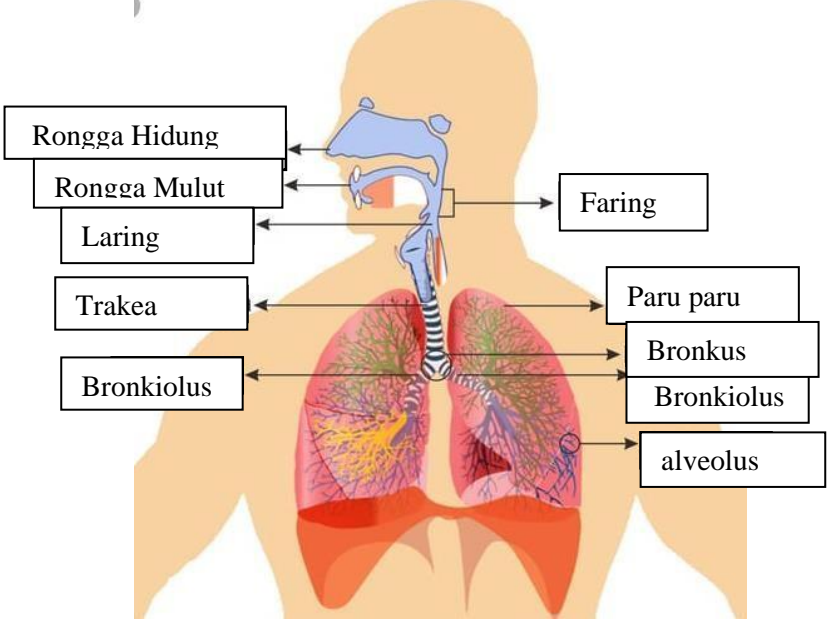
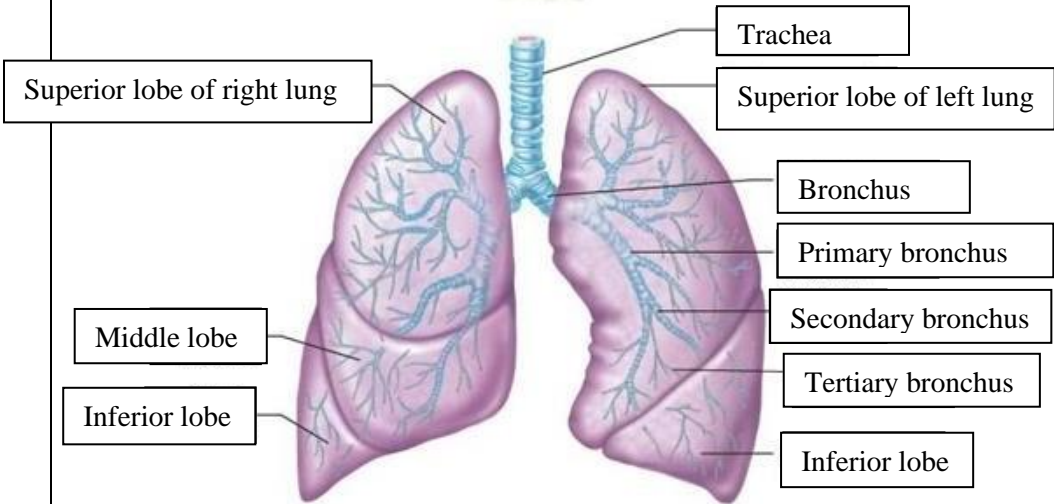
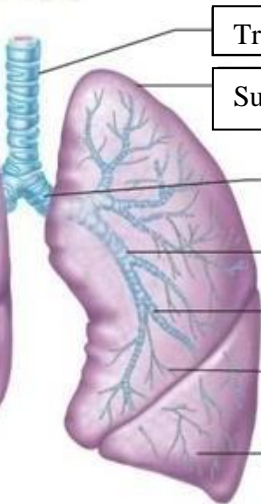
No	Keterangan	Pembahasan
1		
		



**WORKSHEETS (LEMBAR KERJA)**

<b>Mata Kuliah</b>	: Anatomi
<b>Materi</b>	: Anatomi Respirasi
<b>NIM&gt;Nama Mahasiswa</b>	: MARIANA ULFA_2110101111

No	Keterangan	Pembahasan
1	<p>An anatomical diagram of the human respiratory system. It shows the nasal cavity (Rongga hidung), pharynx (Faring), larynx (Laring), trachea (Trakea), bronchi (Bronchus and bronkus), bronchioles (Bronkiolus), and the lungs (Right lobes and Left lobes). The diaphragm (Diafragma) is shown at the base of the thoracic cavity. The pleura (Pluera) are shown covering the lungs. The diagram is color-coded, with pink for the upper respiratory tract and yellow for the lower respiratory tract.</p>	

No	Keterangan	Pembahasan
		 <p>Diagram of the human respiratory system with the following labels:</p> <ul style="list-style-type: none"> <li>Rongga Hidung</li> <li>Rongga Mulut</li> <li>Laring</li> <li>Trakea</li> <li>Bronkiolus</li> <li>Faring</li> <li>Paru paru</li> <li>Bronkus</li> <li>Bronkiolus</li> <li>alveolus</li> </ul>
	 <p>Labels for the lung lobes:</p> <ul style="list-style-type: none"> <li>Superior lobe of right lung</li> <li>Middle lobe</li> <li>Inferior lobe</li> <li>Superior lobe of left lung</li> <li>Inferior lobe</li> </ul>	 <p>Labels for the bronchial tree:</p> <ul style="list-style-type: none"> <li>Trachea</li> <li>Bronchus</li> <li>Primary bronchus</li> <li>Secondary bronchus</li> <li>Tertiary bronchus</li> </ul>

