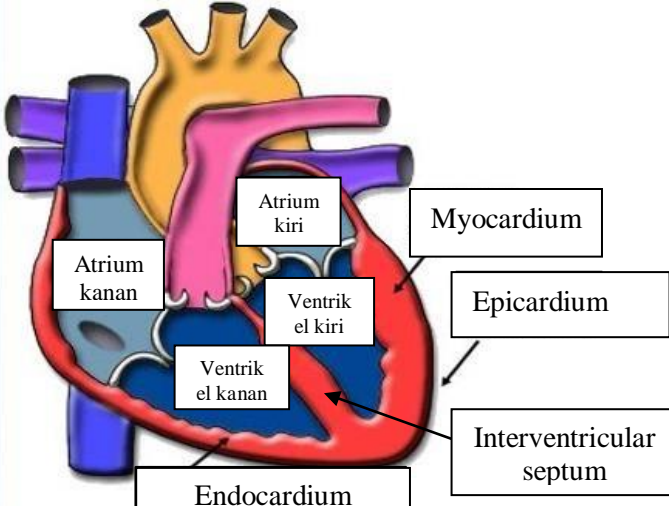
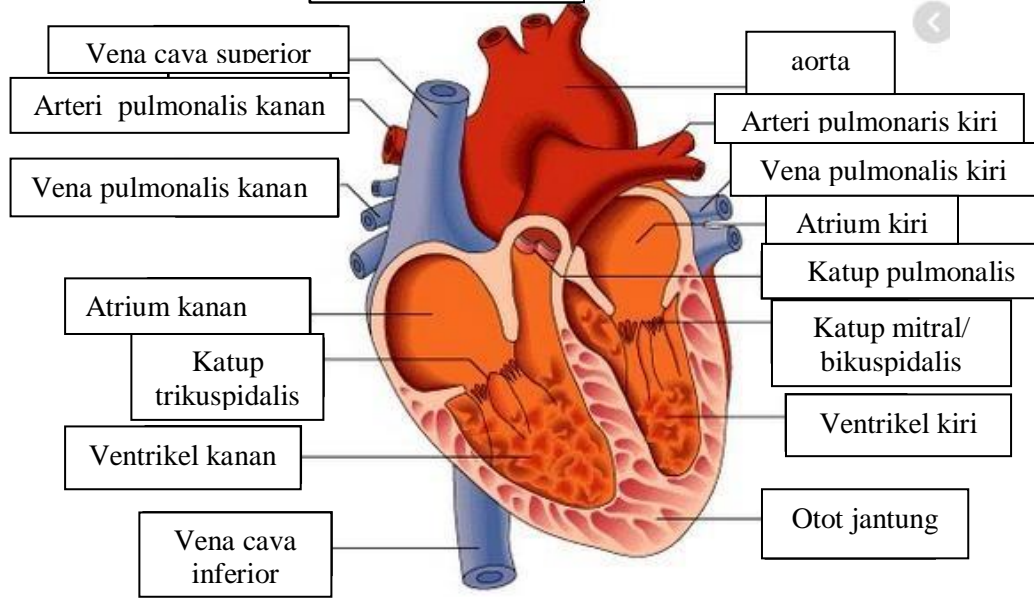
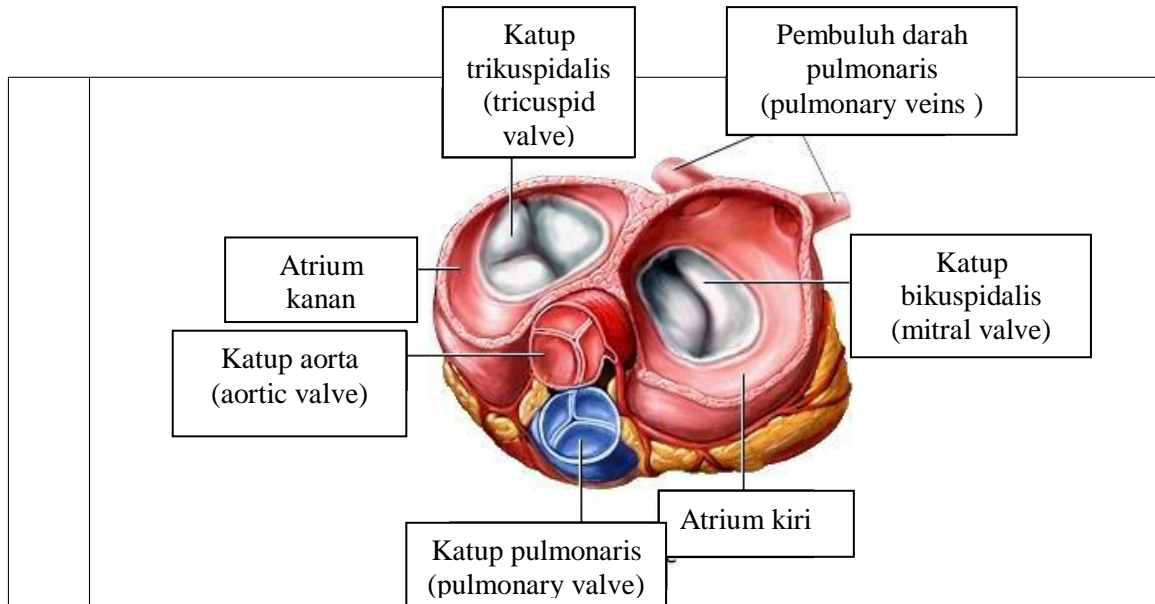


WORKSHEETS (LEMBAR KERJA)

Mata Kuliah	: Anatomi
Materi	: Anatomi Cardiovaskuler
NIM>Nama Mahasiswa	: 2110101110/Cici Liara Septi

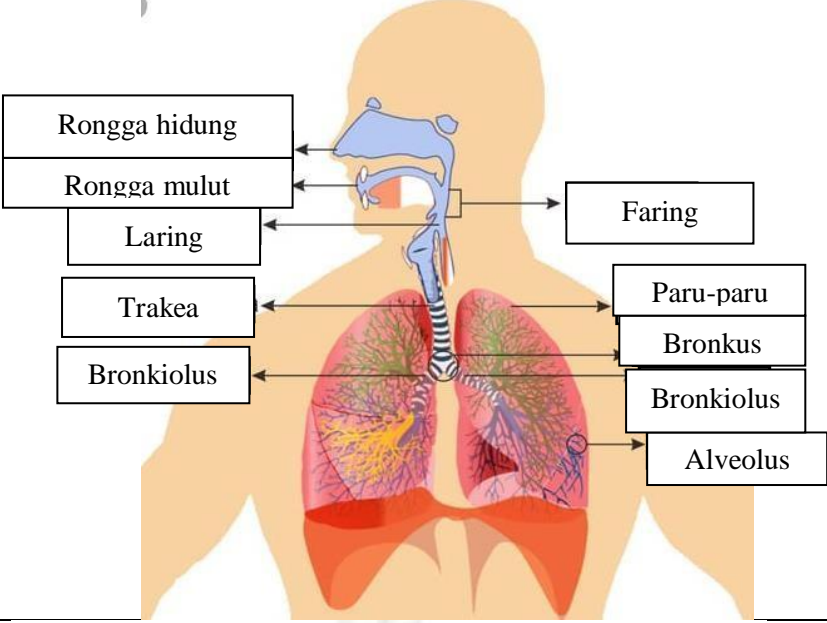
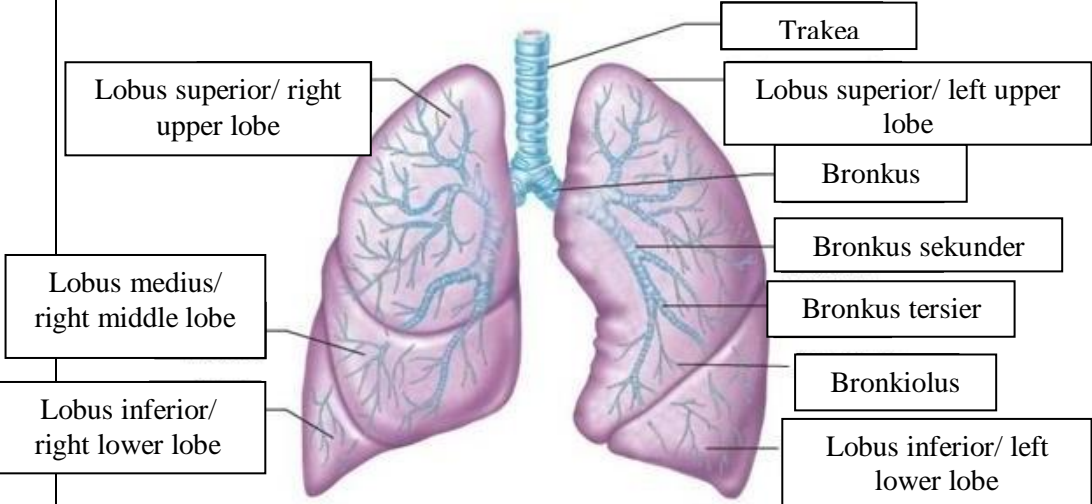
No	Keterangan	Pembahasan
1		
		



WORKSHEETS (LEMBAR KERJA)

Mata Kuliah	: Anatomi
Materi	: Anatomi Respirasi
NIM>Nama Mahasiswa	: 2110101110/Cici Liara Septi

No	Keterangan	Pembahasan
1	<p>Anatomical diagram of the human respiratory system showing the airway and lungs. The labels are as follows:</p> <ul style="list-style-type: none"> Faring Rongga hidung Epiglottis Trakea Bronkus Bronkiolus Lobus superior Bronkus Paru-paru Lobus inferior Diafragma 	

No	Keterangan	Pembahasan
		 <p>Diagram of the human respiratory system with the following labels:</p> <ul style="list-style-type: none"> Rongga hidung Rongga mulut Laring Trakea Bronkiolus Faring Paru-paru Bronkus Bronkiolus Alveolus
		 <p>Diagram of the lungs with the following labels:</p> <ul style="list-style-type: none"> Trakea Lobus superior/ right upper lobe Lobus superior/ left upper lobe Bronkus Bronkus sekunder Bronkus tersier Bronkiolus Lobus medius/ right middle lobe Lobus inferior/ right lower lobe Lobus inferior/ left lower lobe

