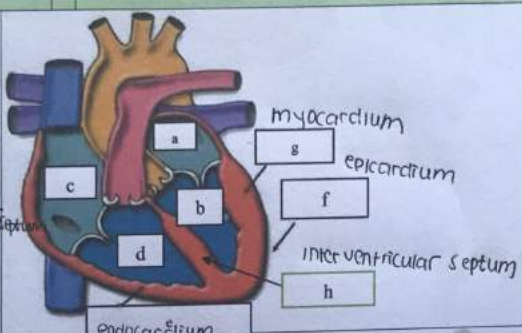
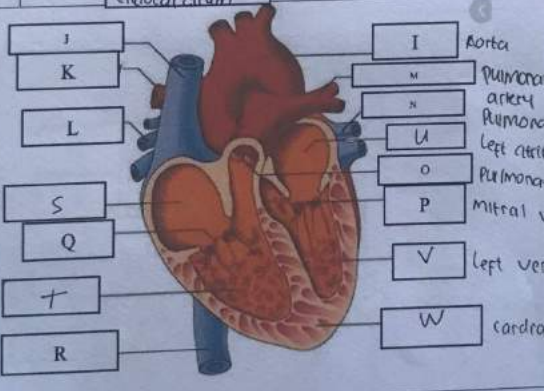


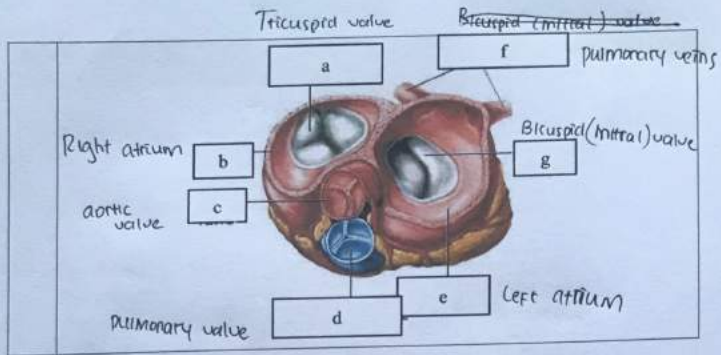
WORKSHEETS (LEMBAR KERJA)

Mata Kuliah	: Anatomi
Materi	: Anatomi Cardiovaskuler
NIM>Nama Mahasiswa	: Tiara Sinta A

No	Keterangan	Pembahasan
1	<p>a. Left atrium b. Left ventricle c. Right atrium d. Right ventricle e. Pericardium f. endocardium g. Interventricular septum h. myocardium i. epicardium</p>	 <p>myocardium epicardium Interventricular septum endocardium</p>
	<p>superior vena cava pulmonary artery pulmonary veins Right atrium Tricuspid valve Right ventricle Inferior vena cava</p>	 <p>J K L S Q T R I Aorta M Pulmonary artery N Pulmonary vein U Left atrium O Pulmonary valve P Mitral valve V Left ventricle W cardiac muscle</p>

- 1. Aorta
- J. superior vena cava
- K. pulmonary artery
- L. pulmonary veins
- M. pulmonary artery
- N. pulmonary veins
- O. pulmonary valve
- P. mitral valve
- Q. tricuspid valve

- R. Inferior vena cava
- S. Right atrium
- T. Right ventricle
- U. Left atrium
- V. Left ventricle
- W. Cardiac muscle.



WORKSHEETS (LEMBAR KERJA)

Mata Kuliah	: Anatomi
Materi	: Anatomi Respirasi
NIM>Nama Mahasiswa	: Tiara sinta A

No	Keterangan	Pembahasan
1	<p>Faring Laring Bronchus paru kanan pleura Diaphragma</p>	<p>a. Faring b. Rongga hidung c. Laring d. Trakea e. Bronchus f. Bronkiolus g. Bronkiolus h. pleura i. Diaphragma j. Paru-paru kanan k. " " " "</p> <p>Diaphragma.</p>

No	Keterangan	Pembahasan
----	------------	------------

