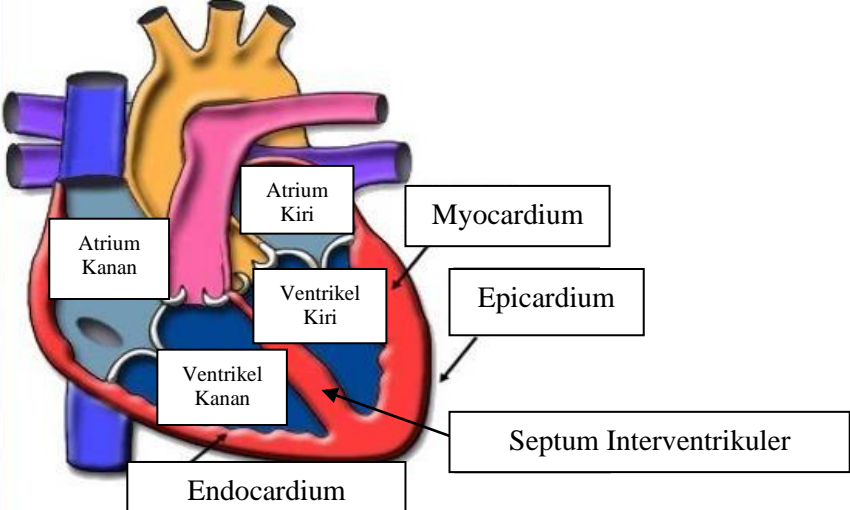
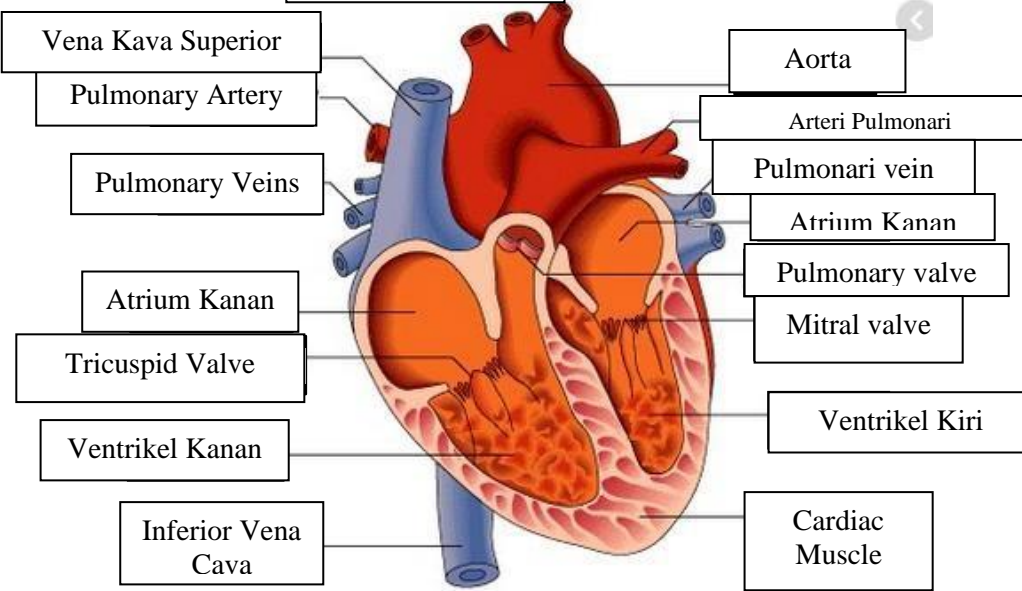
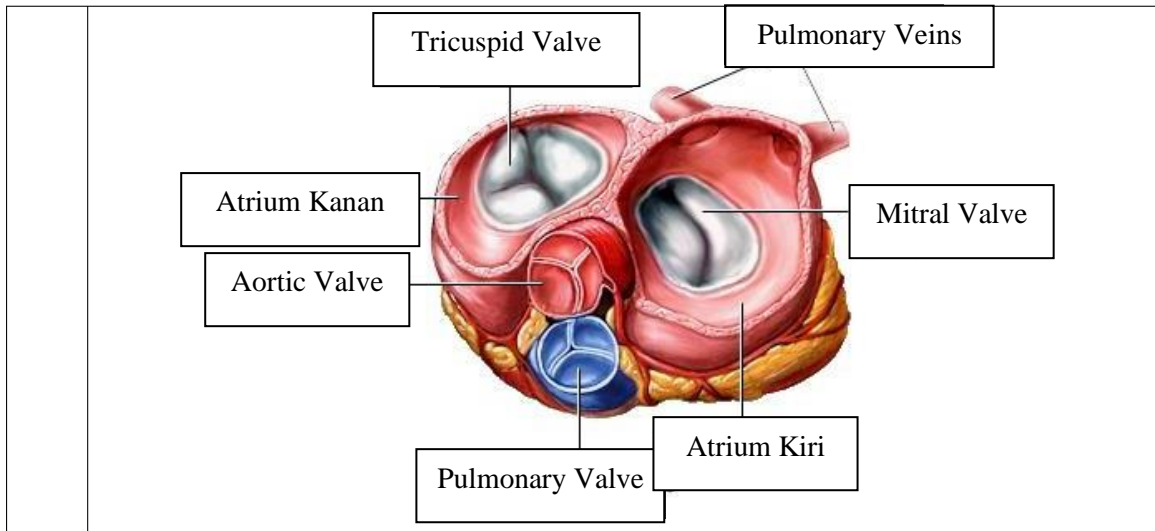


WORKSHEETS (LEMBAR KERJA)

| | |
|------------------------------|--|
| Mata Kuliah | : Anatomi |
| Materi | : Anatomi Cardiovaskuler |
| NIM>Nama Mahasiswa | : 2110101098/Renita Pramesti Ardita Putri |

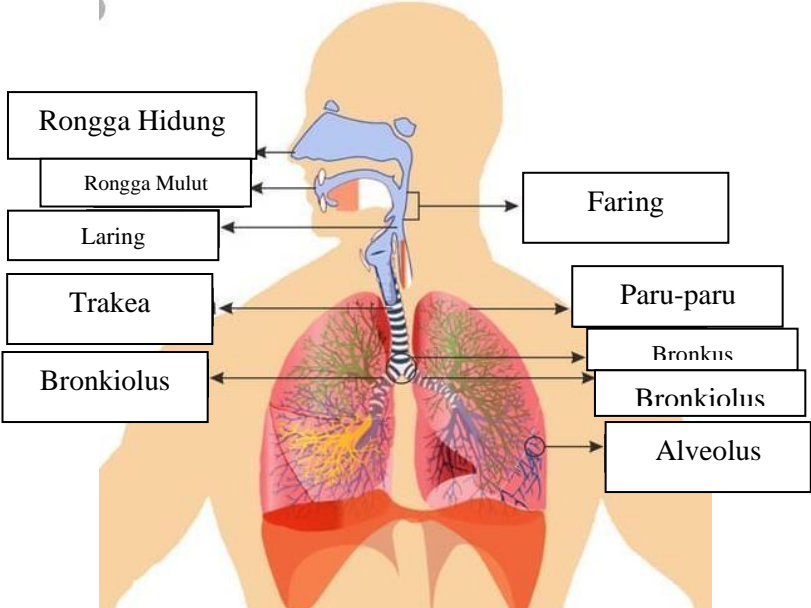
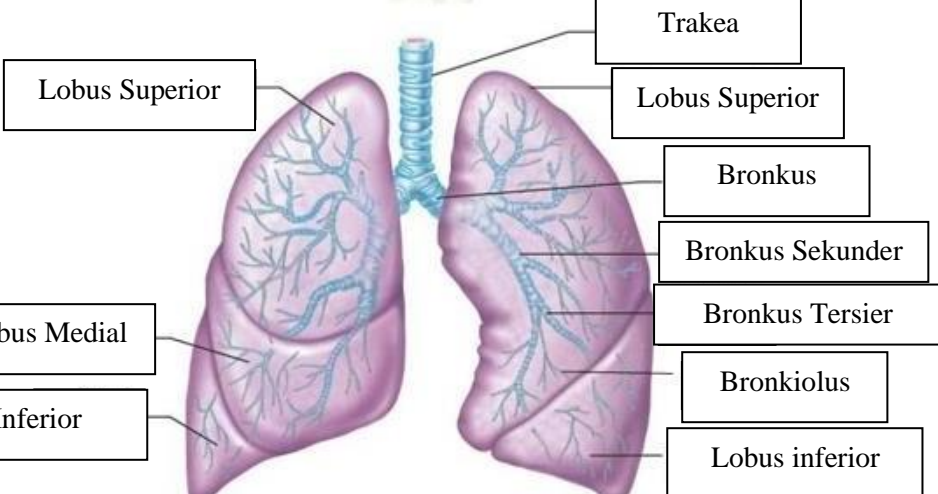
| No | Keterangan | Pembahasan |
|----|------------|--|
| 1 | |  <p>This diagram shows a cross-section of the heart wall. Labels include: Atrium Kiri (Left Atrium), Myocardium (middle layer of muscle), Epicardium (outer layer of muscle), Endocardium (inner layer of muscle), Ventrikel Kiri (Left Ventricle), Septum Interventrikuler (Septum Interventricular), Ventrikel Kanan (Right Ventricle), and Atrium Kanan (Right Atrium).</p> |
| | |  <p>This diagram shows the heart with its major vessels and valves. Labels include: Vena Kava Superior (Superior Vena Cava), Pulmonary Artery, Pulmonary Veins, Atrium Kanan (Right Atrium), Tricuspid Valve, Ventrikel Kanan (Right Ventricle), Inferior Vena Cava (Inferior Vena Cava), Aorta, Arteri Pulmonari (Pulmonary Artery), Pulmonari vein (Pulmonary Vein), Pulmonary valve, Mitral valve, Ventrikel Kiri (Left Ventricle), and Cardiac Muscle.</p> |



WORKSHEETS (LEMBAR KERJA)

| | |
|------------------------------|---------------------|
| Mata Kuliah | : Anatomi |
| Materi | : Anatomi Respirasi |
| NIM>Nama Mahasiswa | : 2110101098 |

| No | Keterangan | Pembahasan |
|----|--|------------|
| 1 | <p>An anatomical diagram of the human respiratory system. It shows the nasal cavity (Rongga Hidung), pharynx (Faring), larynx (Laring), trachea (Trakea), bronchi (Bronkus), bronchioles (Bronkiolus), and the right (Paru-paru Kanan) and left (Paru-paru Kiri) lungs. The pleura (Pleura) is shown surrounding the lungs, and the diaphragm (Diafragma) is at the base. The diagram is color-coded to show the airway structure.</p> | |

| No | Keterangan | Pembahasan |
|----|------------|---|
| | |  <p>Diagram of the human respiratory system with labels:</p> <ul style="list-style-type: none"> Rongga Hidung Rongga Mulut Laring Trakea Bronkiolus Faring Paru-paru Bronkus Bronkiolus Alveolus |
| | |  <p>Diagram of the lungs with labels:</p> <ul style="list-style-type: none"> Lobus Superior Lobus Medial Lobus Inferior Trakea Lobus Superior Bronkus Bronkus Sekunder Bronkus Tersier Bronkiolus Lobus inferior |

