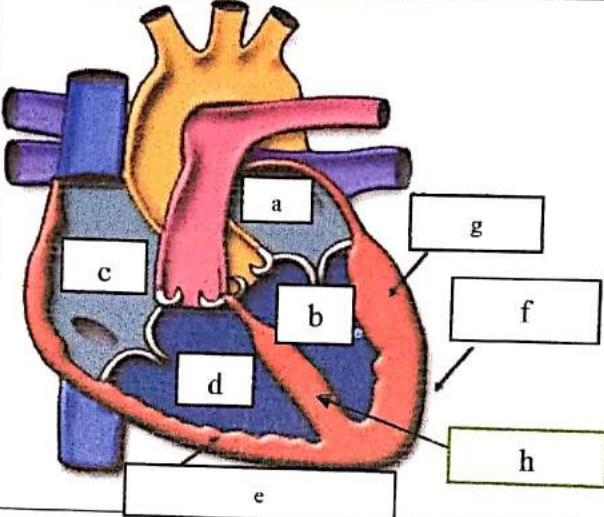
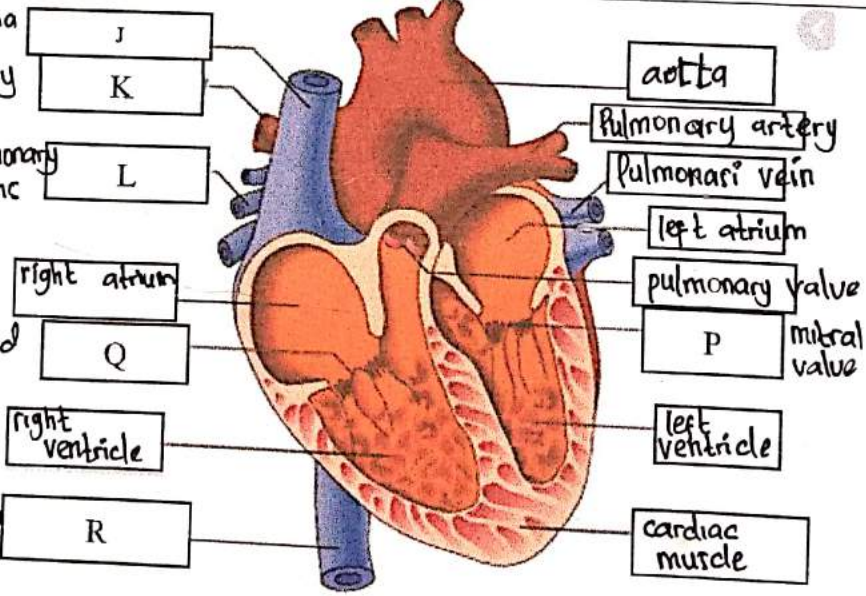
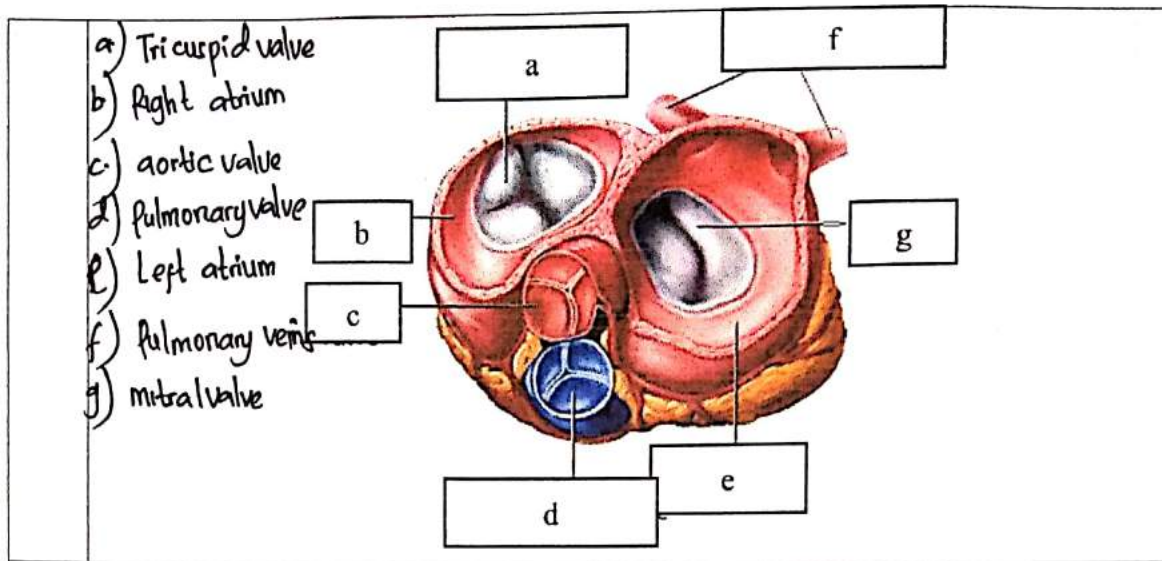


**WORKSHEETS (LEMBAR KERJA)**

Mata Kuliah	: Anatomi
Materi	: Anatomi Cardiovaskuler
NIM>Nama Mahasiswa	: 2110101095 / Raisa Dwi Nur Vika

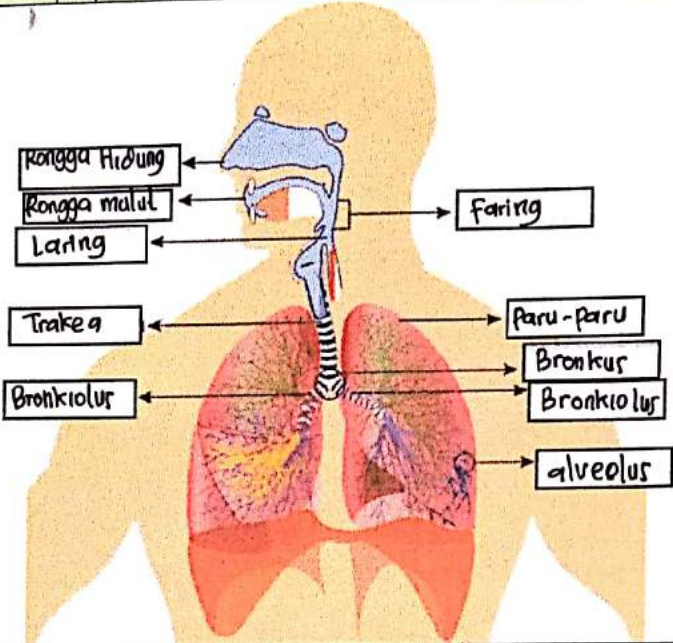
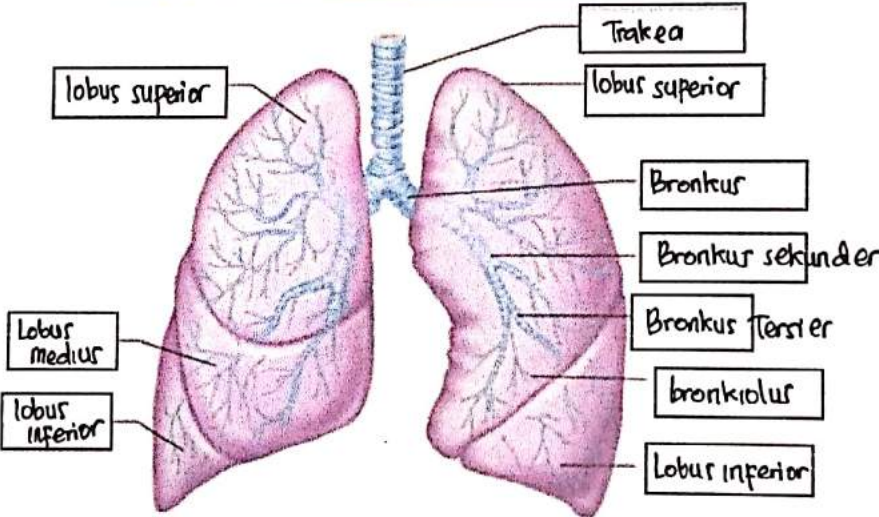
No	Keterangan	Pembahasan
1		 <p>a) Left atrium                  b) Left ventricle                  c) Right Atrium                  d) Right Ventricle                  e) Endocardium                  f) Epicardium                  g) Myocardium                  h) Interventricular septum</p>
	<p>J) superior vena cava</p> <p>K) Pulmonary artery</p> <p>L) Pulmonary vein</p> <p>Q) tricuspid valve</p> <p>R) inferior vena cava</p>	 <p>aorta</p> <p>Pulmonary artery</p> <p>Pulmonary vein</p> <p>left atrium</p> <p>pulmonary valve</p> <p>mitral valve</p> <p>left ventricle</p> <p>cardiac muscle</p> <p>right atrium</p> <p>right ventricle</p>



**WORKSHEETS (LEMBAR KERJA)**

Mata Kuliah	: Anatomi
Materi	: Anatomi Respirasi
NIM>Nama Mahasiswa	:

No	Keterangan	Pembahasan
1	<ul style="list-style-type: none"> <li>a) Faring</li> <li>b) Rongga hidung</li> <li>c) Laring</li> <li>d) Trakea</li> <li>e) Bronkus</li> <li>f) Bronkiolus</li> <li>g) Bronkus</li> <li>h) Pleura</li> <li>i) Diafragma</li> </ul>	

No	Keterangan	Pembahasan
		 <p>Diagram of the human respiratory system with the following labels:</p> <ul style="list-style-type: none"> <li>Kongga Hidung</li> <li>Kongga mulut</li> <li>Laring</li> <li>Trakea</li> <li>Bronkiolus</li> <li>Faring</li> <li>Paru-paru</li> <li>Bronkus</li> <li>Bronkiolus</li> <li>alveolus</li> </ul>
		 <p>Detailed diagram of the lungs with the following labels:</p> <ul style="list-style-type: none"> <li>lobus superior</li> <li>lobus medius</li> <li>lobus inferior</li> <li>Trakea</li> <li>lobus superior</li> <li>Bronkus</li> <li>Bronkus sekunder</li> <li>Bronkus Tersier</li> <li>bronkiolus</li> <li>Lobus inferior</li> </ul>