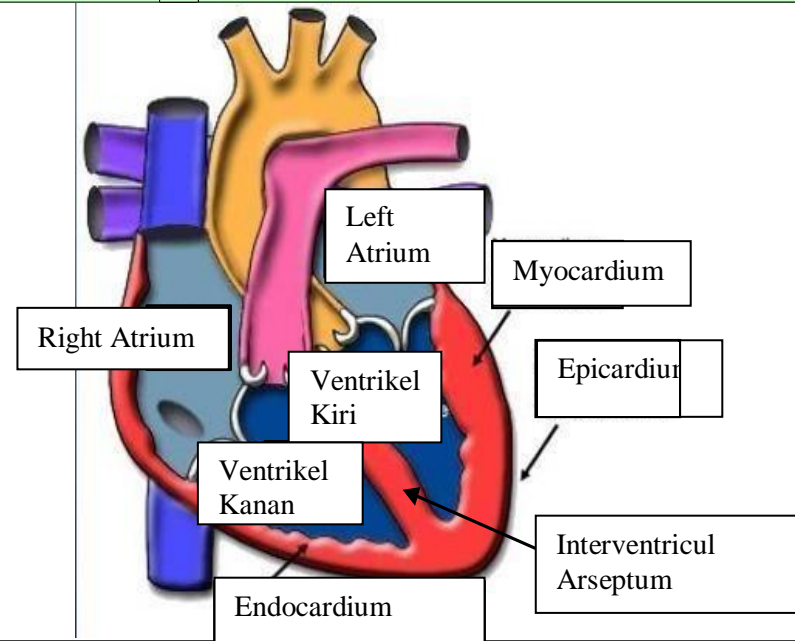
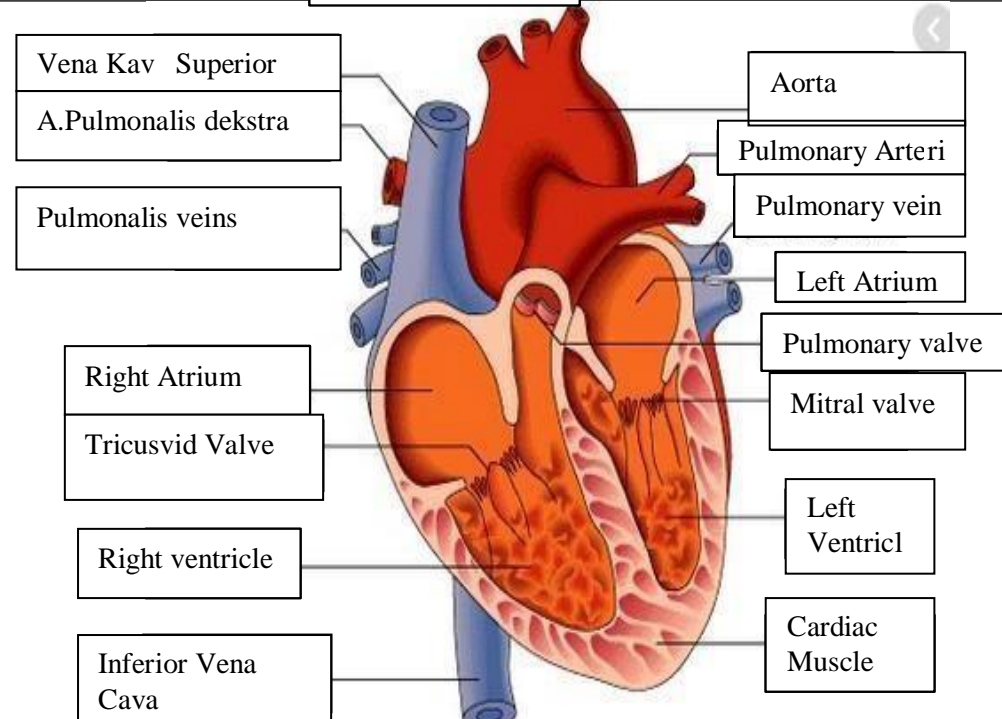
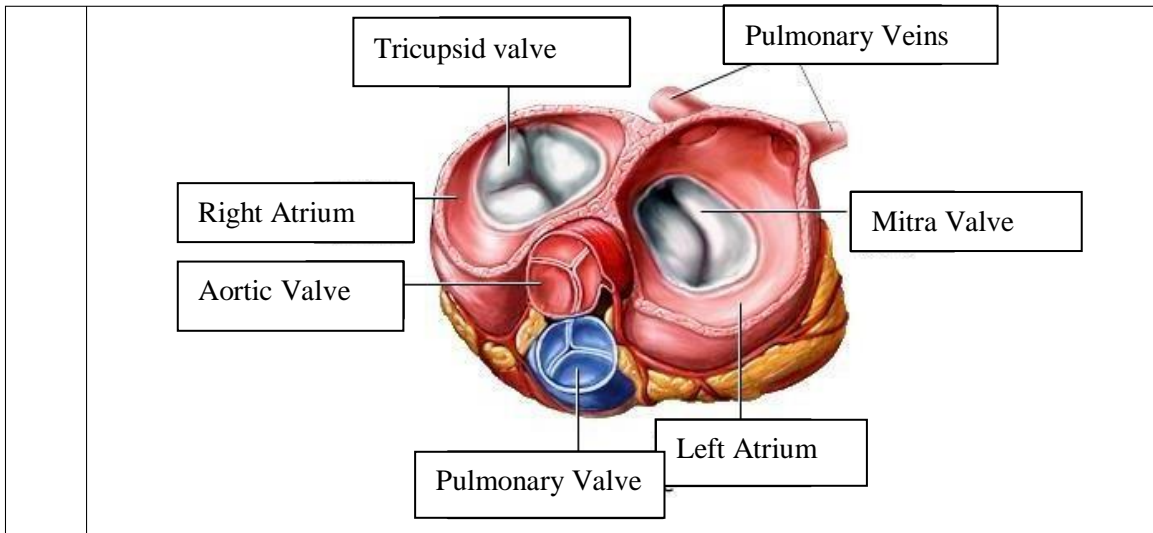


WORKSHEETS (LEMBAR KERJA)

| | |
|---------------------------|--------------------------------------|
| Mata Kuliah | : Anatomi |
| Materi | : Anatomi Cardiovaskuler |
| NIM/Nama Mahasiswa | : 2110101103_ALFINA FEBRIYANI |

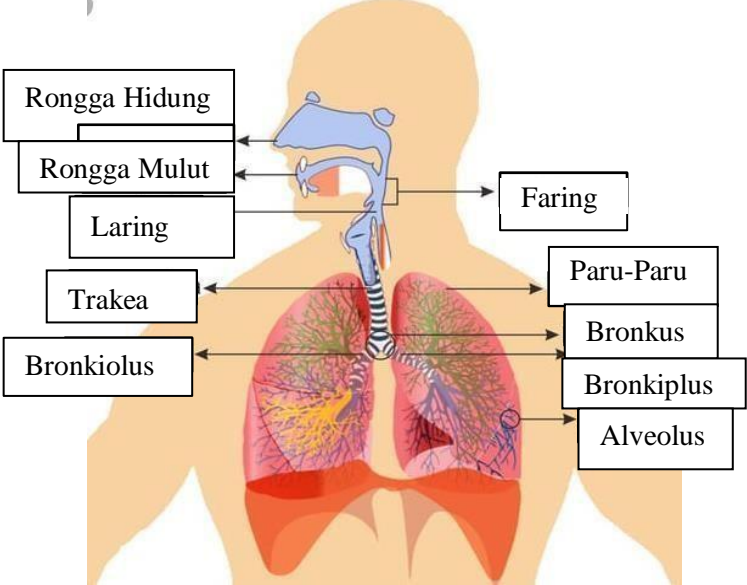
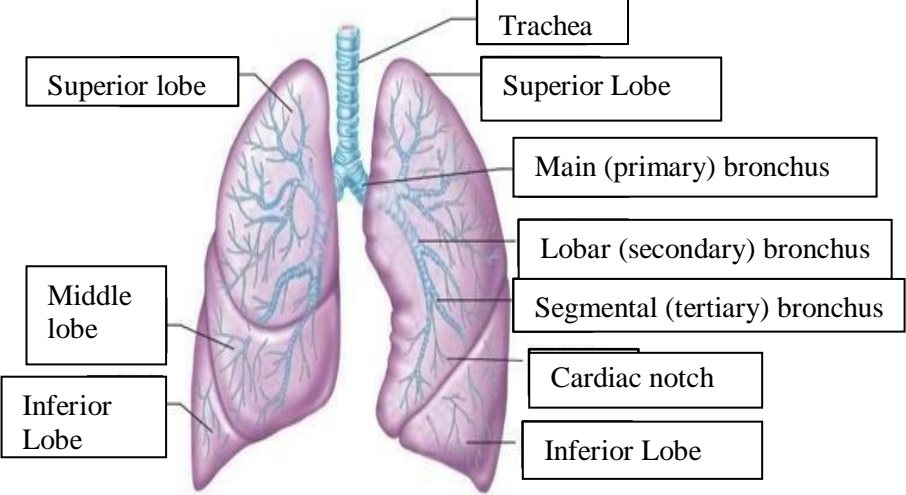
| No | Keterangan | Pembahasan |
|----|---|--|
| 1 | |  <p>Labels in diagram:</p> <ul style="list-style-type: none"> Left Atrium Myocardium Right Atrium Ventrikel Kiri Epicardium Ventrikel Kanan Interventricul Arseptum Endocardium |
| | <ul style="list-style-type: none"> Vena Kav Superior A.Pulmonalis dekstra Pulmonalis veins Right Atrium Tricusvid Valve Right ventricle Inferior Vena Cava |  <p>Labels in diagram:</p> <ul style="list-style-type: none"> Aorta Pulmonary Arteri Pulmonary vein Left Atrium Pulmonary valve Mitral valve Left Ventricl Cardiac Muscle |



WORKSHEETS (LEMBAR KERJA)

| | |
|------------------------------|--------------------------------------|
| Mata Kuliah | : Anatomi |
| Materi | : Anatomi Respirasi |
| NIM>Nama Mahasiswa | : 2110101067/Mellynda Fortius |

| No | Keterangan | Pembahasan |
|----|--|------------|
| 1 | <p>Pharynx</p> <p>Esophagus</p> <p>Bronkus</p> <p>Paru Paru Kanan</p> <p>Pleura</p> <p>Nasal Cavity</p> <p>Traches</p> <p>Bronkiolus</p> <p>Bronkus</p> <p>Paru-Paru Kiri</p> <p>Diafragma</p> | |

| No | Keterangan | Pembahasan |
|----|------------|--|
| | |  <p>Diagram of the human respiratory system with labels: Rongga Hidung, Rongga Mulut, Laring, Trakea, Bronkiolus, Faring, Paru-Paru, Bronkus, Bronkiplus, Alveolus.</p> |
| | |  <p>Detailed diagram of the lungs with labels: Superior lobe, Middle lobe, Inferior Lobe, Trachea, Superior Lobe, Main (primary) bronchus, Lobar (secondary) bronchus, Segmental (tertiary) bronchus, Cardiac notch, Inferior Lobe.</p> |

