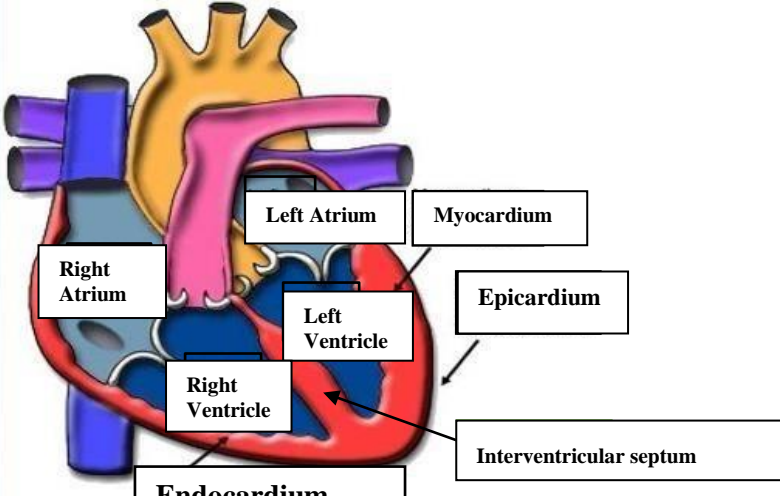
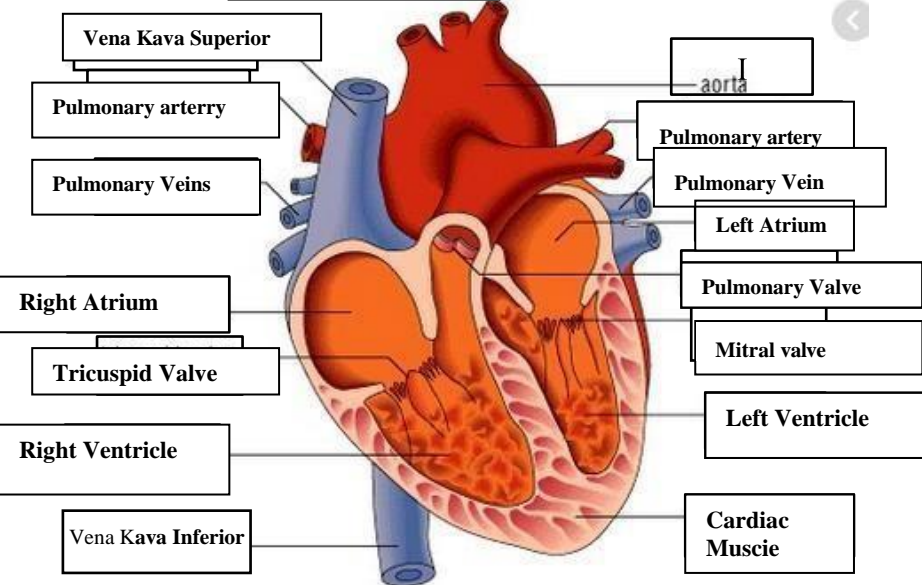
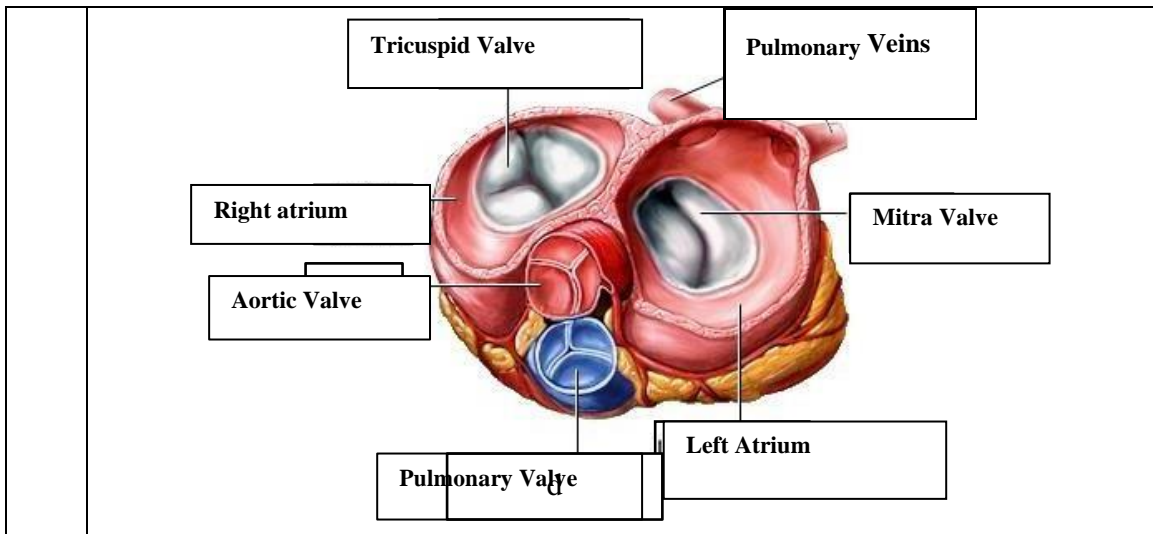


WORKSHEETS (LEMBAR KERJA)

Mata Kuliah	: Anatomi
Materi	: Anatomi Cardiovaskuler
NIM>Nama Mahasiswa	: 2110101077 / PUTRI ANGGRAINI

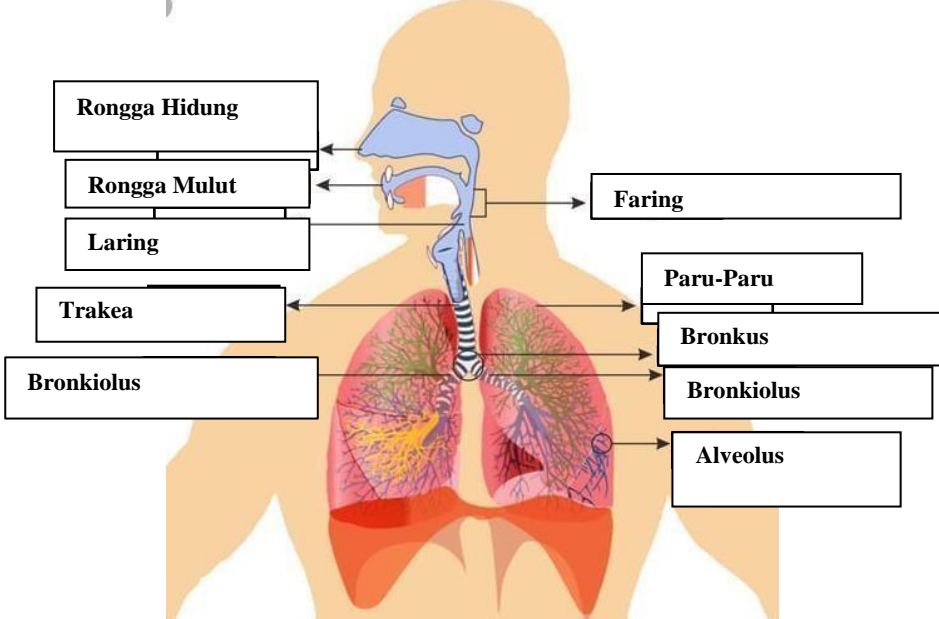
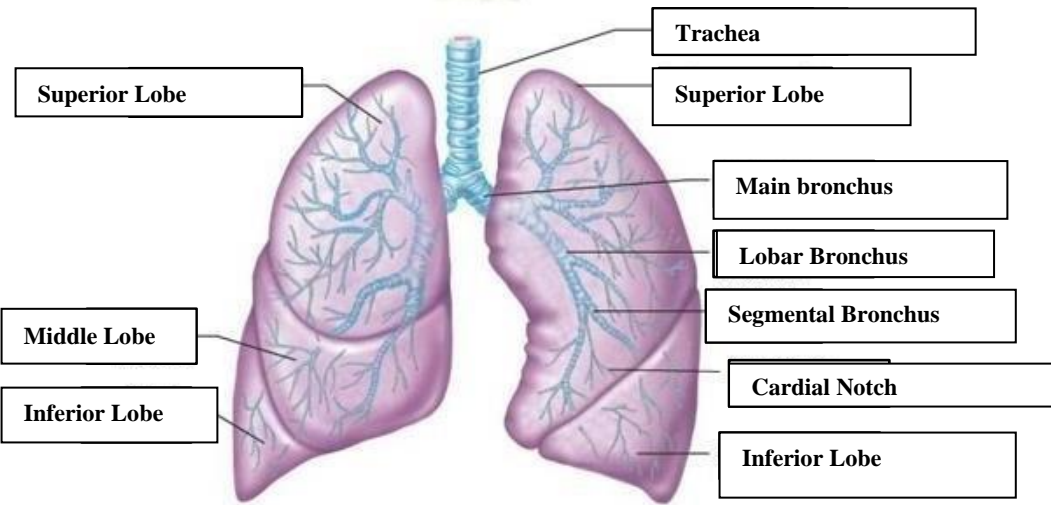
No	Keterangan	Pembahasan
1		
		



WORKSHEETS (LEMBAR KERJA)

Mata Kuliah	: Anatomi
Materi	: Anatomi Respirasi
NIM>Nama Mahasiswa	: 2110101077/ PUTRI ANGGRAINI

No	Keterangan	Pembahasan
1	<p>An anatomical diagram of the human respiratory system. Labels with leader lines point to the following parts: Faring (throat), Laring (voice box), Bronkus (main bronchi), Paru-Paru kanan (right lung), Pleura (lung lining), Diafragma (diaphragm), Rongga Hidung (nasal cavity), Trakea (trachea), Bronkiolus (bronchioles), Bronkus (secondary bronchi), and Paru-Paru kiri (left lung).</p>	

No	Keterangan	Pembahasan
		 <p>Diagram of the human respiratory system with labels:</p> <ul style="list-style-type: none"> Rongga Hidung Rongga Mulut Laring Trakea Bronkiolus Faring Paru-Paru Bronkus Bronkiolus Alveolus
		 <p>Diagram of the lungs with labels:</p> <ul style="list-style-type: none"> Superior Lobe Middle Lobe Inferior Lobe Trachea Superior Lobe Main bronchus Lobar Bronchus Segmental Bronchus Cardial Notch Inferior Lobe

