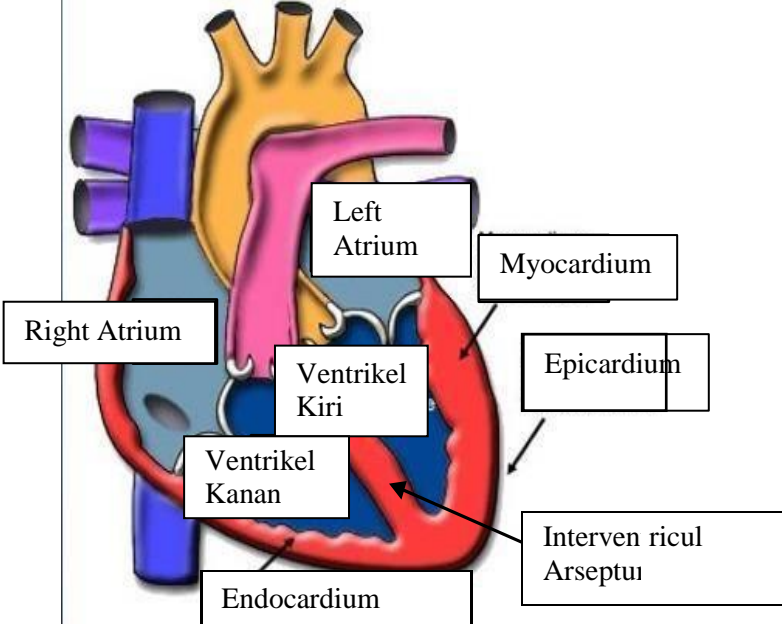
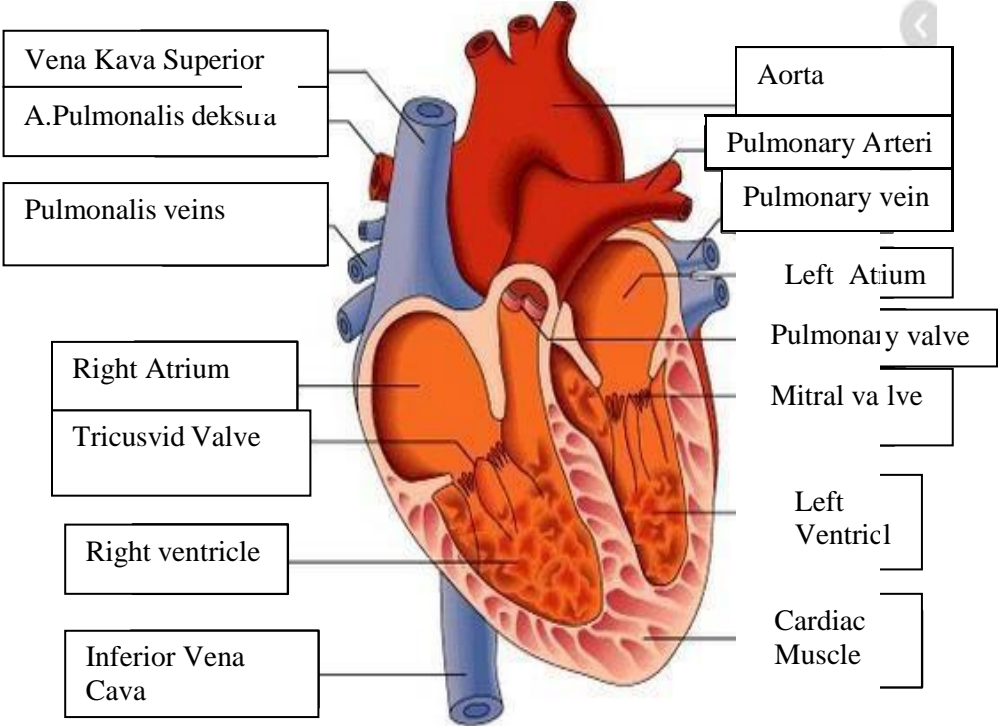
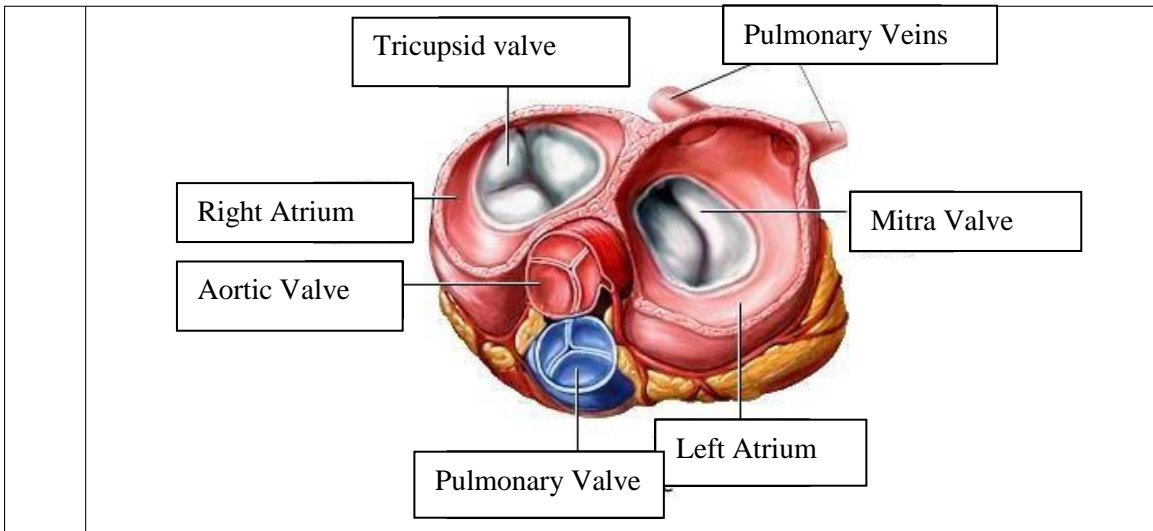


WORKSHEETS (LEMBAR KERJA)

Mata Kuliah	: Anatomi
Materi	: Anatomi Cardiovaskuler
NIM/Nama Mahasiswa	: 2110101068/Irna Rara Junika

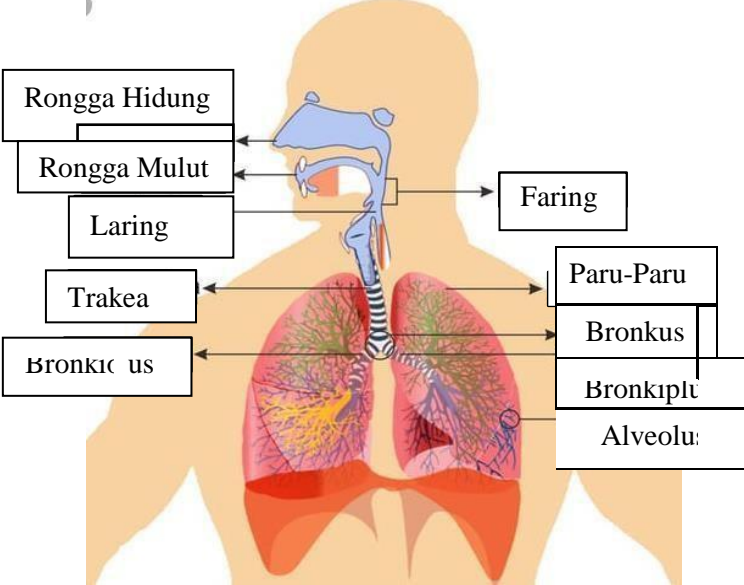
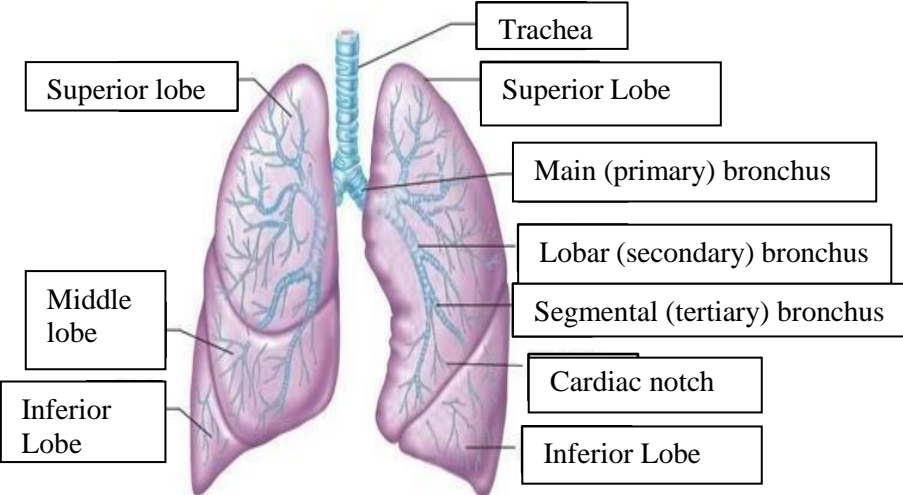
No	Keterangan	Pembahasan
1		 <p>Labels in diagram:</p> <ul style="list-style-type: none"> Left Atrium Myocardium Right Atrium Ventrikel Kiri Epicardium Ventrikel Kanan Interven ricul Arseptu Endocardium
	<p>Vena Kava Superior</p> <p>A.Pulmonalis deksua</p> <p>Pulmonalis veins</p> <p>Right Atrium</p> <p>Tricusvid Valve</p> <p>Right ventricle</p> <p>Inferior Vena Cava</p>	 <p>Labels in diagram:</p> <ul style="list-style-type: none"> Aorta Pulmonary Arteri Pulmonary vein Left Atium Pulmonary valve Mitral valve Left Ventricl Cardiac Muscle



WORKSHEETS (LEMBAR KERJA)

Mata Kuliah	: Anatomi
Materi	: Anatomi Respirasi
NIM>Nama Mahasiswa	: 2110101067/Mellynda Fortius

No	Keterangan	Pembahasan
1	<p>An anatomical diagram of the human respiratory system. It shows the nasal cavity leading to the pharynx, which then branches into the trachea (windpipe) and bronchi (bronchus). The bronchi further divide into bronchioles and finally into the alveoli of the right and left lungs (paru-paru kanan and paru-paru kiri). The lungs are surrounded by the pleura. The diaphragm is shown at the base of the thoracic cavity. Labels with leader lines point to each of these structures.</p>	

No	Keterangan	Pembahasan
		 <p>Diagram of the human respiratory system with labels:</p> <ul style="list-style-type: none"> Rongga Hidung Rongga Mulut Laring Trakea Bronki us Faring Paru-Paru Bronkus Bronkiptu Alveolu
		 <p>Detailed diagram of the lungs with labels:</p> <ul style="list-style-type: none"> Superior lobe Middle lobe Inferior Lobe Trachea Superior Lobe Main (primary) bronchus Lobar (secondary) bronchus Segmental (tertiary) bronchus Cardiac notch Inferior Lobe

