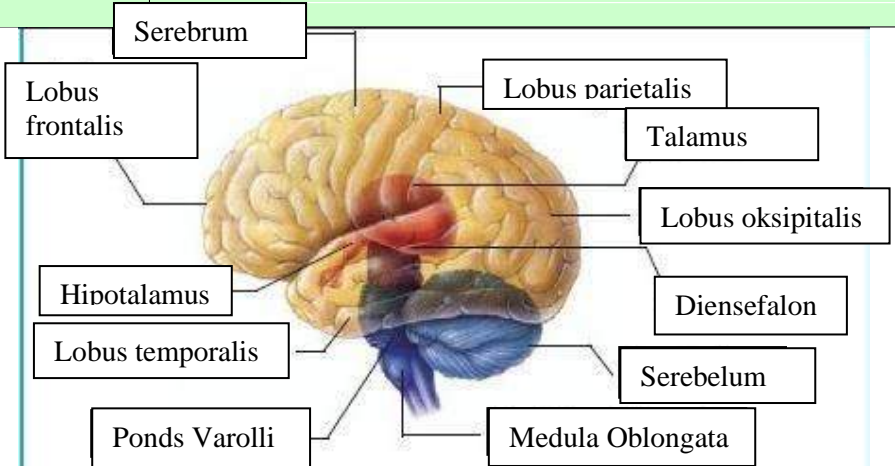
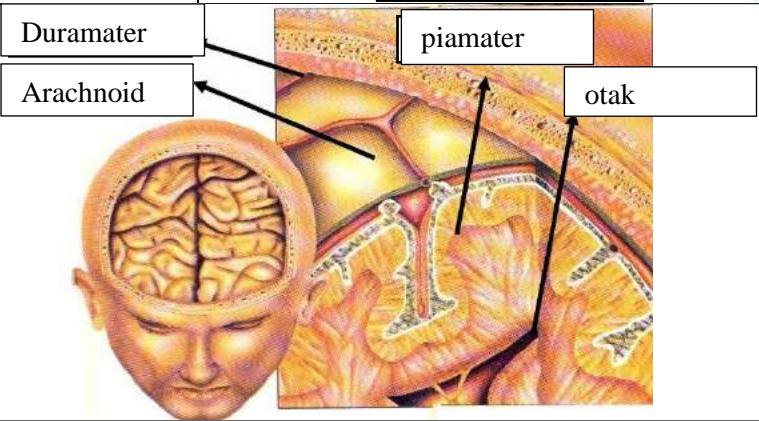
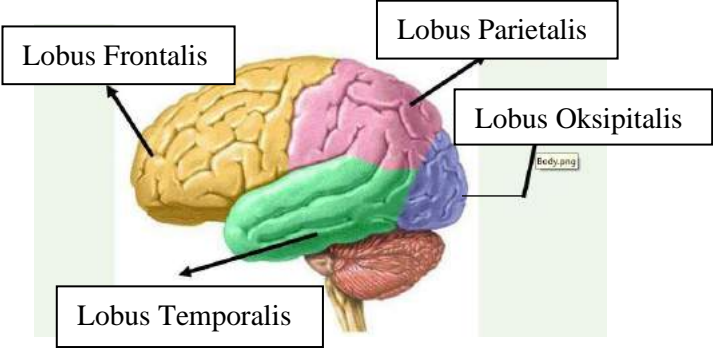
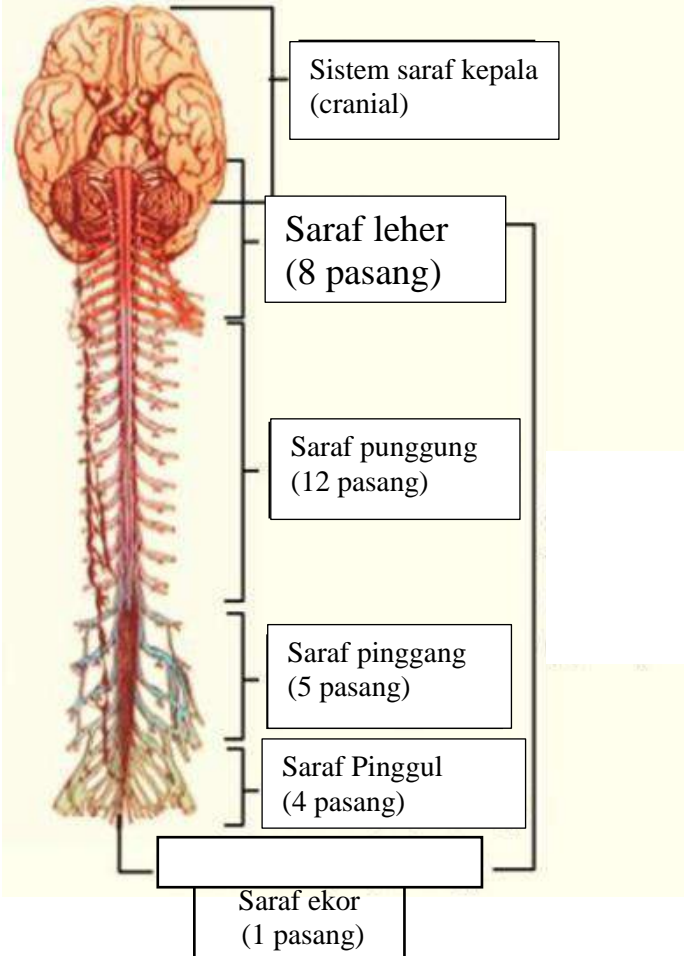


WORKSHEETS (LEMBAR KERJA)

Mata Kuliah	: Anatomi
Materi	: Anatomi Syaraf
NIM>Nama Mahasiswa	: 2110101134/ Aisyah Mutiara Agustin

No	Keterangan	Pembahasan
1	Pembagian sistem syaraf : a) Susunan syaraf pusat b) Susunan syaraf perifer	<div style="border: 1px solid black; padding: 5px; margin-bottom: 5px;"> Susunan saraf pusat terdiri dari otak dan sumsum tulang belakang. </div> <div style="border: 1px solid black; padding: 5px;"> sistem saraf tepi terdiri dari sistem saraf somatik dan otonom </div>
	Sebutkan 2 jenis sel pembangun sistem persyarafan 2 jenis sel pembangun sistem persyarafan yaitu neuron dan sel glia	<div style="border: 1px solid black; width: 100px; height: 20px; margin: 0 auto;"></div> <p>The diagram shows a multipolar neuron. On the left, there are several branching structures labeled 'Dendrit'. The main body of the neuron is labeled 'Tubuh cell' and contains a green nucleus labeled 'Nukleus'. A long 'Axon' extends from the cell body, covered by a 'Myelin sheath' composed of 'Schwann cell' segments. Gaps in the sheath are labeled 'Node of Ranvier'. The axon ends in branching structures labeled 'Axon Terminal'.</p>
	Otak terdiri dari Otak besar (Cerebrum), Otak kecil (Cerebellum), Batang otak, dan sistem limbik. 4 lobus pada cerebrum adalah Lobus frontal, Lobus oksipital, lobus temporal, dan Lobus parietal.	

No	Keterangan	Pembahasan
		
		
	Lobus otak	

No	Keterangan	Pembahasan
	 <p>The diagram illustrates the human nervous system, showing the brain at the top and the spinal cord extending downwards. Brackets on the right side of the diagram group the nerves into six categories, each with a corresponding text box:</p> <ul style="list-style-type: none"> Sistem saraf kepala (cranial): Located at the top, connected to the brain. Saraf leher (8 pasang): Eight pairs of nerves branching from the cervical region of the spinal cord. Saraf punggung (12 pasang): Twelve pairs of nerves branching from the thoracic region of the spinal cord. Saraf pinggang (5 pasang): Five pairs of nerves branching from the lumbar region of the spinal cord. Saraf Pinggul (4 pasang): Four pairs of nerves branching from the sacral region of the spinal cord. Saraf ekor (1 pasang): A single pair of nerves at the very bottom of the spinal cord. 	