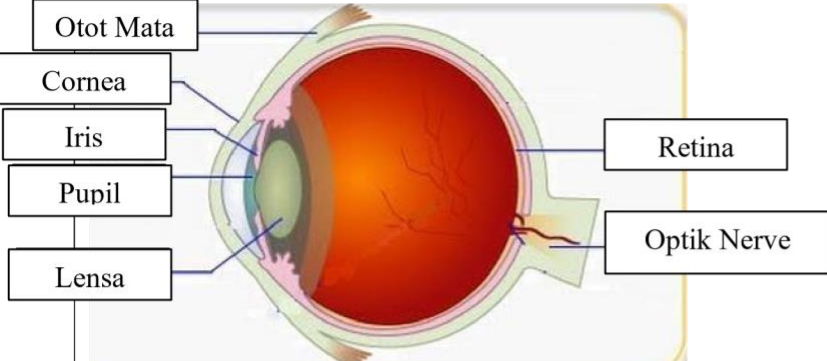
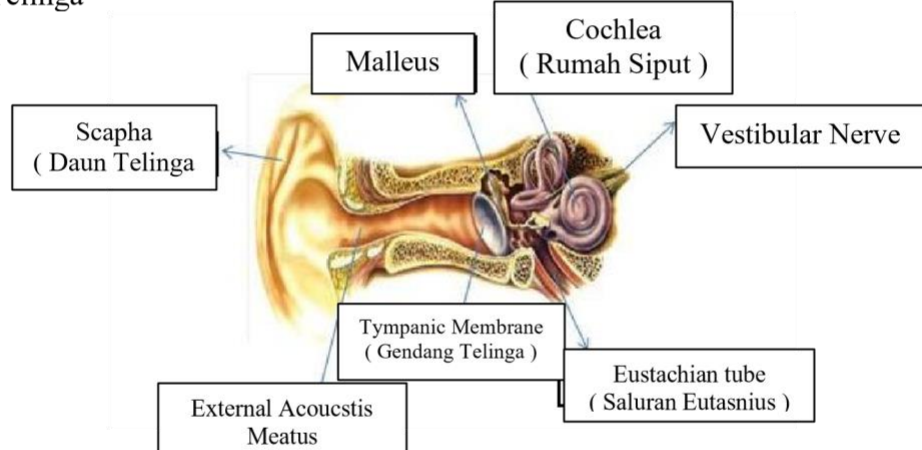
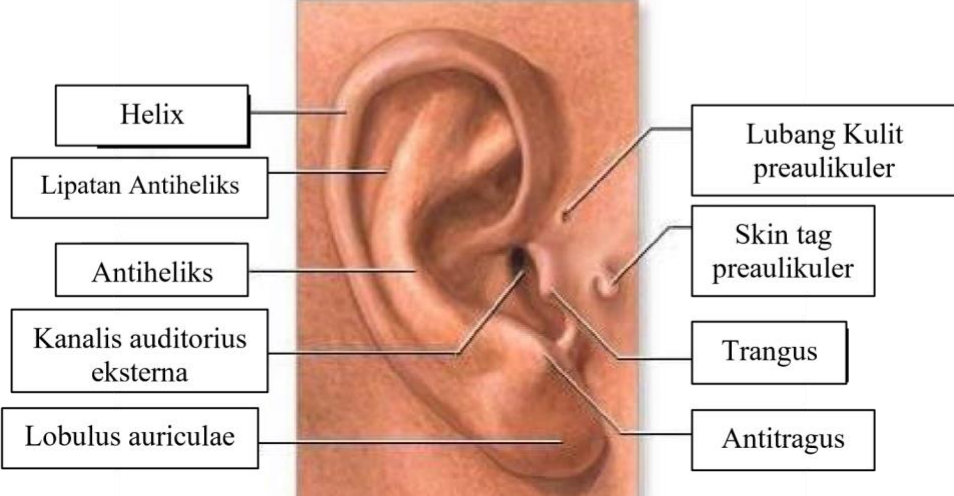
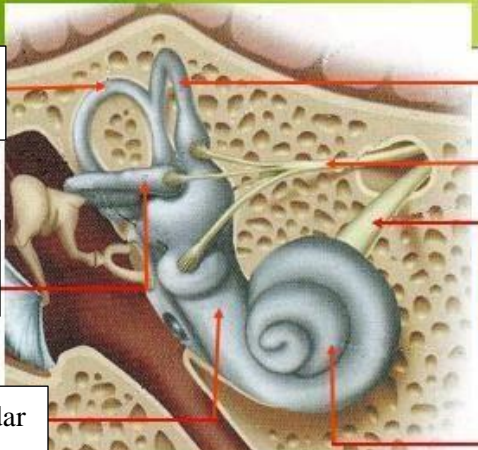
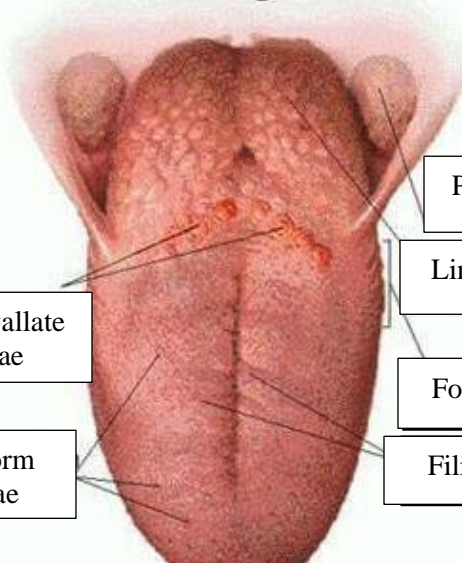


WORKSHEETS (LEMBAR KERJA)

Mata Kuliah	: Anatomi
Materi	: Anatomi Panca Indra
NIM>Nama Mahasiswa	: 2110101018/Heni Indriani

No	Keterangan	Pembahasan
1	<p>Mata</p> 	
	<p>Telinga</p> 	
		

No	Keterangan	Pembahasan
	<p>Semicircular canals</p> <p>Vestibular complex</p> <p>Tingkap bundar</p>	 <p>Semicircles cluct within anterios semicor</p> <p>Vestbular branch (Malicus, incus, and stapes)</p> <p>Cochlear branch</p> <p>Cochlea</p>
	<p>Circumvallate papilae</p> <p>Fungiform Papillae</p>	 <p>Palatine Tonsil</p> <p>Lingual Tonsil</p> <p>Foliate papilae</p> <p>Filiform papillae</p>