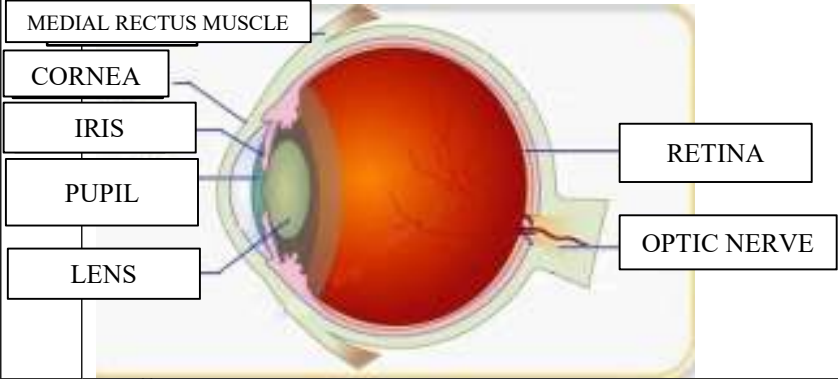
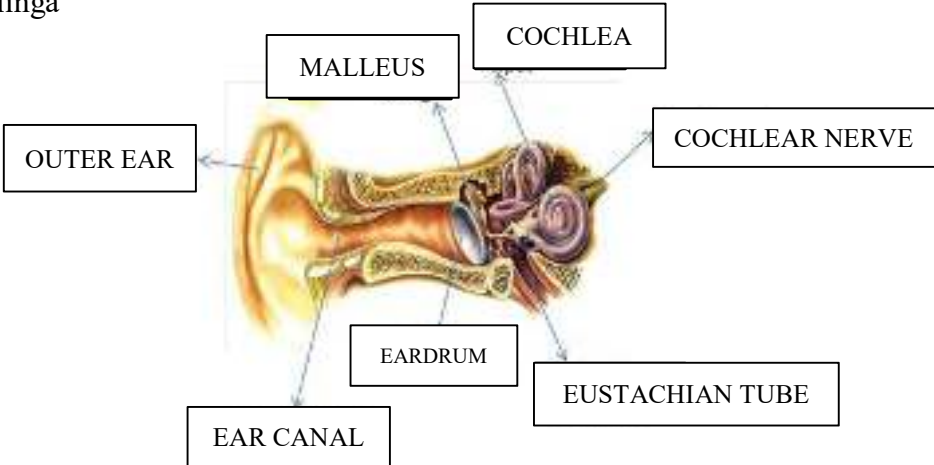
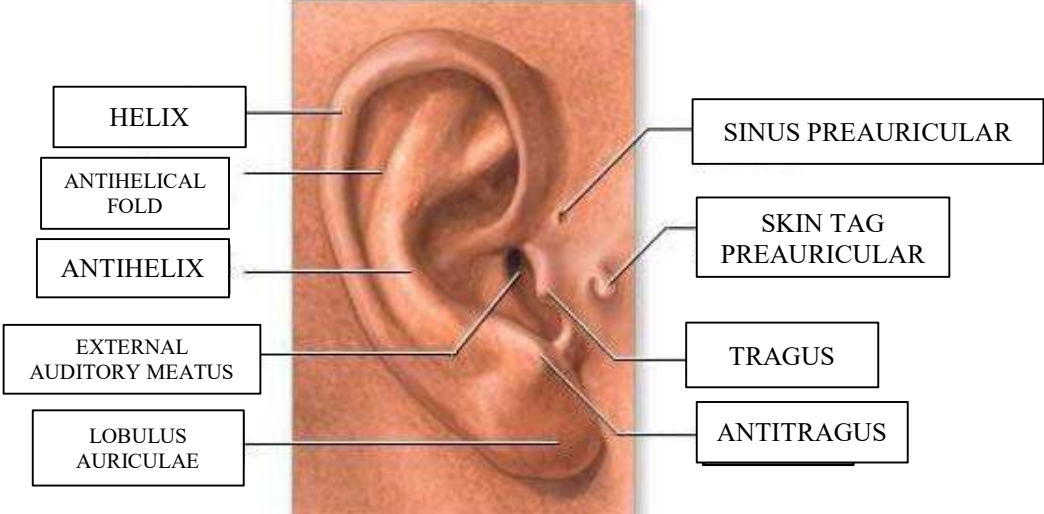

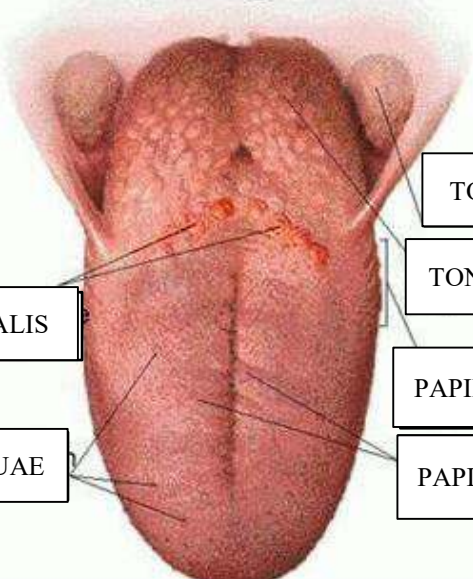


**WORKSHEETS (LEMBAR KERJA)**

<b>Mata Kuliah</b>	: <b>Anatomi</b>
<b>Materi</b>	: <b>Anatomi Panca Indra</b>
<b>NIM&gt;Nama Mahasiswa</b>	: <b>2110101024/INTAN LAROIBA KHURIJATI HAJID.</b>

No	Keterangan	Pembahasan
1	Mata	
	Telinga	
		

No	Keterangan	Pembahasan
	<p>SEMICIRCULAR CANALS</p> <p>CRISTAE WITHIN AMPULLAE</p> <p>VESTIBULAR COMPLEX</p>	 <p>ANTERIOR</p> <p>VESTIBULAR NERVE</p> <p>COCHLEAR NERVE</p> <p>COCHLEA</p>
	<p>SULCUS TERMINALIS</p> <p>DORSUM LINGUAE</p>	 <p>TONSILA PALATINA</p> <p>TONSILA LINGUALIS</p> <p>PAPILA FILIFORMIS</p> <p>PAPILA FUNGIFORMIS</p>