

WORKSHEETS (LEMBAR KERJA)

Mata Kuliah	: Anatomi
Materi	: Anatomi Panca Indra
NIM>Nama Mahasiswa	: 2110101022 / AFIKA SELMA.S.

No	Keterangan	Pembahasan
----	------------	------------

1 Mata

Labels on the left side of the eye diagram: OTOT, Kornea, Iris, Pupil, Lensa.

Labels on the right side of the eye diagram: Retina, Saraf Optik.


Telinga

Labels: Daun Telinga, Tulang Telinga, Rumah Siput, Saraf ke otak, Gendang Telinga, Saluran eustachius, Lubang Telinga.

Labels on the left side of the ear diagram: Helix, Lipatan anti heliks, Anti heliks, Kanal Auditorio externa, Lobulus.

Labels on the right side of the ear diagram: Lubang kulkul preaurikuler, Skinfold preaurikuler, Tragus, Antitragus.

No	Keterangan	Pembahasan
----	------------	------------



Semicircular Canals

Vestibular Complex

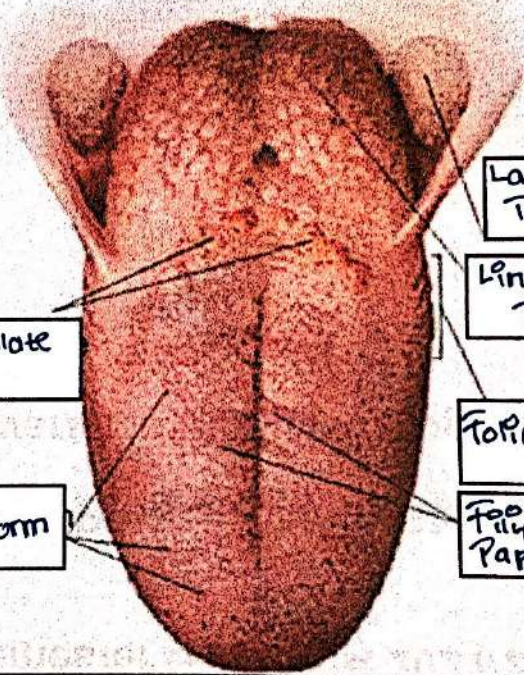
Tingkap Bundar

Semicircular duct within anterior semicor

1. Malleus
2. Incus
3. Stapes

Saraf Koles

Konker (rumah sipit)



Circumvallate papilla

Papili fungiform

Langit-Langit Tenggorokan

Lingual Tongsi

Foliate Papillae

Filiform Papillae