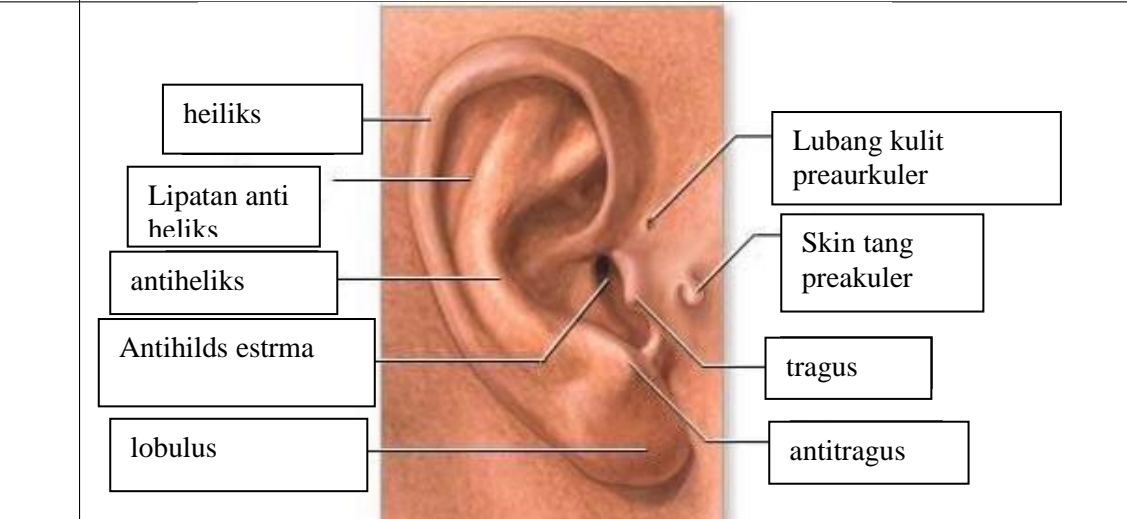
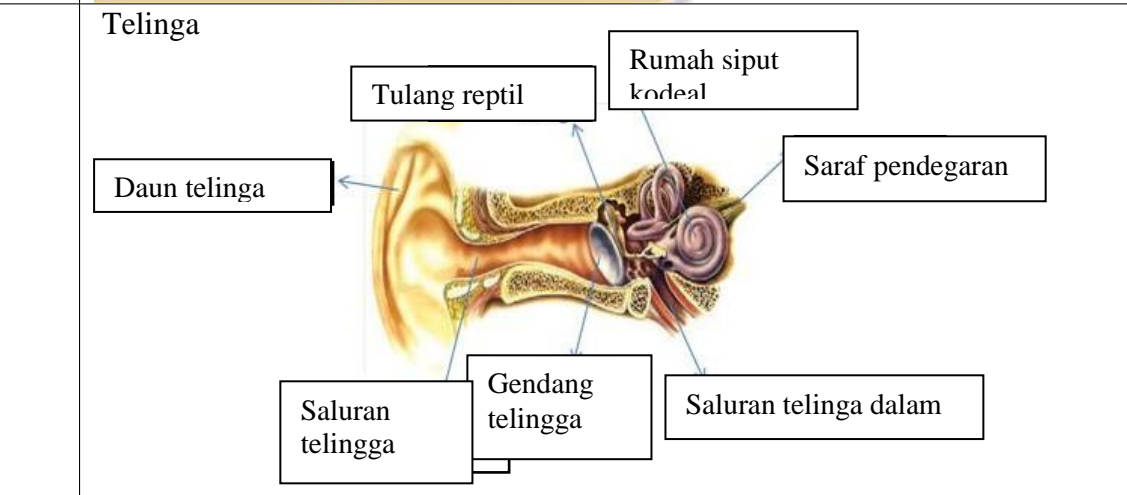
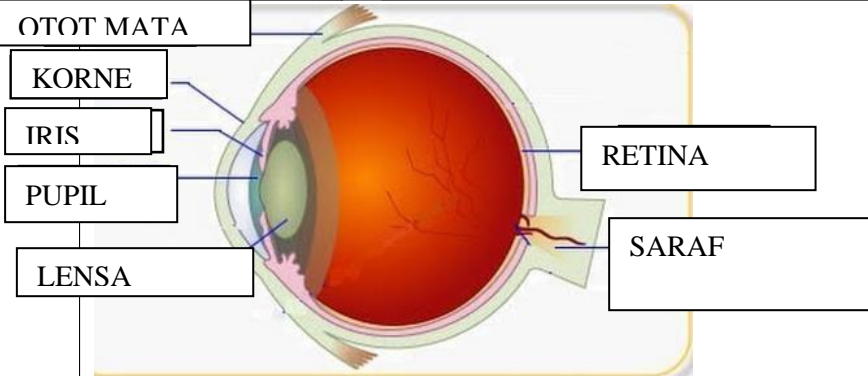

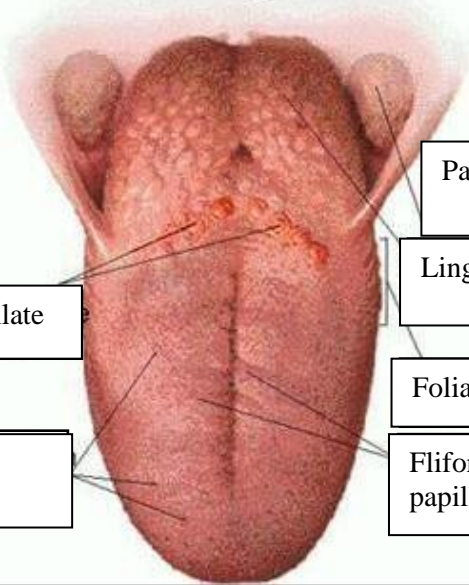


WORKSHEETS (LEMBAR KERJA)

Mata Kuliah	: Anatomi
Materi	: Anatomi Panca Indra
NIM>Nama Mahasiswa	: 2110101017_ suryanti

No	Keterangan	Pembahasan
1	Mata	



No	Keterangan	Pembahasan
	<p data-bbox="225 315 456 412">Semicircular canals</p> <p data-bbox="268 488 469 584">Semicircular canals</p> <p data-bbox="236 622 456 730">Vertibular apparatus</p>	 <p data-bbox="991 315 1374 412">Semicircular canals</p> <p data-bbox="991 434 1254 517">Vertubal never</p> <p data-bbox="991 562 1318 645">Auditory nerever</p> <p data-bbox="991 658 1161 730">coclea</p>
	<p data-bbox="453 1025 671 1099">circumvallate</p> <p data-bbox="400 1173 663 1272">Fungiform papillae</p>	 <p data-bbox="991 882 1254 965">Palatine tonsil</p> <p data-bbox="991 987 1246 1070">Linguar tongsir</p> <p data-bbox="991 1099 1289 1182">Foliate papillae</p> <p data-bbox="991 1173 1193 1272">Fliform papillae</p>