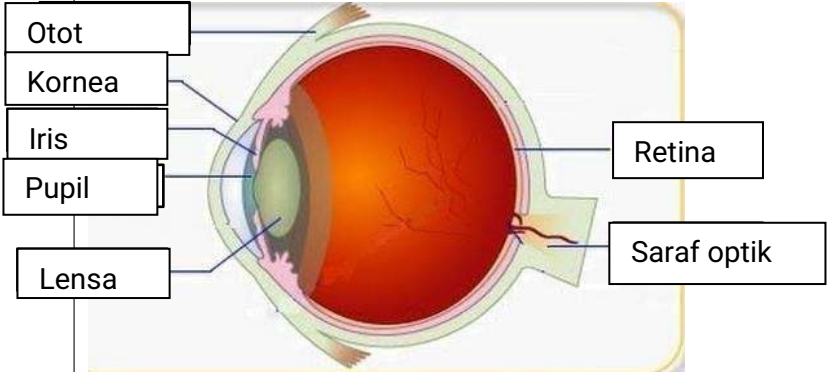

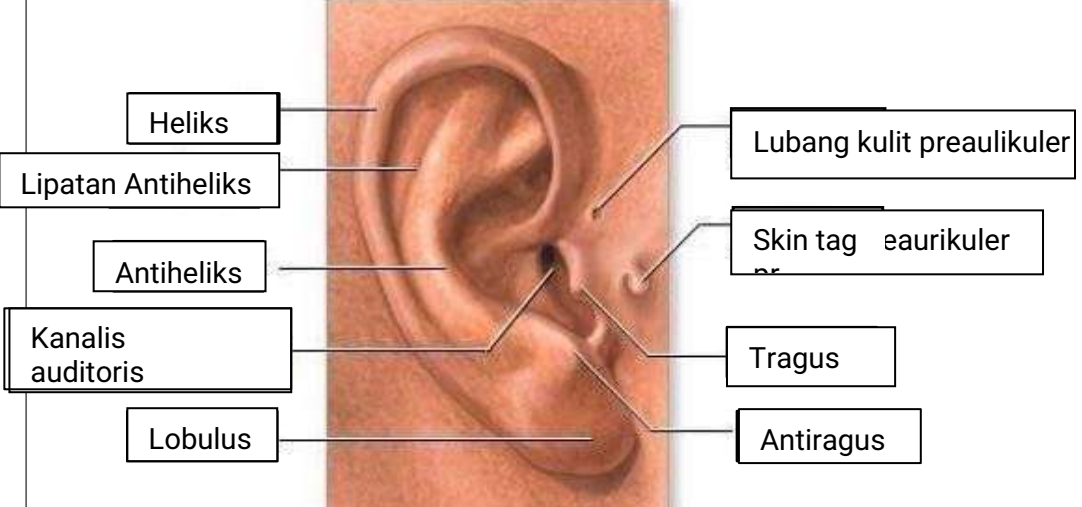

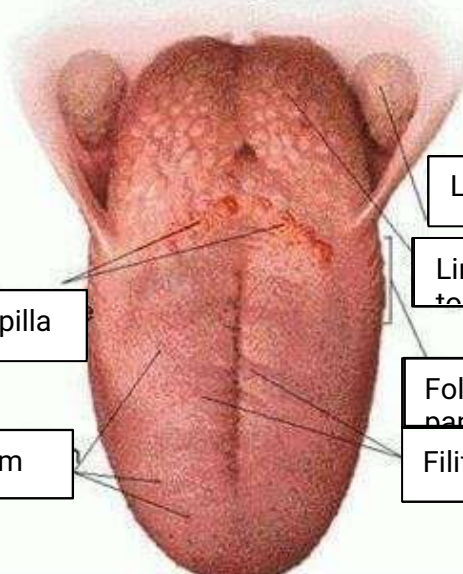


WORKSHEETS (LEMBAR KERJA)

Mata Kuliah	: Anatomi
Materi	: Anatomi Panca Indra
NIM>Nama Mahasiswa	: 2110101011 , Elivya Putri Melsany.

No	Keterangan	Pembahasan
1	<p>Mat</p> 	
	<p>Teling</p> 	
		

No	Keterangan	Pembahasan
	 <p data-bbox="271 313 470 425">Semicircular canals</p> <p data-bbox="247 481 454 571">Vestibulus</p> <p data-bbox="223 638 454 716">Tingkap</p>	<p data-bbox="997 324 1332 414">Semicircular canals within anterior</p> <p data-bbox="997 436 1292 571">1. Malleus 2. Incus 3. Stapes</p> <p data-bbox="997 582 1204 649">Saraf kranial</p> <p data-bbox="997 660 1324 728">Koklea (rumah siput)</p>
	 <p data-bbox="343 1030 670 1097">Circumvallate papilla</p> <p data-bbox="383 1164 662 1232">Papil fungiform</p>	<p data-bbox="1013 896 1380 963">Langit-langit tenggorokan</p> <p data-bbox="997 974 1236 1041">Lingual tonsil</p> <p data-bbox="997 1097 1244 1164">Foliate papillae</p> <p data-bbox="997 1176 1244 1243">Filiform papillae</p>